

Isotretinoin-Associated Crohn's Disease-Like Ileo-Colitis in a Renal Transplanted Patient: Case Report

Renal Transplantasyonlu Hastada İzetretinoin İlişkili Crohn Hastalığı Benzeri İleokolit

Hakan ÜNAL,^a
Cem ÇOMUNOĞLU,^b
Gülşen TÜKENMEZ^c

^aDepartment of Gastroenterology,
Başkent University İstanbul Hospital,
İstanbul

^bDepartment of Pathology,
Near East University Faculty of Medicine,
Lefkoşa, TRNC

^cClinic of Dermatology,
Şişli Etfal Training and Research Hospital,
İstanbul

Geliş Tarihi/Received: 07.11.2012
Kabul Tarihi/Accepted: 19.03.2013

Yazışma Adresi/Correspondence:
Cem ÇOMUNOĞLU
Acıbadem Health Group,
Central Pathology Laboratory, İstanbul,
TÜRKİYE/TURKEY
cemcomunoglu@gmail.com

ABSTRACT Isotretinoin (13-cis-retinoic acid) is a vitamin A synthetic analogue. It has been used for various forms of folliculitis and severe acne. Recently, an increasing number of data has been suggested a causal relationship between isotretinoin and inflammatory bowel disease. A 38 year-old male patient who had end stage renal failure due to Familial Mediterranean Fever amyloidosis, had a renal transplantation operation. During the first month of transplantation, steroid-induced acne developed on his back. Following treatment of isotretinoin he presented to the emergency clinic with abdominal pain and bloody diarrhea. Colonoscopic examination revealed multiple ulcers from the sigmoid colon through the ileum. Histopathology revealed patchy active chronic inflammation. Following discontinuation of isotretinoin, regression in number, diameter and depth of mucosal ulcers were detected colonoscopically. We have presented the case report of first renal transplanted and immune suppressed case in English literature who developed Crohn's disease-like ileocolitis following the use of isotretinoin.

Key Words: Isotretinoin; Crohn disease; Familial Mediterranean Fever; amyloidosis

ÖZET İzetretinoin (13-cis-retinoik asid) A vitamini sentetik analoglarından biridir. Farklı tipte folikülitler ve şiddetli akne tedavisinde kullanılmıştır. Yakın zamanda izotretinoin ile inflamatuvar barsak hastalığı arasında nedensel bir ilişki olduğuna yönelik veriler artmaktadır. Ailesel Akdeniz ateşine bağlı amiloidoz nedeniyle son dönem böbrek yetmezliği olan 38 yaşındaki erkek hasta renal transplantasyon operasyonu oldu. Transplantasyonun 1. ayında sırta steroide bağlı akne gelişti. İzetretinoin tedavisi sonrasında karın ağrısı ve kanlı diyare şikâyetiyle acil servise başvurdu. Kolonoskopik incelemede sigmoid kolon-ileum arasında multipl ülserler görüldü. Histopatolojik incelemede yama tarzında aktif kronik inflamasyon saptandı. İzetretinoin tedavisinin sonlandırılmasıyla mukozal ülserlerin sayısı ve derinliğinin azaldığı kolonoskopide saptandı. Burada, izotretinoin tedavisi sonrası Crohn hastalığı benzeri ileokolit gelişen, İngilizce literatürdeki ilk renal transplantasyonlu ve immünsüprese hasta sunulmuştur.

Anahtar Kelimeler: İzetretinoin; Crohn hastalığı; Ailesel Akdeniz Ateşi; amiloidoz

Türkiye Klinikleri J Gastroenterohepatol 2013;20(1):32-6

Isotretinoin (13-cis-retinoic acid) is a vitamin A synthetic analogue. It has been used for various forms of folliculitis and severe acne.¹ Current or past history of isotretinoin (ISTR) use is highly frequently encountered among patients suffering inflammatory bowel disease (IBD).²⁻⁸ We report a case with stable renal function after renal transplantation who developed inflammatory bowel disease following the usage of oral ISTR for his immunosuppression-induced acne.

CASE REPORT

A 38 year-old male patient who had end stage renal failure due to Familial Mediterranean Fever (FMF) amyloidosis, had had a renal transplantation operation. The immunosuppressive agents he had taken had been prednisolone 2x5 mg, micofenolat mofetil (MM) 2x540 mg and everolimus 2x0.75 mg, in order to prevent rejection. During the first month of transplantation, steroid-induced acne developed on his back. He was referred to the dermatology outpatient clinic eight months after the transplantation because he suffered from the lesions so severely that he was not able to lay on his back. His serum creatinine level was stable but CRP (C-reactive protein) and white blood cell (WBC) levels were elevated (67 mg/l and 14900/ul respectively). Acne therapy was started with azithromycin 500 mg per day for three consecutive days in a week, totally for three months and added topical therapy such as benzoil peroxide 10% lotion, sulfacetamide lotion, and tretinoin 0.05% cream. His acne failed to respond to this therapy. After confirming his diagnosis of acne with histopathological examination he was treated with ISTR orally with a dose of 10 mg daily. He experienced a dramatic improvement in his acne. However at the end of the second month of this therapy he came back to the emergency clinic with abdominal pain and bloody diarrhea.

On physical examination in the emergency department, he had a good general condition, and vital signs were stable. There was diffuse abdomi-

nal tenderness. Digital rectal examination showed that the rectum was empty. Upright abdominal X-ray findings were not pathological. Hematocrit, WBC count and CRP levels were 36%, 13000/ul and 72 mg/dl, respectively. Other biochemical tests were within normal limits. Clostridium difficile toxin and CMV PCR were negative. Colonoscopic examination revealed multiple ulcers from the sigmoid colon through the ileum. Ileocecal valve was deformed by ulcers. Diameters of ulcers were between 8-25 mm (Figure 1). Each ulcer had exude and red peripheral halo. Remaining mucosal areas among ulcers were normal. In microbiological examination of colonic and ileal biopsies taken from the ulcers, ARB was negative.

In colonoscopic biopsy samples from terminal ileum, ileocecal valve and descending colon, patchy active chronic inflammation was present histopathologically. In lamina propria, inflammatory cell infiltration consisting of neutrophils, plasma cells and lymphocytes destroying crypts were seen (Figure 2). Any granuloma was not detected. In some biopsy fragments mucosal ulceration and formation of granulation tissue were present (Figure 3). With special crystal violet stain, amyloid was positive in the vessel walls in colonic biopsies but not in ileal biopsies.

Crohn's disease was supported by colonoscopic and pathological findings. ISTR was discontinued and mesalazine 4 gr p.o. was added to the immunosuppressive treatment regimen. During his follow-up on the 2nd year, abdominal pain, diarrhea or rectal hemorrhage was not present. Control

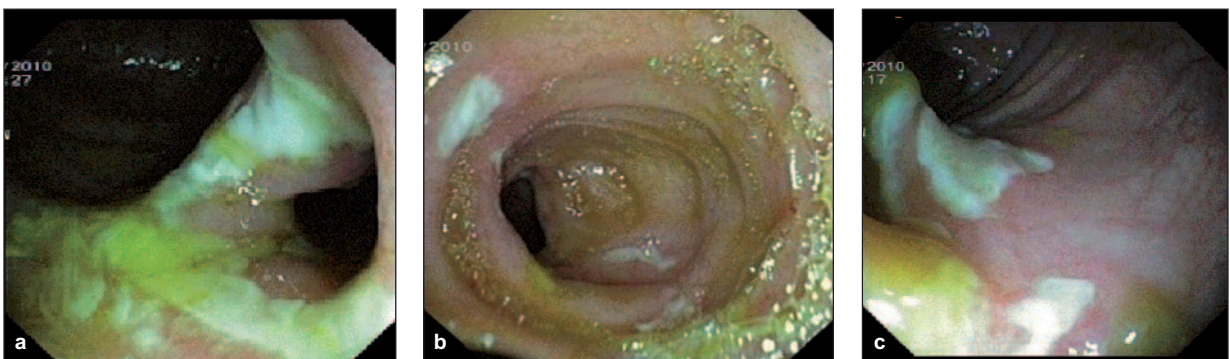


FIGURE 1: a) Endoscopic appearance of ulcers located at ileocecal valve. b) Endoscopic appearance of ileal ulcers. c) Endoscopic appearance of colonic ulcers.

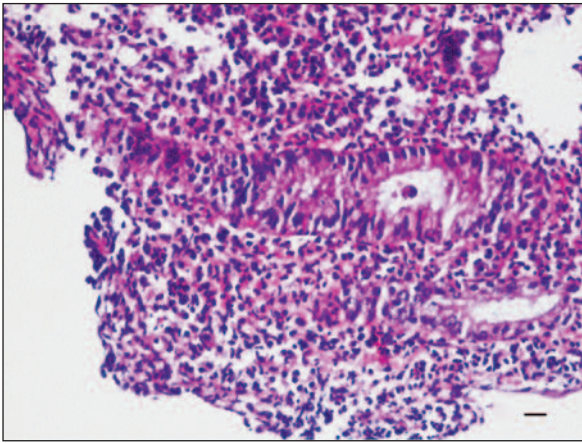


FIGURE 2: Inflammatory cells destroying colonic crypts (H-E, scale bar: 50 µ).

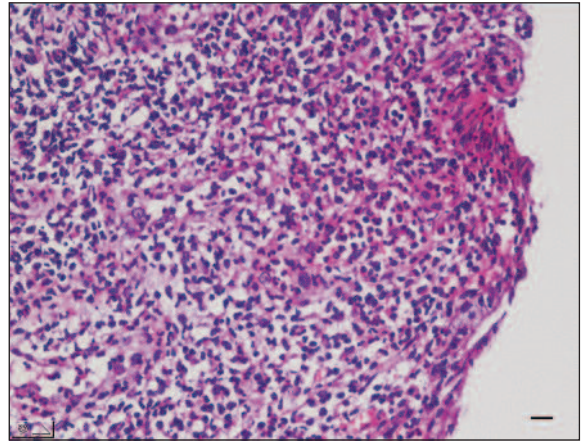


FIGURE 3: Ulcerated colonic mucosa and replacing granulation tissue (H-E, scale bar: 50 µ).

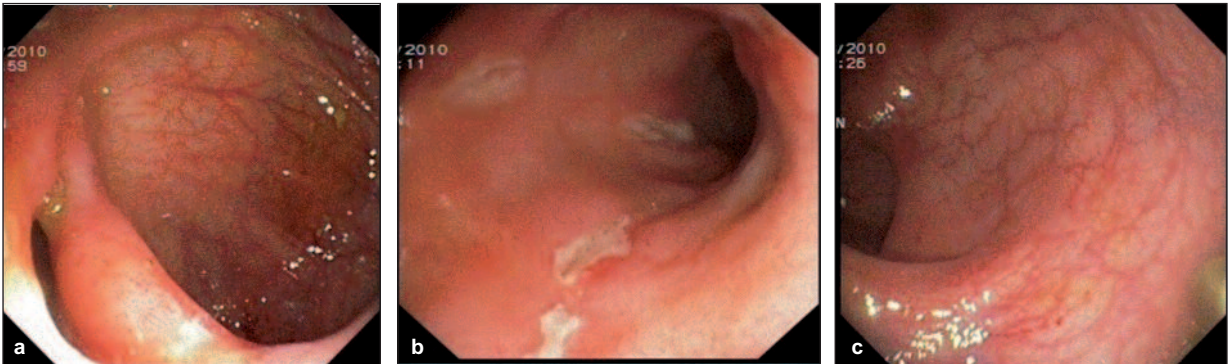

FIGURE 4: a) Endoscopic appearance of healed ulcers at ileocecal valve. b) Endoscopic appearance of healed ileal ulcers. c) Endoscopic appearance of healed colonic ulcers.

colonoscopic examination revealed regression in number, diameter and depth of mucosal ulcers (Figure 4).

DISCUSSION

Crohn's disease (CD) is a chronic inflammatory bowel disease (IBD) of the human gastrointestinal tract. The etiology and pathogenesis of CD remain unknown, but increasing evidence suggests that the dysregulation of mucosal T cells which results in the secretion of pro-inflammatory mediators, the accumulation of inflammatory cells, and tissue damage, may play an important role in the pathogenesis of CD. T0 lymphocytes produced from the thymus are transformed into cytotoxic T lymphocytes such as Th1, Th2 and Th17 by stimulation of proinflammatory cytokines (IL1, IL2, IL4, IL6, IL23, TGF- β).⁹ Cytotoxic T lymphocyte activity is controlled by Treg cells, which is responsible for

immune tolerance to intestinal bacterial antigens in gastrointestinal lumen and ingested antigens. Function and/or number of the Treg cells decrease, cytotoxic T lymphocyte activation increases. Excessive activation of cytotoxic T lymphocytes with various warnings is an important factor in epithelial damage. Although the exact etiology is unclear in such cases, some drugs such as antibiotics, non-steroidal anti-inflammatory drugs and oral contraceptive pills are held responsible.¹⁰⁻¹² Isotretinoin (13-cis-retinoic acid) is a well-known vitamin A synthetic analogue used in several dermatologic diseases, including acne and various forms of folliculitis.¹ Synthetic analogues of retinoic acid trigger intestinal mucosal killer T cell activation. These activated cells cause epithelial damage and mucosal inflammation.^{5,13} Besides, synthetic retinoic acid derivatives contribute to the development of intestinal mucosal ulcerations by dis-

rupting epithelial cell maturation. Retinoic acid derivatives contribute to the development of inflammation and mucosal ulceration by activated T_s lymphocytes.

The colonoscopic biopsy specimen in our case showed focal active chronic inflammation. The histologic findings suggest that ISTR may have acted as a trigger for acute inflammation and the histologic features are compatible with the chronic IBD, most likely with CD. Following discontinuation of ISTR, the gastrointestinal complaints of the patient disappeared further supporting the relationship between ISTR and IBD.

The results of some studies on the association of ISTR with new-onset IBD are conflicting.^{14,15} Bernstein et al. claimed that isotretinoin was not likely to cause chronic IBD.¹⁴ However, Crockett et al. suggested that ulcerative colitis (UC) but not CD was associated with previous isotretinoin exposure.¹⁵ Spada and colleagues have reported a case of pan-enteritis associated with isotretinoin which was not compatible with IBD but instead showed focal, nonspecific acute inflammation with a moderate neutrophil infiltrate, consistent with an acute proctosigmoiditis.⁸ There are well documented cases supporting the relationship between ISTR and IBD.²⁻⁷

Detection of amyloid on biopsy samples taken from the colonic mucosa neighboring the ulcers, made us to consider a possible etiological relationship between amyloid and these ulcers. Because a myeloproliferative disease was not present as a causative factor, primary amyloidosis of AL type was excluded and because the dialysis period was short, amyloidosis related with dialysis was not considered. It was estimated that in this patient suffering from chronic renal failure secondary to FMF, amyloidosis detected on colonic biopsies was reactive and AA type. In AA type reactive amyloidosis gastrointestinal involvement was reported to be 60%.¹⁶ Ensari et al. detected amyloid storage in rectum in 36 cases and in ileum in 1 case in their case series of 111 FMF patients.¹⁷ In another case series of patients having amyloid storage in gastrointestinal tract amyloid was found in mucosa of duode-

num in 100%, in stomach and colon in 90% and in esophagus in 70% of cases.¹⁸ Small intestinal involvement was reported rarely. In our patient ileal ulcers were present however amyloid was negative on biopsies sampled from ileal mucosa around these ulcers. After discontinuation of ISTR, regression at the number, diameter and depth of mucosal ulcers were detected. Furthermore, histopathological findings supported the diagnosis of CD. It was reported that survival in amyloidosis of extensive gastrointestinal involvement was limited with months; however our case was in his 2nd year of follow-up.

Concurrence of Crohn's Disease and Familial Mediterranean Fever (FMF) may pose a challenge to diagnosis. FMF is an inflammatory disorder transmitted in an autosomal recessive pattern characterized by an uncontrolled immune response.¹⁹ Influx of polymorphonuclear leukocytes (PNLs) is seen into the inflamed regions in FMF. FMF is caused by mutations in MEFV gene which is associated with functional disorders in PNLs. It has been reported that MEFV mutations were not associated with CD susceptibility.²⁰

Everolimus and MM are being tried for refractory or corticosteroid depended Crohn's Disease. Although experience of everolimus is limited, it has been reported that MM might have been effective in refractory or corticosteroid depended Crohn's Disease.²¹⁻²³ The most common side effect of MM is on gastrointestinal system. In a few cases, gastrointestinal ulcers developing after the usage of MM have been reported. Halim et al. concluded that de-novo inflammatory bowel disease could have developed post renal transplantation even when MM has been used.²⁴ Mechanism of ulcer development in the gastrointestinal mucosa with MM is unclear. Immunosuppressive effect of MM arises through with T lymphocytes. Since the patient had been using MM for one year when his symptoms begun, according to us, ISTR which has been started two months ago, may be a more dominant factor than MM. However, MM may have additive effect with ISTR on mucosal ulcer development.

As a result, although the causal relationship between IBD and ISTR has not been explained, increasing numbers of studies suggest that this relationship is strong. In this regard, our patient is

different and important because he is the first renal transplanted and immune suppressed case who developed CD-like ileocolitis after the use of ISTR.

REFERENCES

- Ellis CN, Krach KJ. Uses and complications of isotretinoin therapy. *J Am Acad Dermatol* 2001;45(5):S150-7.
- Brodin MB. Inflammatory bowel disease and isotretinoin. *J Am Acad Dermatol* 1986;14(5 Pt 1):843.
- Martin P, Manley PN, Depew WT, Blakeman JM. Isotretinoin-associated proctosigmoiditis. *Gastroenterology* 1987;93(3):606-9.
- Reniers DE, Howard JM. Isotretinoin-induced inflammatory bowel disease in an adolescent. *Ann Pharmacother* 2001;35(10):1214-6.
- Passier JL, Srivastava N, van Puijenbroek EP. Isotretinoin-induced inflammatory bowel disease. *Neth J Med* 2006;(2)64:52-4.
- Bankar RN, Dafe CO, Köhnke A, Babu PS. Ulcerative colitis probably associated with isotretinoin. *Indian J Gastroenterol* 2006;25(3):171-2.
- Rolanda C, Macedo G. Isotretinoin and inflammatory bowel disease. *Am J Gastroenterol* 2007;102(6):1330.
- Spada C, Riccioni ME, Marchese M, Familiari P, Costamagna G. Isotretinoin-associated pan-enteritis. *J Clin Gastroenterol* 2008;42(8):923-5.
- Inflammatory bowel disease: immunologic consideration. In: Greenberger N, Blumberg R, Burakoff R, eds. *CURRENT Diagnosis & Treatment Gastroenterology, Hepatology, & Endoscopy*. 1st ed. New York, United States: Mc Graw Hill Professional Publishing; 2009. p.11-2.
- Card T, Logan RF, Rodrigues LC, Wheeler JG. Antibiotic use and the development of Crohn's disease. *Gut* 2004;53(2):246-50.
- Evans JM, McMahon AD, Murray FE, McDevitt DG, MacDonald TM. Non-steroidal anti-inflammatory drugs are associated with emergency admission to hospital for colitis due to inflammatory bowel disease. *Gut* 1997;40(5):619-22.
- Godet PG, May GR, Sutherland LR. Meta-analysis of the role of oral contraceptive agents in inflammatory bowel disease. *Gut* 1995;37(5):668-73.
- Reddy D, Siegel CA, Sands BE, Kane S. Possible association between isotretinoin and inflammatory bowel disease. *Am J Gastroenterol* 2006;101(7):1569-73.
- Bernstein CN, Nugent Z, Longobardi T, Blanchard JF. Isotretinoin is not associated with inflammatory bowel disease: a population-based case-control study. *Am J Gastroenterol* 2009;104(11):2774-8.
- Crockett SD, Porter CQ, Martin CF, Sandler RS, Kappelman MD. Isotretinoin use and the risk of inflammatory bowel disease: a case-control study. *Am J Gastroenterol* 2010;105(9):1986-93.
- Kahi CJ, Vakili S, Liepnieks JJ, Benson M. Amyloidoma of the esophagus. *Am J Gastroenterol* 2007;102(4):910-1.
- Ensari C, Ensari A, Tümer N, Ertug E. Clinicopathological and epidemiological analysis of amyloidosis in Turkish patients. *Nephrol Dial Transplant* 2005;20(8):1721-5.
- Tada S, Iida M, Iwashita A, Matsui T, Fuchigami T, Yamamoto T, et al. Endoscopic and biopsy findings of the upper digestive tract in patients with amyloidosis. *Gastrointest Endosc* 1990;36(1):10-4.
- Çelikel Acar B, Yalçınkaya F, Ekim M. [The pathogenesis of familial mediterranean fever]. *Türkiye Klinikleri J Pediatr* 2006;15(4):151-5.
- Fidder H, Chowers Y, Ackerman Z, Pollak RD, Crusius JB, Livneh A, et al. The familial mediterranean fever (MEVF) gene as a modifier of Crohn's disease. *Am J Gastroenterol* 2005;100(2):338-43.
- Tan T, Lawrance IC. Use of mycophenolate mofetil in inflammatory bowel disease. *World J Gastroenterol* 2009;15(13):1594-9.
- Palaniappan S, Ford AC, Greer D, Everett SM, Chalmers DM, Axon AT, et al. Mycophenolate mofetil therapy for refractory inflammatory bowel disease. *Inflamm Bowel Dis* 2007;13(12):1488-92.
- Carvalho R, Almeida N, Portela F, Gomes D, Gregório C, Gouveia H, et al. Terminal ileitis in a renal transplanted patient: could it be infectious ileitis, Crohn's disease, or pharmacological toxicity? *Inflamm Bowel Dis* 2011;17(6):E52-3.
- Halim MA, Al-Otaibi T, Elsisy A, El-Sayed A, Nair P, Said T, et al. De-novo [corrected] post renal transplantation inflammatory bowel disease. *Saudi J Kidney Dis Transpl* 2008;19(4): 624-6.