

Late Breast Cancer Metastases of Spine: A Case Report

OMURGADA GEÇ DÖNEM MEME KANSERİ METASTAZI: OLGU SUNUMU

Kenan BAYRAKCI*, Mustafa ÖZDEMİR*, Murat ALTAY*, Aziz ERAKAR*, Tarık YAZAR*

* Dr., Ankara University Faculty of Medicine, Orthopaedics and Traumatology Department, Ankara, TURKEY

Summary

Of all the malign metastatic cancers that metastases to bones and more so to the skeletal system, the most common of these is breast cancer. In this article we report a case in which the patient was diagnosed of having breast cancer with late spinal metastases. After a period of 35 years following her initial diagnosis T12-L1 spinal metastases was established. Because neurologic deficit was present, a two stage combined posterior instrumentation and fusion approach was done followed by an anterior approach for T12-L1 tumour resection, cord decompression and vertebral reconstruction. During the period of 14 months follow-up total neurologic recovery was recorded without any resultant loss in time and neither surgically nor tumour related (distant metastases or new metastatic sites) complications were seen.

Key Words: Breast cancer, Late metastases, Spine

T Klin J Med Sci 1999, 17:232-235

Özet

Tüm malign metastatik kanserler içinde en sık meme kanseri kemiğe ve iskelet sistemine yayılır. Bu çalışmada kliniğimizde tanı ve tedavisi yapılan geç dönem meme kanseri metastazlı bir hastanın vaka sunumu yapılmıştır. Hastanın ilk tanısından 35 yıl sonra T12-L1 vertebra metastazı tesbit edilmiş ve nörolojik defisitinin de olması nedeni ile iki aşamada önce posterior enstrümantasyon ve füzyon sonra anterior yol ile tümör rezeksiyonu, kord dekompresyonu ve vertebra rekonstrüksiyonu uygulanmıştır. 14 aylık takibi süresince nörolojik defisitinde tam düzelme olduğu, zaman içerisinde gerileme olmadığı ve cerrahi veya tümöre bağlı olarak komplikasyon gelişmediği gözlenmiştir.

Anahtar Kelimeler: Meme kanseri, Geç metastaz, Vertebra

T Klin Tıp Bilimleri 1999, 17:232-235

Breast cancers account for 27% of all cancers affecting women (12). After treatment of the primary lesion of breast cancer, regardless of the stage, grade, histopathology and treatment scheme, distant metastases is likely to occur. Although breast cancer is reported to metastase to the spine in approximately 19-70% (13). As a consequence of the metastases, neurologic deficit resulting from spinal cord compression is seen 2-12.5% of patients in which a surgical treatment is unavoidable (6). Our patient's clinical, radiological and histopathologic-histochemical studies confirmed multilevel spinal metastases after a period of 35 years follow-

ing her initial diagnosis and treatment. 35 years' period is very seldom in the literature.

Case Report

A 71 year old postmenopausal woman with back pain, lower extremity weakness and paresthesia was seen at our clinic in January 1997. She complained about pain which increased during the last three months. This patient underwent operation 35 years ago for left breast carcinoma. Radical left mastectomy was performed.

In physical and systematic examination, left breast was mastectomised; right breast was intact; other systems were normal. Neurologic examination of the upper extremity were normal; in contrast lower extremity findings were as follows: atrophy of the bilateral quadriceps femoris muscles with right sided predominance, and a minimal degree of

Geliş Tarihi: 08.04.1999

Yazışma Adresi: Dr.Kenan BAYRAKCI
Özveren Sok., 37/4, Maltepe, Ankara

anterior cruris muscle atrophy was observed. In the lower extremities, the patellar tendon reflexes were reduced; the Achilles reflexes were absent; below the T12 level there was hypoesthesia.

Roentgenograms demonstrated severe destructive collapse of the T12 and L1 vertebral bodies and moderate degree of compression with a lytic appearance of L2-L3 (Fig.1). Magnetic resonance and computed tomogram studies illustrated anterior epidural cord compression and 70% of canal compromise (Fig.2 and 3). To determine whether her metastases was direct result of her previous breast carcinoma or not, further advanced screening techniques were performed. However no new primary source of malignancy was discovered (Fig 4).

The fact that the patient's pain and neurologic deficit was progressive and the exact diagnosis was not known we thought it best to perform for both diagnostic, and theropathic/palliative reasons. A two stage combined posterior instrumentation and

fusion approach was done followed by an anterior approach for T12-L1 tumour resection, cord decompression and vertebral reconstruction (Fig 5 and 6). Intraoperative frozen section studies suggested metastatic malignancy and postoperative histopathologic-histochemical studies confirmed this malignancy to be intraductal breast carcinoma with estrogen receptor positivity. Tamoxiphen and radiotherapy was administered postoperatively. After physical rehabilitation she was able to walk on aided. No neurologic deficits were documented. After 14 months of postoperative follow-up no decrease in neurologic status was recorded. Instrumentation and reconstruction related problems did not occur; pain was totally relieved and no new metastatic sites were observed.

Discussion

The skeletal system accounts for 15% of all carcinoma metastases, of which breast cancer is one of the most common (10,12). Bone metastases is

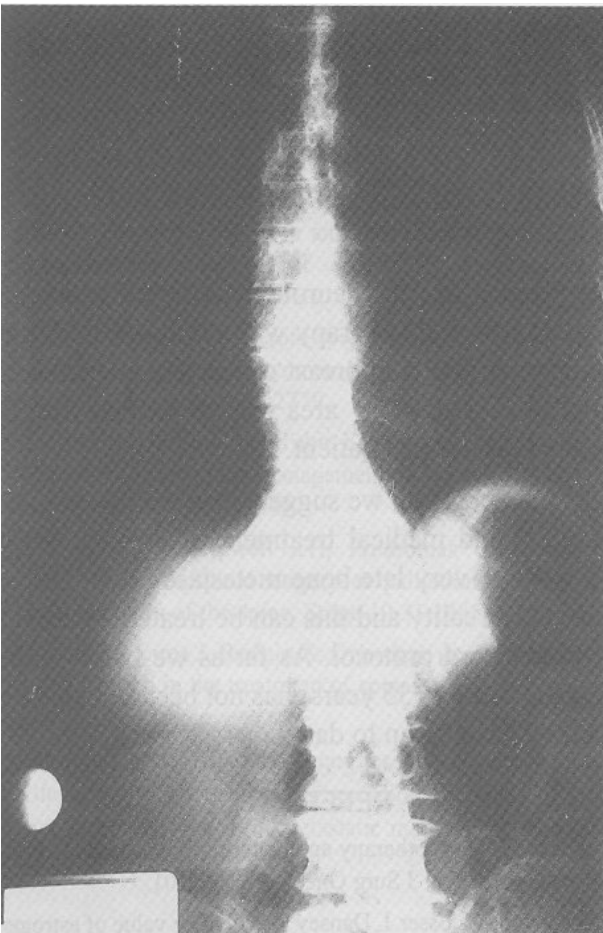


Figure 1. Preoperative anteroposterior X-Ray view

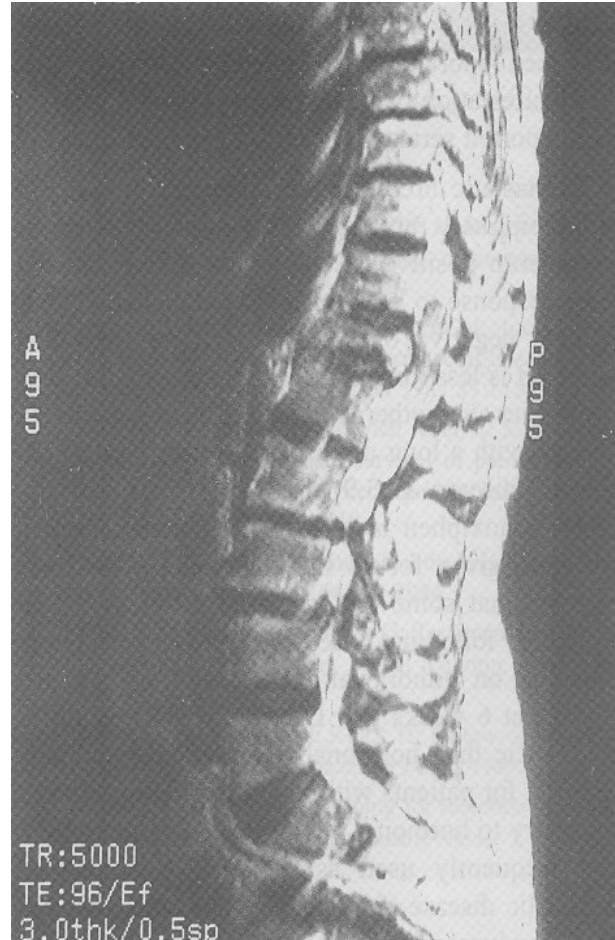

Figure 2. Preoperative sagittal view of MRI

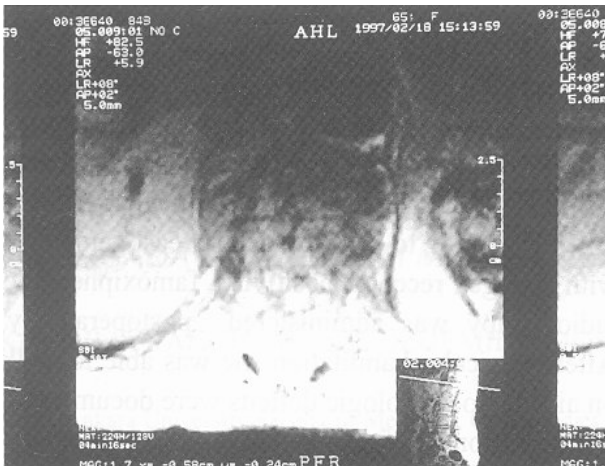

Figure 3. Preoperative transverse view of MRI.

most commonly seen in the vertebral column especially in the thoracic region (11). It is also well known that bone metastatic cancer most frequently arises from breast carcinoma which is most commonly seen 1 to 2 years after the diagnosis and treatment of breast cancer (1,3). However late metastases to both the visceral organs and bones have been reported (12). The median survival from the manifestation of metastases is about 3 years in most reported series (1,14).

Metastatic breast cancer treatment must be a multidisciplinary approach (7,8,15). Estrogen or progesteron positive receptor type cancers have a better response to both hormonal and chemotherapy than negative ones (2-6). Because hormonal treatment is less toxic than chemotherapy, it is preferred over chemotherapy and it is most effective in patients with a long disease-free interval and non-visceral disease (2,3,9). In postmenapausal patients, tamoxiphen is typically the first hormonal treatment given for its limited toxicity. Evidence suggests that some patients who progress on tamoxiphen following a response may show tumor shrinkage on withdrawal of the drug for a duration of at least 6 weeks (4). Because chemotherapy is more toxic than hormonal therapy, it is generally reserved for patients with metastatic disease that is refractory to hormonal treatment. Chemotherapy is also frequently used as the first treatment of metastatic disease if the patient has extensive visceral involvement or if the tumour is growing rapidly, especially in visceral sites (1). The indication

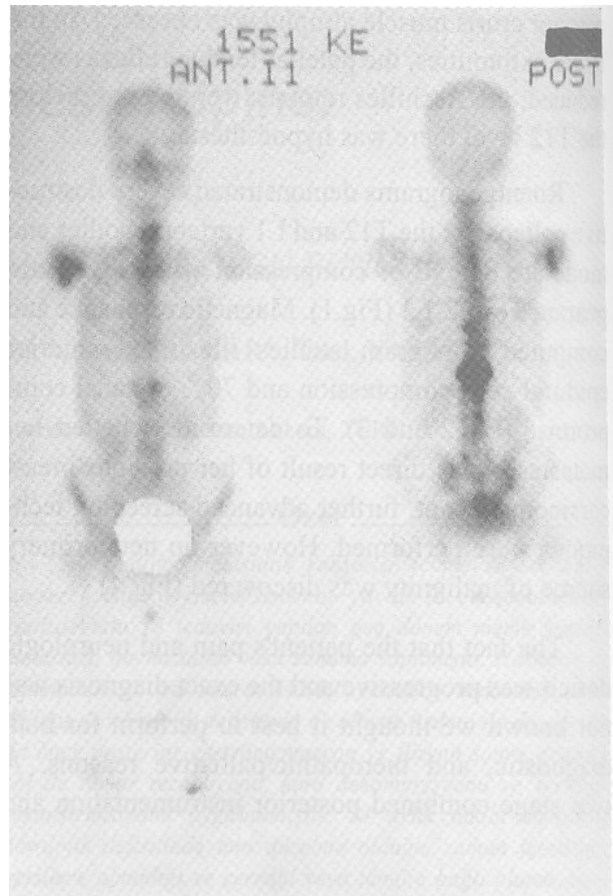


Figure 4. Bone scintigraphic appearance of tumor.

for surgery was the neurological deficit which our patient had. Radiotherapy was a part of multidisciplinary approach in breast cancer treatment. Local control of metastatic area was performed with radiotherapy for this patient.

In conclusion we suggest that despite effective surgical and medical treatment of primary breast carcinoma, very late bone metastase (as in our patient) is a reality and this can be treated effectively by a standard protocol. As far as we know such a late metastases (35 years) has not been documented in the literature up to date.

REFERENCES

1. Amer M. Chemotherapy and pattern of metastases in breast cancer patients. *J Surg Oncol* 1982;19:101.
2. Bezwoda W, Esser J, Dansey R et al: The value of estrogen and receptor determination in the management of advanced breast cancer. *Cancer* 1991;68:867.

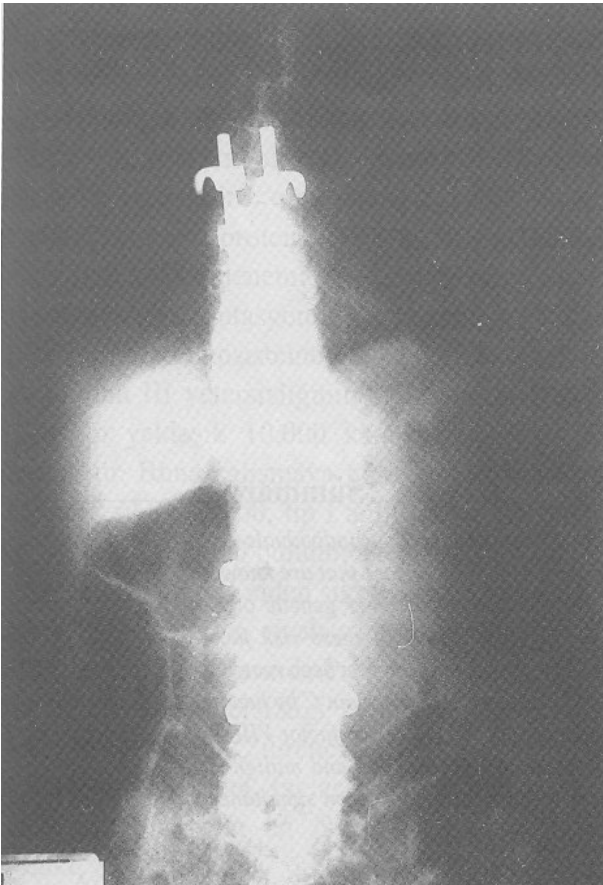


Figure 5. Postoperative anteroposterior X-Ray view

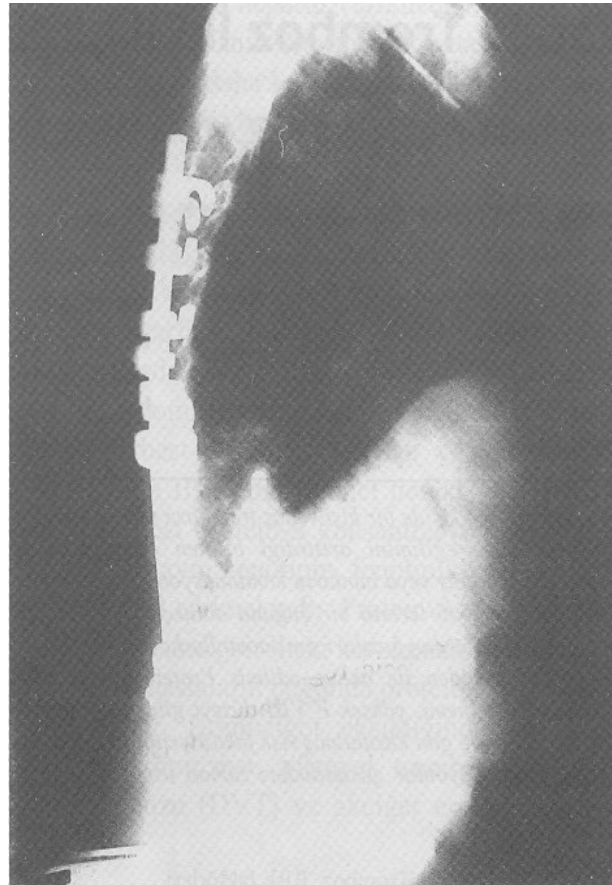


Figure 6. Postoperative lateral X-Ray view

3. Brooks S, Saunders D, Singhakowinta A et al: Relation of tumor content of estrogen and progesteron receptors with response of patients of endocrine therapy. *Cancer* 1980;46:2775
4. Dao T, Newoto T: Steroid receptors and response to endocrine ablations in woman with metastatic cancer of breast. *Cancer* 1980;46:2779.
5. Degenshein G, Bloom N, Tobin E: The value of progesterone receptor assays in the management of advanced breast cancer. *Cancer* 1980;46:2789.
6. Dewald RL, Bridwell KH, Prodromas C, Rodts MF: Reconstructive spinal surgery as palliation for metastatic malignancies of the spine. *Spine* 10:31:1985.
7. Faccioli F, Lima J, Bricolo A: One-stage decompression and stabilization in the treatment of spinal tumors. *J Neurosurg Sci* 29:199:1985.
8. Harrington KD: Anterior decompression and stabilization of the spine as a treatment for vertebral collapse and spinal cord compression from metastatic malignancy. *Clin Ortop* 233:177:1988.
9. Howell A, Defriend D, Robertson J et al: Response to a specific antiestrogen (ICI 182780) in tamoxiphen-resistant breast cancer. *Lancet* 1995;345:29.
10. Kamby C, Dirksen H, Vejborg I et al: Incidence and methodologic aspects of the occurrence of liver metastases in recurrent breast cancer. *Cancer* 1987;59:1524.
11. Leone B, Rowero A, Rabinowich M et al: Stage 4 breast cancer: Clinical course and survival of patients with osseous versus extraosseous metastases at initial diagnosis. *Am J Clin Oncol* 1988;11:618.
12. Miller F, Whitwill R: Carcinoma of the breast metastatic to the skeleton. *Clin Ortop* 184:121:1984.
13. O'Neil J, Gardner V, Armstrong G: Treatment of tumors of the thoracic and lumbar spinal column. *Clin Ortop* 227:103:1986.
14. Rutgers E, Van Slooten E, Kluck H: Follow-up after treatment of primary breast cancer. *Br J Surg* 1989;76:187.
15. Tamin R, Donegon W: Screening for recurrent breast cancer: its effectiveness and prognostic value. *J Clin Oncol* 1987;5:62.