

# The Anomaly of Left Circumflex Artery Originating from the Right Coronary Artery Detected by 64-Slice Multidetector Computed Tomography Angiography: Scientific Letter

## 64 Kesit Multidedektör Bilgisayarlı Tomografi Anjiyografi ile Saptanan Sağ Koroner Arter Kaynaklı Sol Sirkumfleks Arter Anomalisi

Hakkı Serhat TULAY, MD<sup>a</sup>

<sup>a</sup>Department of Radiology,  
The Hospital of Mağusa Medical  
Center, Famagusta

Geliş Tarihi/Received: 08.09.2007  
Kabul Tarihi/Accepted: 01.10.2007

Yazışma Adresi/Correspondence:  
Hakkı Serhat TULAY, MD  
The Hospital of Mağusa Medical  
Center, Department of Radiology,  
Eşref Bitlis Street, Famagusta,  
CYPRUS  
serhattulay@hotmail.com

**ABSTRACT** The incidence of coronary artery anomalies in routine coronary angiography series is between 0.6% and 1.5%. Anomalies of the left circumflex artery (LCX) are the third most common coronary artery anomalies after left main coronary artery (LMCA) (48%) and right coronary artery (RCA) anomalies (22%). Coronary artery anomalies are potentially life threatening anatomic variations but most of these variations are generally asymptomatic. However, detecting these anomalies prior to coronary angioplasty or cardiac surgery has uttermost importance. We present the case of a 40-year-old-man with a family history of coronary artery disease who presented to our hospital with complaints of hypertension and hypercholesterolemia. Multidetector CT coronary angiography revealed that the LCX originated variationally from the proximal part of the RCA reaching its anatomical supplementation area after passing between the aorta and left atrium.

**Key Words:** Coronary vessel anomalies; tomography, spiral computed; coronary angiography

**ÖZET** Rutin koroner anjiyografi serilerinde koroner arter anomalisi görülme oranı %0.6 ile %1.5 arasında değişmektedir. Sol ana koroner arter (LMCA) (%48), sağ koroner arter(RCA) (%22) anomalilerinden sonra 3. en sık görülen koroner arter anomalisi sol sirkumfleks arter (LCX) anomalisidir. Koroner arter anomalisi saptanan olgular genellikle asemptomatiktir. Koroner anjiyoplasti veya kardiyak cerrahi girişimler öncesi bu damarların saptanması önemlidir. Ailede kalp hastalığı öyküsü, yüksek kan kolesterol düzeyi ve hipertansiyon öyküsü ile merkezimize başvuran 40 yaşında erkek hastaya yapılan 64 kesit multidedektör tomografi koroner anjiyografi değerlendirmesinde LCX'in varyasyonel olarak RCA proksimalinden kaynaklanıp, aorta ile sol atriyum arasından geçerek normal anatomik sulama alanına ulaştığı saptanan nadir bir olgu sunulmaktadır.

**Anahtar Kelimeler:** Koroner arter anomalileri; çokkesitli spiral bilgisayarlı tomografi; BT koroner anjiyografi

**Türkiye Klinikleri J Med Sci 2008, 28:551-554**

Coronary artery anomaly is a group of diseases with various severities ranging from asymptomatic occurrence to life threatening conditions. The incidence of coronary artery anomalies in routine coronary angiography series is between 0.6% and 1.5%.<sup>1-7</sup> Most patients with coronary artery anomaly are asymptomatic. Rarely, coronary artery anomalies may present with chest pain and may have myocardial ischemia or other life threatening conditions and sudden death may occur in some cases.<sup>8-10</sup> Coronary artery anomalies without myocardial ischemia are generally accepted as innocent or insignificant.<sup>10</sup>

Until the last couple of years, the preferred method for detecting coronary artery anomalies was conventional invasive coronary angiography. However, the identification of anomalous coronary arteries with conventional coronary angiography is usually difficult as 3-dimensional (D) visualization of the ostium and the course of the coronary arteries and the great vessels is not possible. Multi-detector computed tomographic (CT) coronary angiography provides excellent spatial resolution and 3D information of the ostium, the course of the coronary arteries and the great vessels. This procedure is also easy and noninvasive and it can be applied on an outpatient basis with patient comfort. With the novel 64-slice multidetector CT, which enables high spatial and temporal resolution, it is possible to diagnose coronary arterial disease accurately without heart rate limitation.<sup>3,4</sup>

A 40-year-old-man with a family history of coronary artery disease presented to our hospital with hypertension and hypercholesterolemia. Routine biochemical analysis and electrocardiographic (ECG) evaluations were normal. A multidetector CT coronary angiography was recommended after cardiology consultation. After the flush infusion of 90 cc of intravenous iodinated contrast material

and 30 cc saline, the examination was performed by using the GE Lightspeed VCT (General Electric Milwaukee Wisconsin USA) 64 detector tomography with retrospective ECG gating. Axial images of 0.625 mm thickness were obtained. The images were processed on the workstation. Thick and thin slab multiplanar reformation (MPR), maximum intensity projection (MIP) and 3D volumetric mode (volume rendering) (VR) reconstructions were obtained. Reconstructions at various phases of cardiac cycle were performed. The 75% phase during diastole was used for the analysis of the LMCA. The RCA and circumflex artery were evaluated at the 37.5% and 50% phase of the cardiac cycle.

The VR images of the patient revealed that the LMCA, the left anterior descending artery (LAD), RCA and the posterior descending artery (PDA) had normal locations and calibrations. They also revealed that the left circumflex (LCX) artery originated variationally from the proximal portion of the RCA and reached the normal anatomic supplementation area after crossing between the aortic root and left atrium. The lumen of the LCX artery was examined by using the curved image technique and no plaques or intimal deformities were detected (Figure 1-4).

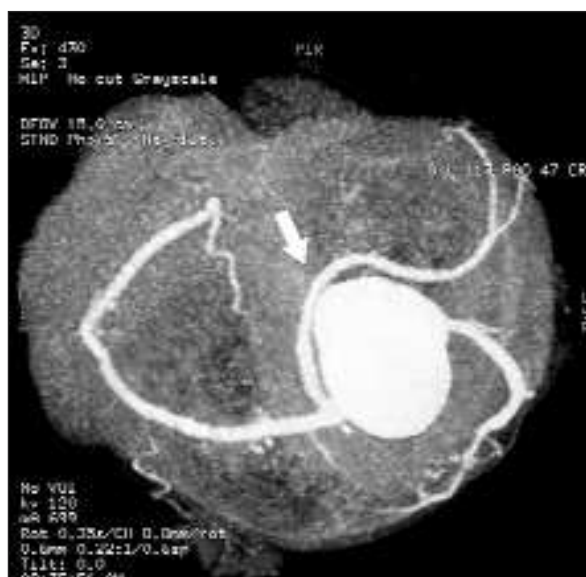

FIGURE 1: HD MIP.

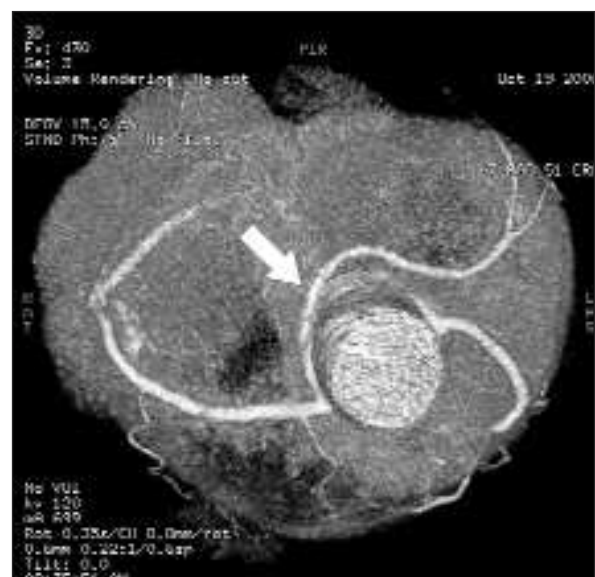

FIGURE 2: Volume Rendering (VR).

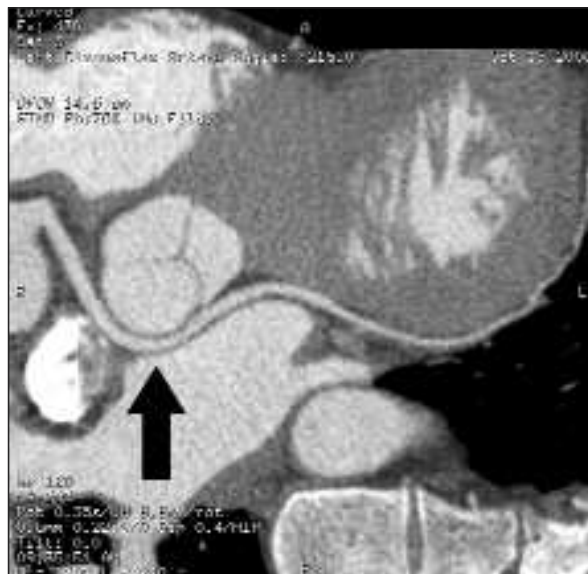


FIGURE 3: Curved Imaging.

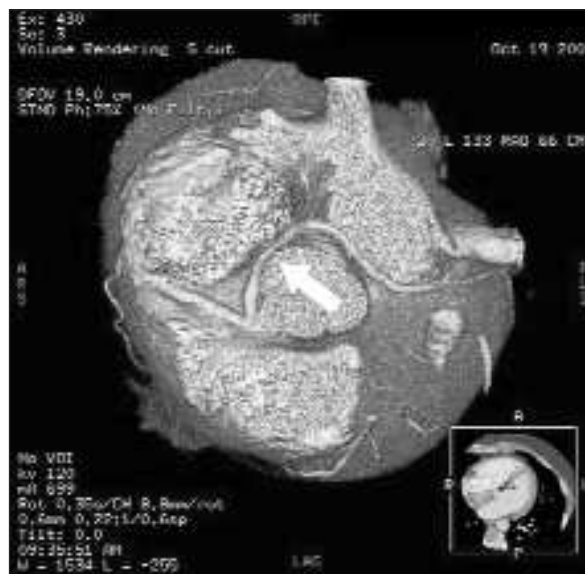

FIGURE 4: Volume rendering.

## DISCUSSION

The incidence of coronary artery anomalies in routine coronary angiography series is between 0.6% and 1.5%.<sup>1-7</sup> Asymptomatic coronary artery anomalies are generally diagnosed incidentally by routine coronary angiography or during autopsies.<sup>3,8,9</sup> Coronary arteries originating from the different aortic sinuses are rare but mortal. Approximately 20% of coronary artery anomalies produce lifethreatening symptoms, including arrhythmias, syncope, myocardial infarction or sudden death, especially if the anomaly is between the aorta and the main pulmonary artery. Death is due to myocardial ischemia in such cases. The mechanisms of the development of myocardial ischemia are not clear. However, the valve mechanism was suggested to be due to the angulations at the arterial origin or to the compression of the artery between the aorta and the pulmonary artery during exercise.<sup>9-13</sup> In some cases, the spasms of the abnormal coronary artery (possibly due to endothelial damage) or arteriosclerosis were considered to be the reason for coronary arterial occlusion.<sup>14</sup>

In our case, the LMCA originated from its normal anatomic ostium. Multidetector CT coronary angiography showed an anomalous origin of

the LCX artery from the RCA. It was between the aorta and the left atrium on VR images. There was no luminal narrowing or angulations in the LCX on the curved and multiplanar images. The evaluation of the lumen revealed no atherosclerotic changes.

Previous studies reported that LCX anomalies were the third most common coronary artery anomaly diagnosed incidentally by using conventional angiography.<sup>1,2,15,16</sup>

Nicholas et al reported the rate of LCX anomalies as 29% in their series of 26 coronary artery anomalies.<sup>16</sup>

Two types of LCX artery anomalies were reported in the literature. In the first type, LCX originates from either the right valsalva sinus or the left valsalva sinus as a separate ostium. In the second type, LCX originates from the proximal part of the RCA.<sup>2</sup> The origin of the LCX from the right sinus valsalva is one of the most common coronary artery anomalies. The incidence ranges from 0.3% to 0.67%.<sup>8,15-17</sup> The recognition and identification of this anomaly before coronary angioplasty or cardiac surgery is important because the symptoms can not be differentiated from those of the atherosclerotic coronary artery disease.

Until the last couple of years, the preferred diagnostic procedure to detect coronary arterial anomalies was invasive coronary angiography. The disadvantages of invasive coronary artery angiography are the need for hospitalization, invasive nature of the procedure and the risk of complications. In addition, images of the ostium and the traces of the coronary arteries and the great vessels are limited on the conventional coronary angiography because it is not a 3D examination.

Recently, multidetector row CT coronary angiography has made it possible to demonstrate the anatomic variations of the coronary artery. With the rapid developments in sectional imaging techniques, multidetector CT coronary angiography provides accurate depiction of the origin and the traces of the coronary arteries non-invasively and with accuracy comparable to that of the invasive coronary angiography. 64-slice multidetector CT

is able to determine the continuous trace of the coronary vessels on MPR images or MIP images with excellent image quality, without stair step and motion artifacts. The 3D orientation, short procedure time, high patient comfort and the extra information on adjacent structures and great vessels are the main advantages of this procedure. The novel 64 section multidetector tomography devices that avoid the limitations related to heart rate and motion artifacts and provide high spatial and temporal resolutions, have shortened the procedure time.

In conclusion, 64-slice multidetector CT with its faster volume coverage and higher spatial and temporal resolutions allow accurate and noninvasive depiction of coronary artery anomalies of ostial origin, trace, and termination. It should be considered a major noninvasive imaging tool for suspected coronary artery anomalies.

## REFERENCES

- Kosar F, Ermis N, Erdil N, Battaloglu B. Anomalous LAD and CX artery arising separately from the proximal right coronary artery--a case report of single coronary artery with coronary artery disease. *J Card Surg* 2006;21:309-12.
- Aydinlar A, Çiçek D, Sentürk T, Gemici K, Serdar OA, Kazazoglu AR, et al. Primary congenital anomalies of the coronary arteries: a coronary arteriographic study in Western Turkey. *Int Heart J* 2005;46:97-103.
- Ong K, Chin SP, Chan WL, Liew CK, Seyfarth MT, Liew HB, et al. Feasibility and accuracy of 64-row MDCT coronary imaging from a centre with early experience: a review and comparison with established centres. *Med J Malaysia* 2005;60:629-36.
- Plass A, Grünenfelder J, Leschka S, Alkadhi H, Eberli FR, Wildermuth S, et al. Coronary artery imaging with 64-slice computed tomography from cardiac surgical perspective. *Eur J Cardiothorac Surg* 2006;30:109-16.
- Kimbiris D, Iskandrian AS, Segal BL, Bemis CE. Anomalous aortic origin of coronary arteries. *Circulation* 1978;58:606-15.
- Yamanaka O, Hobbs RE. Coronary artery anomalies in 126,595 patients undergoing coronary arteriography. *Cathet Cardiovasc Diagn* 1990;21:28-40.
- Felmeden D, Singh SP, Lip GY. Anomalous coronary arteries of aortic origin. *Int J Clin Pract* 2000;54:390-4.
- Veinot JP, Acharya VC, Bedard P. Compression of anomalous circumflex coronary artery by a prosthetic valve ring. *Ann Thorac Surg* 1998;66:2093-4.
- Taylor AJ, Rogan KM, Virmani R. Sudden cardiac death associated with isolated congenital coronary artery anomalies. *J Am Coll Cardiol* 1992;20:640-7.
- Jokl E, Mc Clellan JT, Ross GD. Congenital anomaly of left coronary artery in a young athlete. *JAMA* 1962;182:572-3.
- Cohen LS, Shaw LD. Fatal myocardial infarction in an 11 year old boy associated with a unique coronary artery anomaly. *Am J Cardiol* 1967;19:420-3.
- Frescura C, Basso C, Thiene G, Corrado D, Pennelli T, Angelini A, et al. Anomalous origin of coronary arteries and risk of sudden death: a study based on an autopsy population of congenital heart disease. *Hum Pathol* 1998;29:689-95.
- Kejriwal NK, Tan J, Gordon SP, Newman MA. Retroaortic course of the anomalous left main coronary artery: is it a benign anomaly? A case report and review of literature. *Heart Lung Circ* 2004;13:97-100.
- Wilkins CE, Betancourt B, Mathur VS, Massumi A, De Castro CM, Garcia E, et al. Coronary artery anomalies: a review of more than 10,000 patients from the Clayton Cardiovascular Laboratories. *Tex Heart Inst J* 1988;15:166-73.
- Chaitman BR, Lespérance J, Saltiel J, Bourassa MG. Clinical, angiographic, and hemodynamic findings in patients with anomalous origin of the coronary arteries. *Circulation* 1976;53:122-31.
- Bunce NH, Lorenz CH, Keegan J, Lesser J, Reyes EM, Firmin DN, et al. Coronary artery anomalies: assessment with free-breathing three-dimensional coronary MR angiography. *Radiology* 2003;227:201-8.
- Basso C, Maron BJ, Corrado D, Thiene G. Clinical profile of congenital coronary artery anomalies with origin from the wrong aortic sinus leading to sudden death in young competitive athletes. *J Am Coll Cardiol* 2000;35:1493-501.