

Isolated Epididymo-Orchitis in a Patient with Brucellosis: Case Report

Brusellozlu Hastada Tek Bulgu Olarak Görülen Epididimoörşit

Orhun SİNANOĞLU, MD,^a
Sinan EKİCİ, MD^a

^aDepartment of Urology,
Maltepe University Faculty of Medicine,
İstanbul

Geliş Tarihi/Received: 19.03.2010
Kabul Tarihi/Accepted: 30.04.2010

Yazışma Adresi/Correspondence:
Orhun SİNANOĞLU, MD
Maltepe University Faculty of Medicine,
Department of Urology, İstanbul,
TÜRKİYE/TURKEY
orhundr@hotmail.com

ABSTRACT Epididymoorchitis complication of brucellosis that may affect many organs and systems of the body had been reported in up to 20% of patients with brucellosis. However we seldom, if ever, see initial epididymoorchitis as a single manifestation of brucellosis. This is a case report of Brucella epididymoorchitis in a Turkish male patient. He presented with unilateral swelling and pain on the left testicle. He had no other accompanying symptoms like fever, arthralgia or night sweats for at least 8 days. Ultrasound examination revealed enlarged left epididymis and testicle. Brucella serology was positive and the patient responded to treatment with doxycycline and rifampicin. We conclude that in a patient from an endemic area, Brucella infection can emerge only in the form of epididymoorchitis.

Key Words: Brucella; epididymitis; orchitis

ÖZET Epididimoörşit, vücutta muhtelif organ ve sistemleri etkileyen brusellozun bir komplikasyonu olup %20 sıklıkla görülür. Ancak başlangıçtaki tek klinik bulgusu epididimoörşit olan bruselloz oldukça nadirdir. Biz burada, brusellozu olup başlangıçtaki tek klinik bulgusu epididimoörşit olan bir hastayı sunuyoruz. Hasta kliniğimize tek taraflı olarak testiste şişme ve ağrı ile gelmiştir. Ateş, artralji ve gece terlemeleri gibi eşlik eden bulguları bize gelmeden önceki 8 gün içinde de olmamıştır. Ultrason görüntüleme tetkikinde sol testis ve epididimde genişleme tespit edildi. Brusella serolojisi pozitif idi ve hasta doksisisiklin, rifampisin tedavisine olumlu yanıt verdi. Bu olguyla birlikte endemik bölgelerde epididimoörşit görüldüğü zaman bunun bruselloza bağlı olabileceğinin akılda tutulması gerektiği kanaatine varmaktayız.

Anahtar Kelimeler: Brusella; epididimit; orşit

Türkiye Klinikleri J Urology 2010;1(3):99-101

Brucella is characterized by the classic triad of fever, arthralgia/arthritis and hepatosplenomegaly.¹ Hematologic manifestations of brucellosis include anemia, leucopenia, thrombocytopenia and pancytopenia.^{2,3} Osteoarticular involvement of the axial skeleton described in the worldwide literature is the most common presentation of brucella infection.⁴ Genitourinary system involvement occurs in 2-20% of patients with brucellosis and includes prostatitis, epididymoorchitis, cystitis, pyelonephritis, interstitial nephritis, exudative glomerulonephritis and renal abscess. Epididymoorchitis is very rarely seen as an isolated manifestation of

this disease. We present a case with acute painful scrotal swelling which was the earliest sign of brucellosis.

CASE REPORT

A 53-year-old man presented with painful scrotal swelling for 5 days to our urology clinic. He had been administered with intramuscular cefazolin 1000 mg two times daily for five days. Physical examination revealed a tender and swelling left testis, the skin over the swelling testis was red with local rise of temperature. Hemoglobin, white blood cell, neutrophil and platelet counts were 10.19 g/dL, 8100/mm³, 6000/mm³ and 69000/mm³, respectively. Urinalysis showed white blood cells of 4-5/high power field (hpf). Color Doppler ultrasound displayed increased blood flow and an hypoechoic lesion suggesting early abscess formation in the left testis (Figure 1). Accumulation of peritesticular fluid in septae was also imaged (Figure 2). He was then administered with parenteral ciprofloxacin 200 mg two times daily. The treatment was unsuccessful, the swelling with pain increased and he began to have fever which rose up to 39°C after the third day at the hospital. White blood cell count increased to 15800/mm³. Although antibiotic treatment was switched to parenteral ceftriaxone and oral doxycycline, the fever was not resolved and the patient began to have bone pain over the sacroileal region on the 10th day of the treatment. When the history thoroughly questioned the patient gave a positive history of ingesting unpasteurized fresh cheese so that brucellosis was suspected. Serum brucella antibodies were positive at a dilution of 1:1280. He was administered doxycycline and

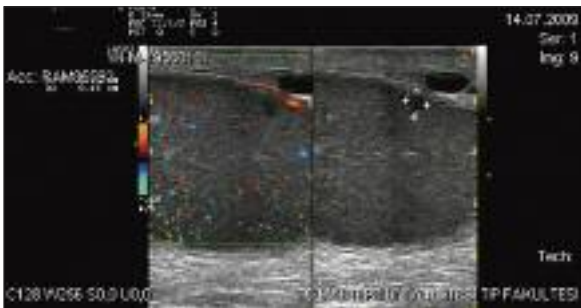


FIGURE 1: Increased blood flow and early abscess formation in the left testis.

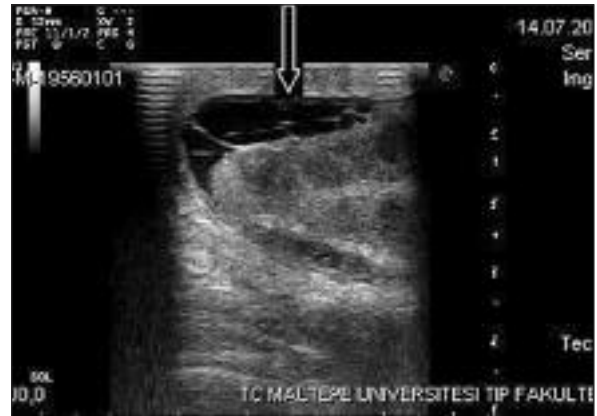

FIGURE 2: Septated fluid accumulation around the left testis.

rifampicin. Epididymo-orchitis began to improve on the 15th day and disappeared in the third week of the treatment. The sacroileal osteoarthritis was confirmed by the magnetic resonance imaging and responded well to triple treatment with rifampin, streptomycin and doxycycline after 4 weeks. Six months later serum Brucella antibodies were positive at a dilution of 1:320, both testis had smooth contours and no pain on palpation.

DISCUSSION

Brucellosis is a zoonotic disease, which may be caused by four Brucella species: *B. abortus*, *B. melitensis*, *B. suis* or *B. canis*.⁵ As a complication, epididymo-orchitis is found to occur in 1.6% of all patients with brucellosis, it accompanies other presenting symptoms which are undulant fever (96%), chills (54%) and arthralgia (23%).⁶ Isolated epididymo-orchitis with absence of these systemic symptoms and laboratory findings is reported to be very rare in the literature.⁷ The differentiation is important since delay of the specific treatment increases risk of contralateral testis involvement, necrosis and systemic manifestations.⁸ The majority of patients with Brucella epididymo-orchitis have initial agglutination titers of >1:320, and 53-69% of patients have positive blood cultures and 6.7% have positive culture from epididymal aspirations.⁵ Doxycycline plus rifampicin for 6 weeks or doxycycline (6 weeks) plus gentamicin for 2-3 weeks is usually prescribed for treatment. Alternatively, streptomycin intramuscularly and tetracycline,

with or without cotrimoxazole orally may be used in cases that do not respond to the standard therapy. The complication rate is usually low with 5% of patients developing necrotizing orchitis requiring orchiectomy. In this case report, epididymo-orchitis was the isolated manifestation during the

initial 8 days of the disease which, to our knowledge, has not been previously reported in the literature. In conclusion, brucella epididymo-orchitis should be a consideration in the differential diagnosis of patients presenting with signs and symptoms of this entity in endemic areas.

REFERENCES

1. Hasanjani Roushan MR, Mohrez M, Smailnejad Gangi SM, Soleimani Amiri MJ, Hajjahmadi M. Epidemiological features and clinical manifestations in 469 adult patients with brucellosis in Babol, Northern Iran. *Epidemiol Infect* 2004;132(6):1109-14.
2. Akdeniz H, Irmak H, Seçkinli T, Buzgan T, Demiröz AP. Hematological manifestations in brucellosis cases in Turkey. *Acta Med Okayama* 1998;52(1):63-5.
3. Karakucuk M, Patiroglu T, Ozdemir MA, Gunes T, Gumus H, Karakucuk C. Pancytopenia, a rare hematologic manifestation of brucellosis in children. *J Pediatr Hematol Oncol* 2004;26(12):803-6.
4. Memish Z, Mah MW, Al Mahmoud S, Al Shaalan M, Khan MY. Brucella bacteraemia: clinical and laboratory observations in 160 patients. *J Infect* 2000;40(1):59-63.
5. Papatsoris AG, Mpadra FA, Karamouzis MV, Frangides CY. Endemic brucellar epididymo-orchitis: a 10-year experience. *Int J Infect Dis* 2002;6(4):309-13.
6. Memish ZA, Venkatesh S. Brucellar epididymo-orchitis in Saudi Arabia: a retrospective study of 26 cases and review of the literature. *BJU Int* 2001;88(1):72-6.
7. Kocak I, Dündar M, Culhaci N, Unsal A. Relapse of brucellosis simulating testis tumor. *Int J Urol* 2004;11(8):683-5.
8. Alapont Alacreu JM, Gómez López L, Delgado F, Palmero Martí JL, Pacheco Bru JJ, Pontones Moreno JL, et al. [Brucellar orchiepididymitis]. *Actas Urol Esp* 2004;28(10):774-6.