

# Combined Treatment of Tongue Lymphangioma with Cryosurgery and Diode Laser Ablation in a Pediatric Patient: A Case Report with 6-Year Follow-Up

## Çocuk Hastada Dilde Görülen Lenfanjiyomanın Kriyocerrahi ve Diyet Lazer Ablasyonu ile Kombine Tedavisi: 6 Yıllık Takipli Bir Vaka Raporu

<sup>1</sup>Sercan KÜÇÜKKURT<sup>a</sup>, <sup>2</sup>Emre BARIŞ<sup>b</sup>, <sup>3</sup>Sedat ÇETİNER<sup>c</sup>

<sup>a</sup>Istanbul Aydın University Faculty of Dentistry, Department of Oral and Maxillofacial Surgery, İstanbul, Türkiye

<sup>b</sup>Gazi University Faculty of Dentistry, Department of Oral Pathology, Ankara, Türkiye

<sup>c</sup>Gazi University Faculty of Dentistry, Department of Oral and Maxillofacial Surgery, Ankara, Türkiye

**ABSTRACT** Lymphangiomas are rare malformations of the lymphatic system and usually affect the head and neck. They rarely occur intraorally, and when they develop in the mouth, they usually affect the tongue. Intraoral lesions can cause macroglossia, malocclusion, speech disorders, chewing difficulties, and airway obstruction. Various therapeutic options for treating such lesions include surgical excision, sclerotherapy, cryotherapy, laser treatments, steroid applications, and bleomycin. In this case report, a case of lymphangioma of the tongue was presented, which was detected prior to orthodontic treatment and could interfere with the treatment process. In this case, a more conservative surgical approach was adopted, and the lesion was first shrunk with sequential cryotherapy treatments, followed by excision with a diode laser. The six-year follow-up of the case with a stable course without recurrence after two-stage treatment is presented.

**ÖZET** Lenfanjiyomlar, lenfatik sistemin nadir görülen malformasyonlarıdır ve genellikle baş ve boyun bölgesini etkilerler. İntraoral olarak nadiren ortaya çıkarlar ve ağız içinde geliştiklerinde genellikle dil bölgesini etkilerler. Ağız içindeki lezyonlar, potansiyel olarak makroglossi, maloklüzyon, konuşma bozuklukları, çiğneme zorlukları ve havayolunun tıkanıklığı gibi sorunlara neden olabilirler. Bu tür lezyonların tedavisi için çeşitli terapötik seçenekler bulunmaktadır, bunlar arasında cerrahi eksizyon, skleroterapi, kriyoterapi, lazer tedavileri, steroid uygulamaları ve bleomisin gibi yöntemler bulunmaktadır. Bu olgu sunumunda, ortodontik tedavi öncesinde tespit edilen ve tedavi sürecini engelleyebilecek düzeyde olan dil lenfanjiyomuyla ilgili bir vaka sunulmaktadır. Bu vakada, daha konservatif bir cerrahi yaklaşım benimsenmiş ve önce ardışık kriyoterapi uygulamaları ile lezyon küçültülmüş, ardından da diyet lazer ile eksizyon gerçekleştirilmiştir. İki aşamalı tedavi sonrasında, nüks göstermeden stabil seyreden vakanın altı yıllık takibi sunulmuştur.

**Keywords:** Lymphangioma; tongue; cryosurgery; diode laser; child

**Anahtar Kelimeler:** Lenfanjiyoma; dil; kriyocerrahi; diyet lazer; çocuk

Lymphangiomas are congenital malformations of the lymphatic system, commonly presenting as cystic lesions resulting from abnormal lymphatic vessel development.<sup>1</sup> When found in the tongue, these growths can lead to significant functional impairments, in-

cluding difficulties in swallowing, speech disturbances, and respiratory complications.<sup>2-4</sup> Clinically, lymphangiomas are characterized by their soft, compressible nature, with surface variations ranging from normal mucosa to bluish or transparent appearances.<sup>4,5</sup>

**TO CITE THIS ARTICLE:**

Küçükkurt S, Barış E, Çetiner S. Combined treatment of tongue lymphangioma with cryosurgery and diode laser ablation in a pediatric patient: A case report with 6-year follow-up. Türkiye Klinikleri J Dental Sci. 2024;30(3):522-6.

**Correspondence:** Sercan KÜÇÜKKURT

Istanbul Aydın University Faculty of Dentistry, Department of Oral and Maxillofacial Surgery, İstanbul, Türkiye

**E-mail:** sercankucukkurt@aydin.edu.tr



Peer review under responsibility of Türkiye Klinikleri Journal of Dental Sciences.

**Received:** 10 Nov 2023

**Received in revised form:** 16 Jan 2024

**Accepted:** 18 Jan 2024

**Available online:** 24 Jan 2024

2146-8966 / Copyright © 2024 by Türkiye Klinikleri. This is an open access article under the CC BY-NC-ND license (<http://creativecommons.org/licenses/by-nc-nd/4.0/>).

Diagnosis typically occurs during childhood, with around 50% of cases identified at birth and the remaining 50% recognized later. Nearly 90% of cases develop in children younger than two years old, with no discernible relation to gender or familial tendency. Lymphangiomas constitute about 6% of all benign tumors in the pediatric population.<sup>4,5</sup>

Lymphangiomas initially track the patient's development and occasionally regress slowly. However, certain factors, such as repeated upper airway infections or traumas in tongue lymphangiomas, can lead to an enlargement of the tumor size, resulting in complications such as macroglossia and functional and aesthetic issues. They tend to become symptomatic during early childhood, often resulting in various complications such as speech disorders, difficulties maintaining oral hygiene and bleeding due to trauma.<sup>2,4,5</sup>

Histopathologically, lymphangiomas can be categorized as capillary, cavernous, or cystic based on the size and structure of the lymphatic vessels. Cavernous lymphangioma is the most common type found intraorally. These growths have been linked to various syndromes and anomalies, including Turner's syndrome, Noonan's syndrome, trisomies, cardiac anomalies, fetal hydrops, fetal alcohol syndrome, and Familial pterygium colli.<sup>5,6</sup> Differential diagnosis for lymphangioma involves several other conditions, such as hemangioma, teratoma, lingual thyroid, dermoid cyst, heterotopic gastric mucosal cyst, or granular cell tumor.<sup>7</sup>

In the presented case report, the comprehensive 6-year follow-up of a 9-year-old girl diagnosed with a lingual lymphangioma on the left half of the dorsal and ventral tongue is detailed. The treatment approach involved an initial reduction in size through cryosurgery, followed by complete excision using a diode laser.

## CASE REPORT

A 9-year-old girl was referred to Gazi University Faculty of Dentistry, Department of Oral and Maxillofacial Surgery in 2014 by her orthodontist because of a swelling on the left side of her tongue that had been present since birth and gradually increased over time.

After reviewing the patient's medical history, it was determined that the patient had no known systemic diseases, was not on regular medication, and no similar conditions were identified among close relatives.

Although the patient had difficulties chewing and speaking, the issue had not received significant attention from the patient or her family. The patient had malocclusion and an anterior open bite, prompting ongoing orthodontic treatment. The orthodontist speculated that the tongue swelling might contribute to the open bite and dental crowding, hindering the progress of orthodontic treatment and forcing the upper teeth to move forward while closing the mouth.

The swelling was non-painful, with no history of pus discharge or bleeding. Intraoral examination revealed multiple papular lesions on the left side of the tongue, including a few blood-filled papules and some lesions displaying coloration similar to the normal mucosa. Palpation indicated that the lesions were soft, non-tender, and exhibited a rough texture with bumps (Figure 1). The large lesion on the dorsum appeared as a nodular 30x20x10 mm structure with a multiple and transparent blister surface, typical of superficial lymphangiomas. The small lesion located at the tip of the tongue is approximately 10x5x5 mm in size. Based on these clinical features, a preliminary diagnosis of lymphangioma was considered.

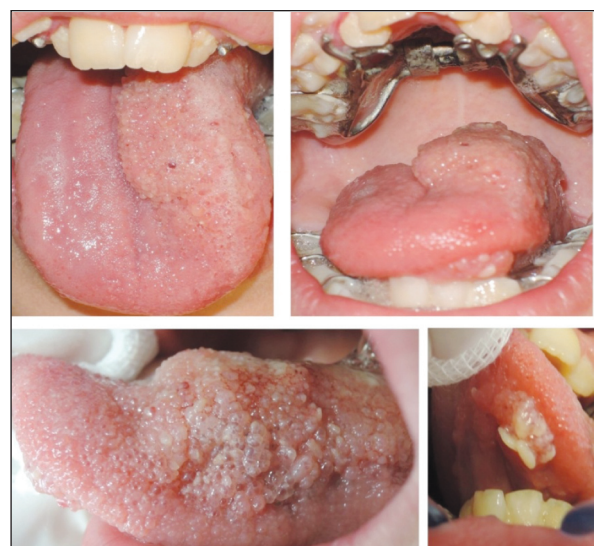
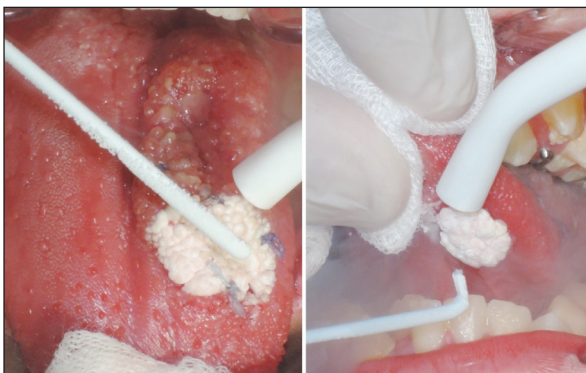
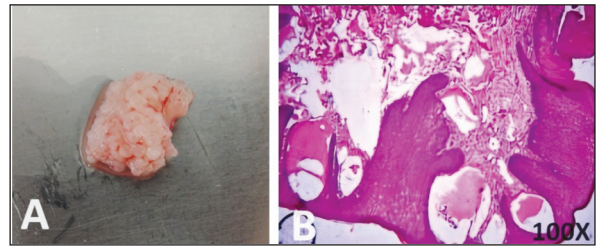
FIGURE 1: Clinical images of the lesion on the dorsal and ventral surface of the tongue.

The patient's family was informed about the condition, and a treatment plan was devised. The initial step involved managing the lymphangioma through multiple cryosurgery sessions aimed at reducing the lesion size. Following this, excision was planned using a diode laser. Informed consent forms were obtained from the patient's family before the procedure.

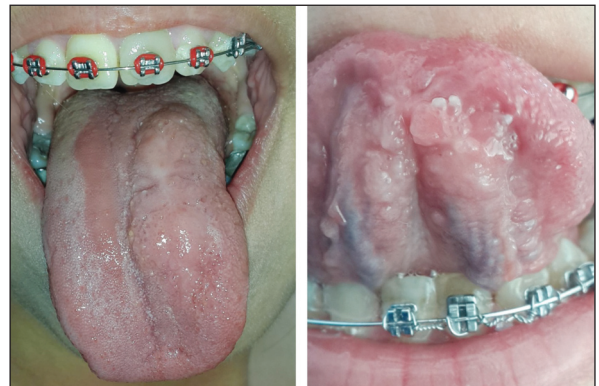During the first session, cryotherapy was applied to lesions on both the dorsal and ventral surfaces. Subsequent cryotherapy sessions were conducted at two-week intervals. The large lesion on the dorsum was treated by dividing it into four imaginary equal sections, and each imaginary part received one-minute cryotherapy sessions. The small lesion on the ventral surface was also treated in one-minute sessions (Figure 2). An incisional biopsy was taken during this stage for pathological examination, with the tissue subsequently processed and stained with hematoxylin and eosin. The histopathological analysis uncovered multiple expanded lymphatic passages, encompassed by a solitary layer of endothelial cells featuring flattened to oval nuclei, brimming with lymph and sporadic inflammatory cells. These enlarged vessels resided immediately below the epithelial layer, with scarce connective tissue stroma dividing them from the epithelial surface above. The connective tissue stroma displayed regions of lymph accumulation, while the overlying epithelium appeared as parakeratinized stratified squamous epithelium, confirming the lymphangioma diagnosis (Figure 3).



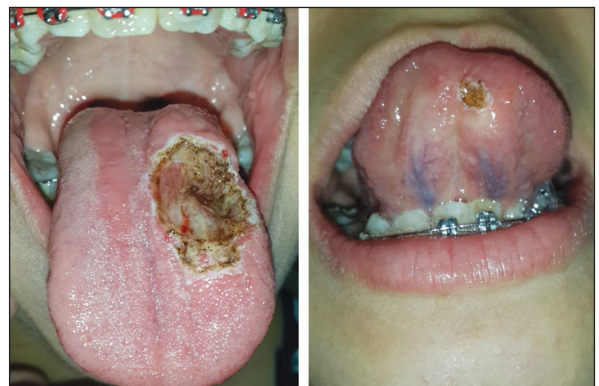**FIGURE 2:** Images taken during cryotherapy applications to the lesion following incisional biopsy.



**FIGURE 3:** A) Incisional biopsy specimen; B) Histological appearance of the abundant expanded lymph vessels, encompassed by a sole endothelial cell layer and replete with lymph fluid (H&E,  $\times 100$ ).



**FIGURE 4:** The situation of the lesion one month after three sessions of cryotherapy. At this stage, diode laser excision was performed.



**FIGURE 5:** Clinical images taken during the excision of the lesion with the help of diode laser.

Following a one-month interval, the remaining lesion was excised in a single session using a diode laser (LAMBDA Medical laser technologies/Vicenza-Italy, doctorSmile erbium&diode laser, wavelength 808 nm, 300 second duration, pulsed mode and 2 watts) under local anesthesia, with no requirement for sutures (Figure 4, Figure 5).

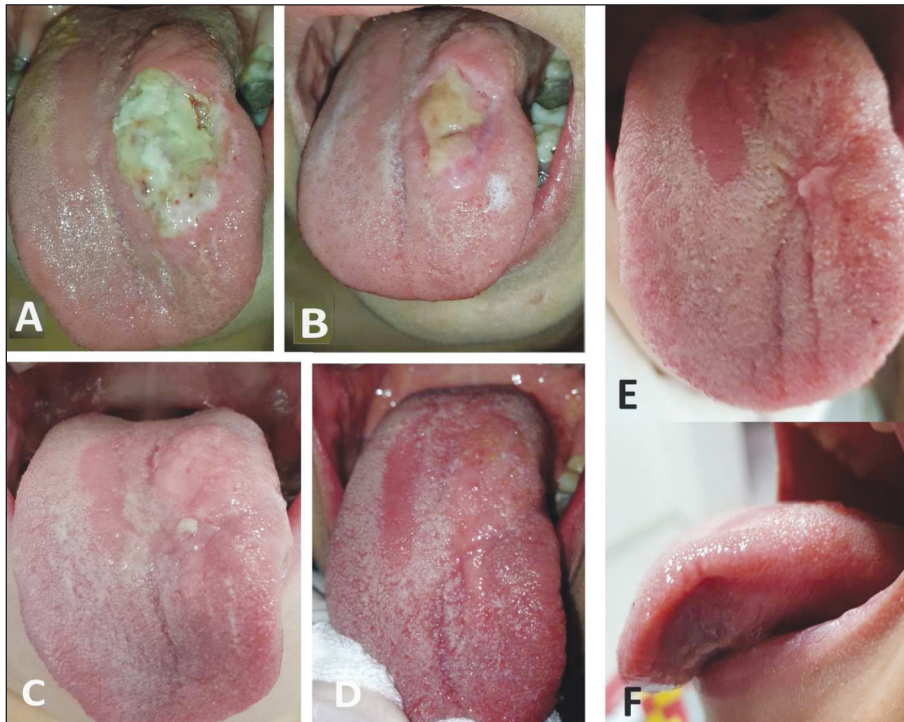


FIGURE 6: A) First week after laser excision; B) Second week; C) First month; D) Fourth month; E-F) Clinical appearance after six years.

Postoperative follow-ups were conducted at one (Figure 6A) and two weeks (Figure 6B) and again at one (Figure 6C) and four months (Figure 6D), revealing no signs of infection or complications. The patient reported experiencing numbness and taste problems in the treated area. Six years after surgery, no lesion recurrence was seen and the patient reported that the initial numbness and taste problems had improved significantly and did not affect the patient's quality of life (Figure 6E, Figure 6F).

## DISCUSSION

Lymphangiomas have the potential to develop in various body regions, typically presenting as masses or cysts. Their predominant manifestation occurs in the head and neck regions, with approximately 75%.<sup>1</sup> While they seldom affect the oral cavity, they can still emerge on the tongue, palate, gingiva, lips, and alveolar ridge. Around 36% of lesions on the tongue are located on the dorsal surface of the tongue.<sup>1,2,5,8,9</sup> In the presented case, the involvement of the tongue extended to the dorsal aspect, tip, and base, underscoring the unusual nature of this manifestation.

Surgical treatment of tongue lesions requires particular attention to preserving taste, if possible, as the structural integrity of the tongue plays a crucial role in the speech development of pediatric patients, highlighting the importance of early diagnosis. Treatment options for lymphangiomas depend on the tumor's type, size, and anatomical involvement. Available methods include surgical excision, radiation therapy, cryotherapy, electrocautery, sclerotherapy, steroid administration, embolization, ligation, and various forms of laser surgery.<sup>3,5,8</sup> Non-surgical treatments, including the use of sclerosing agents, radiation therapy, cryosurgery, and intralesional steroids, have been attempted when complete excision is not feasible. However, these treatments have demonstrated limited effectiveness and can carry various side effects.<sup>1,6,8,10,11</sup>

In the case presented, the patient experienced an enlarged tongue from birth, leading to feeding difficulties and malnutrition. Additionally, the patient encountered impaired speech and an anterior open bite due to the enlarged tongue. Consequently, she commenced orthodontic treatment and was referred to us

by the orthodontist. A phased treatment plan was devised, initiating with cryosurgery as a conservative measure to reduce the lesion's size before its complete excision. Three cryosurgery sessions at two-week intervals effectively reduced the lesion's size to a more manageable extent. The remaining lesion was then excised using a Diode laser, with no recurrence observed during the 6-year follow-up period. Cryosurgery demonstrated its effectiveness in treating small-sized lymphangiomas and reducing larger lesions. Moreover, the Diode laser application provided a comfortable and efficient option for excision, ensuring clinical bleeding control in a region prone to bleeding, such as the tongue, as observed in this case.

### Source of Finance

During this study, no financial or spiritual support was received neither from any pharmaceutical company that has a direct

connection with the research subject, nor from a company that provides or produces medical instruments and materials which may negatively affect the evaluation process of this study.

### Conflict of Interest

No conflicts of interest between the authors and / or family members of the scientific and medical committee members or members of the potential conflicts of interest, counseling, expertise, working conditions, share holding and similar situations in any firm.

### Authorship Contributions

**Idea/Concept:** Sedat Çetiner; **Design:** Sercan Küçükkurt; **Control/Supervision:** Sedat Çetiner, Emre Barış; **Data Collection and/or Processing:** Sercan Küçükkurt; **Analysis and/or Interpretation:** Sedat Çetiner, Emre Barış; **Literature Review:** Sercan Küçükkurt; **Writing the Article:** Sercan Küçükkurt; **Critical Review:** Sedat Çetiner, Emre Barış; **References and Fundings:** Sedat Çetiner, Sercan Küçükkurt; **Materials:** Sercan Küçükkurt.

## REFERENCES

- Júnior FN, da Silva EJ, Paz ALLM, Volpato LER. Extensive tongue lymphangioma followed for eight years: case report. *J Oral Maxillofac Pathol.* 2023;27(Suppl 1):S6-S9. [Crossref] [PubMed] [PMC]
- Nelson BL, Bischoff EL, Nathan A, Ma L. Lymphangioma of the dorsal tongue. *Head Neck Pathol.* 2020;14(2):512-5. [Crossref] [PubMed] [PMC]
- Nagpal T, Shah D, Manjunatha BS, Mahajan A. Macroglossia associated with lymphangioma: surgical management of an interesting case. *J Clin Diagn Res.* 2015;9(11):ZD04-6. [PubMed] [PMC]
- Kayhan KB, Keskin Y, Kesimli MC, Uluşan M, Ünür M. Lymphangioma of the tongue: report of four cases with dental aspects. *Kulak Burun Bogaz İhtis Derg.* 2014;24(3):172-6. [Crossref] [PubMed]
- V U, Sivasankari T, Jeelani S, Asokan GS, Parthiban J. Lymphangioma of the tongue - a case report and review of literature. *J Clin Diagn Res.* 2014;8(9):ZD12-4. [PubMed] [PMC]
- Kataria P, Passey JC, Agarwal AK. Lymphangioma circumscriptum of the tongue: successful treatment using intralesional bleomycin. *J Laryngol Otol.* 2009;123(12):1390-2. [Crossref] [PubMed]
- de Queiroz AM, Silva RA, Margato LC, Nelson-Filho P. Dental care management of a young patient with extensive lymphangioma of the tongue: a case report. *Spec Care Dentist.* 2006;26(1):20-4. [Crossref] [PubMed]
- Aires AV, Kato CNAO, Silva LVO, de Andrade RS, Martelli Júnior H, Ferreira MVL, et al. Lingual lymphangioma ablation with high power diode laser: a case report. *J Lasers Med Sci.* 2020;11(2):234-7. [Crossref] [PubMed] [PMC]
- Eren S, Cebi AT, Isler SC, Kasapoglu MB, Aksakalli N, Kasapoglu C. Cavernous lymphangioma of the tongue in an adult: a case report. *J Istanbul Univ Fac Dent.* 2017;51(2):49-53. [Crossref] [PubMed] [PMC]
- Hwang J, Lee YK, Burm JS. Treatment of Tongue Lymphangioma with Intralesional Combination Injection of Steroid, Bleomycin and Bevacizumab. *Arch Craniofac Surg.* 2017;18(1):54-8. [Crossref] [PubMed] [PMC]
- Chakravarti A, Bhargava R. Lymphangioma circumscriptum of the tongue in children: successful treatment using intralesional bleomycin. *Int J Pediatr Otorhinolaryngol.* 2013;77(8):1367-9. [Crossref] [PubMed]