

A Case of Darier's Disease Unresponsive to Cyclosporine Therapy

Siklosporin Tedavisine Yanıt Alınamayan Bir Darier Hastalığı Olgusu

Arzu KILIÇ, MD,^a
Seher BİLGİLİ, MD,^a
Ülker GÜL, MD,^a
Müzeyyen GÖNÜL, MD,^a
Murat DEMİRİZ, MD^b

^a2nd Dermatology Clinic,
Ankara Numune Education and
Research Hospital,

^bDepartment of Pathology,
GATA School of Medicine, ANKARA

Geliş Tarihi/Received: 19.07.2007
Kabul Tarihi/Accepted: 05.09.2007

Yazışma Adresi/Correspondence:
Arzu KILIÇ, MD
Ankara Numune Education and
Research Hospital,
2nd Dermatology Clinic, Ankara
TÜRKİYE/TURKEY
kilicarzu@gmail.com

ABSTRACT Darier-White (Darier's) disease is a rarely seen autosomal dominant disease characterized by keratotic papules which develop preferentially on seborrheic areas. The most accepted therapies used in generalized Darier's disease are oral retinoids. In addition, cyclosporine therapy has been reported with conflicting results in the treatment of Darier's disease. In this report, we present a 34-year-old man with Darier's disease. He had been treated with systemic retinoids for a long time without any benefit. Cyclosporine therapy was started and continued for six months. However, the lesions also did not regress with this treatment.

Key Words: Cyclosporine; keratosis follicularis; therapy

ÖZET Darier-White (Darier) hastalığı, özellikle seboreik bölgelerde gelişen keratotik papüllerle karakterize nadir gözlenen otozomal dominant bir hastalıktır. Yaygın Darier hastalığında en çok kabul görmüş tedavi oral retinoidlerdir. Darier hastalığının tedavisinde siklosporin tedavisi çelişkili sonuçlarla bildirilmiştir. Bu yazıda, 34 yaşındaki Darier hastalığı olan erkek olguyu sunuyoruz. Olgu uzun süredir sistemik retinoid tedavisi alıyordu ancak bu tedaviden herhangi bir fayda görmemişti. Hastaya siklosporin tedavisi başlandı ve altı ay süreyle devam edildi. Ancak lezyonları bu tedaviyle de gerilemedi.

Anahtar Kelimeler: Siklosporin; keratozis folikülaris; tedavi

Türkiye Klinikleri J Dermatol 2009;19(1):43-5

Darier's disease, also known as keratosis follicularis, is an uncommon autosomal dominant disorder.¹ It is characterized by symmetrical multiple hyperkeratotic or crusted papules localized on seborrheic areas with characteristic histological findings.^{1,2}

The treatment of Darier's disease is usually unsatisfactory. The most frequently used systemic therapies in the treatment of severe Darier's disease are oral (etretinate, acitretin, isotretinoin) and topical retinoids.^{1,2} There are a few published reports about the use of cyclosporine therapy against Darier's disease with variable outcomes.³⁻⁶ As Darier's disease is a keratinization disorder and an altered lymphocytic response to mitogens, particularly involving T lymphocytes have been reported in etiopathogenesis of Darier's disease,³ cyclosporine therapy was started in our patient. Herein, we report a case with generalized Darier's disease that did not response to cyclosporine therapy.

A 34-year-old man presented with widespread eruption on his trunk (Figure 1). He had been suffering from these lesions for 15 years. His mot-

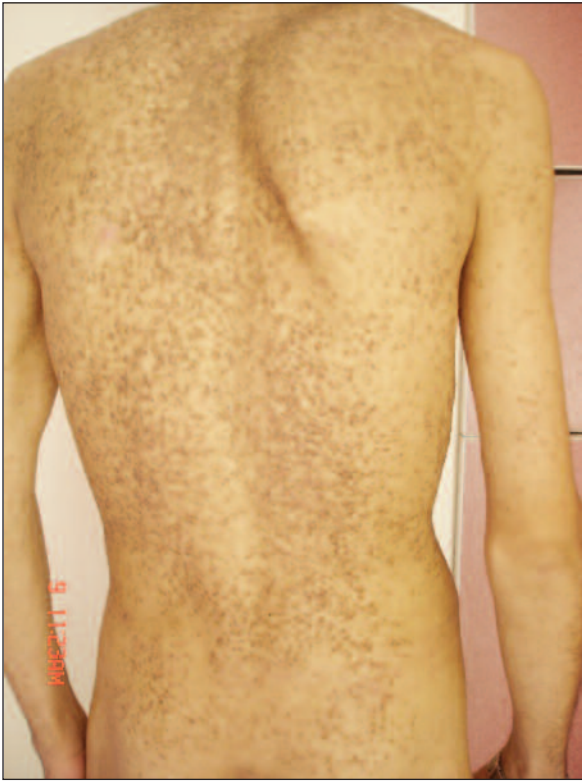

FIGURE 1: The appearance of the skin lesions before cyclosporine therapy.

her, both of his sons and daughter also had the same disease with variable clinical involvements. Before he had admitted to our clinic, he had been treated several times with topical retinoids and systemic retinoids with partial benefit.

On dermatological examination, there were warty brown papules coalescing to form large patches on his face, trunk, bilateral extremities, gluteas, both of the axillary and inguinal regions.

The routine laboratory tests including complete blood count, proteins, electrolytes, lipids, immunoglobulins, renal and liver functions were normal. The histopathological examination of the biopsy of the lesions was consistent with Darier's disease (Figure 2). Oral cyclosporine therapy 3.5 mg/kg/day was started. The other local treatments were discontinued a month before starting cyclosporine therapy. The treatment of the patient was started in our hospital and the patient was kept in hospital for the first two weeks of the therapy. Later, he was evaluated every month. In each visit, he was evaluated by the same dermatologist, his

skin lesions were observed and photographed, and routine laboratory tests were done. No pathology was detected in laboratory findings during the subsequent control visits. During the treatment, the patient's complaint about pruritus decreased; however, there was no change in the severity of the

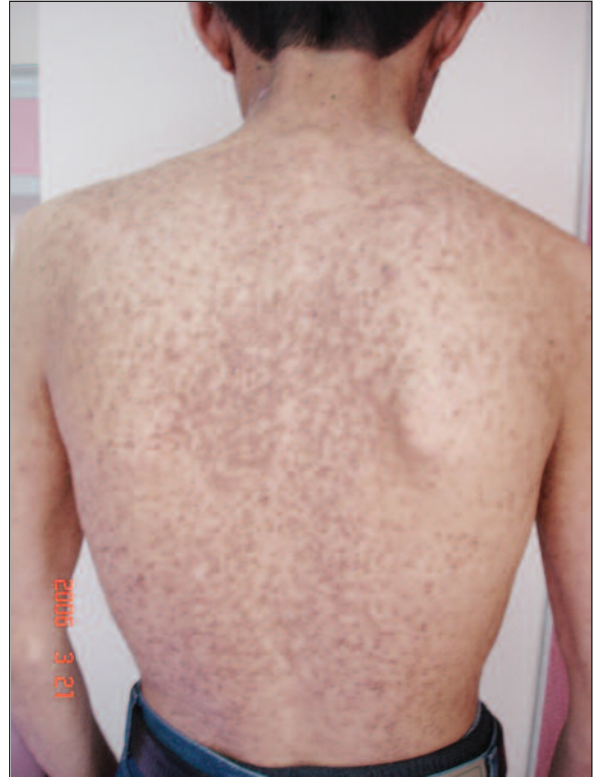

FIGURE 2: After six months of the cyclosporine therapy, the appearance of the skin lesions.

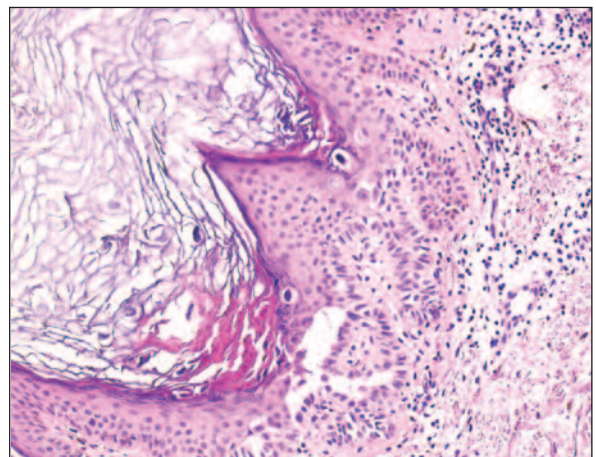


FIGURE 3: The appearance of suprabasal acantholysis and dyskeratotic cells (HE, x 200).

lesions. After six months, not only the old lesions were still present but also new lesions appeared continuously. Therefore, we discontinued the treatment (Figure 3).

The exact mechanism of cyclosporine in Darier's disease is not known. Its effect is probably due to inhibition of lymphocyte activation and proliferation by suppression of the cytokines IL-2, IL-4 and interferon- γ . The use of cyclosporine as a therapy against Darier's disease was reported previously in literature with contradicting results. Martini et al reported a patient who was treated successfully with cyclosporine at a dose of 3 mg/kg/day. However, about three months after discontinuation of the therapy, the lesions relapsed.³ Shahidullah et al reported a patient with Da-

rier's disease with a severe eczematization and who was treated with the same dose of cyclosporin with good results.⁴ However, our patient's skin lesions showed no change with the same therapy after six months.

There are reports with conflicting results about cyclosporine in Darier's disease. Cyclosporine therapy may be useful in Darier's disease. However, cyclosporine has significant side effects especially in long term treatment. Long term side effects of cyclosporine in chronic and hereditary diseases such as Darier's disease should also be considered and patients should be carefully screened. Therefore, further studies should be made to confirm the effectiveness of cyclosporine therapy in the treatment of Darier's disease.

REFERENCES

1. Zeglaoui F, Zaraa I, Fazaa B, Houimli S, El Fekih N, Ezzine N, et al. Dyskeratosis follicularis disease: case reports and review of the literature. *JEADV* 2005;19(1):114-7.
2. Burge S. Management of Darier's disease. *Clin Exp Dermatol* 1999;24(2):53-6.
3. Martini P, Peonia G, Benedetti A, Lorenzi S. Darier-White syndrome and cyclosporin. *Dermatology* 1995;190(2):174-5.
4. Shahidullah H, Humphreys F, Beveridge GW. Darier's disease: severe eczematization successfully treated with cyclosporin. *Br J Dermatol* 1994;131(5):713-6.
5. Gupta AK, Ellis CN, Nickoloff BJ, Goldfarb MT, Ho VC, Rocher IL, et al. Oral cyclosporine in the treatment of inflammatory and noninflammatory dermatoses. A clinical and immunopathologic analysis. *Arch Dermatol* 1990; 126(3): 339-50.
6. Larbre B, Nicolas JF, Frappaz A, Thiovelet J. [Cyclosporine and Darier's disease]. *Ann Dermatol Venereol* 1993;120(4):310-1.