

# The Effects of Long-Term Use of Pregabalin on Reproductive Endocrine Hormones and Testicular Morphology in Adult Male Rats

## Uzun Süreli Pregabalin Kullanımının Erişkin Erkek Sıçanların Üreme Hormonları ve Testis Morfolojileri Üzerine Etkileri

Burçak BİLGİNER, MD<sup>a</sup>,  
Bülent Mehmet ÖNAL, MD<sup>a</sup>,  
Fırat NARİN, MD<sup>a</sup>,  
Işıl Zennure YILDIZ, MD<sup>b</sup>,  
Oğuz Alp GÜRBÜZ, MD<sup>c</sup>,  
Eser Lay ERGÜN, MD<sup>d</sup>,  
Alev ÖZÖN, MD<sup>e</sup>,  
Nejat AKALAN, MD<sup>a</sup>

Departments of <sup>a</sup>Neurosurgery,  
<sup>b</sup>Pathology, <sup>c</sup>Nuclear Medicine,  
<sup>e</sup>Pediatrics, Division of Endocrinology,  
Hacettepe University  
Faculty of Medicine,  
<sup>d</sup>Department of Microbiology,  
Diskapi Yıldırım Beyazıt Education and  
Training Hospital, Ankara

Geliş Tarihi/Received: 21.06.2008  
Kabul Tarihi/Accepted: 10.03.2009

Yazışma Adresi/Correspondence:  
Burçak BİLGİNER, MD  
Hacettepe University  
Faculty of Medicine,  
Department of Neurosurgery, Ankara,  
TÜRKİYE/TURKEY  
burcak@tr.net

**ABSTRACT Objective:** The reproductive system is affected by both epilepsy and antiepileptic drugs. Reduced fertility associated with usage of antiepileptic drugs has been reported in both men and women with epilepsy. This study was conducted to assess the effects of long-term use of pregabalin on reproductive endocrine hormones and testicular morphology in adult male rats. **Material and Methods:** Thirty adult male Wistar rats were included in the study and were divided into two groups. The treatment group (n= 20) was fed orally through a gastric tube with pregabalin twice daily for 60 days. The pregabalin mixture was prepared by dissolving pregabalin in distilled water. The treatment group rats received 40 mg/kg pregabalin solution twice daily. Control group animals received only distilled water. The results were analyzed using the Mann-Whitney U test. **Results:** Pregabalin caused a slight decrease in body weight in the experimental group when baseline and final body weights were compared. Serum free testosterone levels were decreased in the pregabalin-treated group when compared with the control group; this difference was statistically significant. There was no significant difference between the pregabalin-treated rats and the rats receiving control solution regarding follicle stimulating hormone (FSH), luteinizing hormone (LH) and sex hormone binding globulin (SHBG) levels. Serum biochemical markers including alanine aminotransferase, aspartate aminotransferase, total protein, triglycerides and cholesterol were within normal ranges. Seminiferous tubule epithelium thickness was increased and tubule diameters were decreased in the treatment group compared to the control group. **Conclusion:** We suggest that the Leydig cells with a primary function of secreting testosterone are mildly affected by pregabalin.

**Key Words:** Pregabalin, fertility, anticonvulsants, models, animal

**ÖZET Amaç:** Üreme sisteminin hem epilepsi olgularında hem de epilepsi tedavisinde kullanılan antiepileptik ilaçlarla tedavi görenlerde etkilenimi söz konusudur. Antiepileptik ilaçların kullanımına bağlı olarak fertilitede azalma, hem erkek hem de kadın epileptik olgularda söz konusu olabilir. Bu çalışma, bir antiepileptik ilaç olan pregabalinin uzun süreli kullanımının erkek sıçanların üreme hormonları ve testiküler morfolojileri üzerindeki etkilerini araştırmak için planlanmıştır. **Gereç ve Yöntemler:** Bu amaçla 30 adet erkek Wistar sıçan çalışmaya alınmış ve bu sıçanlar çalışma ve kontrol grubu olarak ikiye ayrılmıştır. Çalışma grubuna (n= 20) nazogastrik tüp yardımıyla günde iki kez olacak şekilde 60 gün süreyle 40 mg/kg pregabalin oral yoldan verilmiştir. Pregabalin distile su kullanılarak eriyik hale getirilmiştir. Kontrol grubuna ise sadece distile su verilmiştir. Verilerin karşılaştırılması için Mann-Whitney U testi kullanılmıştır. **Bulgular:** İki grubun başlangıçta ve deney sonundaki vücut ağırlıkları karşılaştırıldığında, pregabalin alan grupta hafif bir azalma olduğu gözlemlendi. Kontrol grubu ile karşılaştırıldığında serum serbest testosteron düzeyleri, tedavi grubunda düşük bulundu ve bu istatistiksel olarak anlamlı idi. Folikül stimüle edici hormon (FSH), luteinizan hormon (LH) ve seks hormonu bağlayıcı globülin (SHBG) düzeyleri açısından bakıldığında, kontrol ve tedavi grupları arasında anlamlı bir fark saptanmadı. Kan biyokimyasında alanin aminotransferaz, aspartat aminotransferaz, total protein, trigliserid ve kolesterol düzeyleri normal sınırlardaydı. Histolojik olarak kontrol grubu ile karşılaştırıldığında, tedavi grubunda seminifer tübül epitel kalınlığının artmış ve tübül çaplarının azalmış olduğu saptandı. **Sonuç:** Ana görevi testosteron sekresyonu yapmak olan Leydig hücrelerinin pregabalin tarafından orta derecede etkilendiği gözlemlenmiştir.

**Anahtar Kelimeler:** Pregabalin, fertilitate, antiepileptik ilaçlar, hayvan modeli

Historically, studies on the interactions between epilepsy, antiepileptic drugs (AEDs) and the reproductive system originated in the 1850s. Numerous studies have been conducted since then and today it is well known that reproductive endocrine disorders are more common among patients with epilepsy than in the general population. These endocrine disorders are not only attributed to the epilepsy itself, but also to the use of AEDs. Signs of reproductive endocrine dysfunction have been reported in both women and men with epilepsy.<sup>1-3</sup>

Pregabalin ((*S*)-(aminomethyl)-5-methylhexanoic acid or *S*-(+)-3-isobutylGABA) is a novel amino acid compound that binds with high affinity to the  $\alpha_2$ -delta ( $\alpha_2$ - $\delta$ ) auxiliary protein of voltage-gated calcium channels.<sup>4</sup> In addition to its antiepileptic effects, it prevents pain-related behavior<sup>5,6</sup> and has anxiolytic-like activity<sup>7-9</sup> both in rodent models and in humans.

In this study, the effects of long-term ingestion of pregabalin on sex hormones were investigated in adult male rats.

## MATERIAL AND METHODS

Thirty adult male Wistar rats were included in the study. The rats were caged in triplet in Macrolon 3 cages at constant temperature and humidity on a 12-hour light/dark cycle at an air exchange rate of 18 changes/hour. The rats were fed B&K pellet rat diet and were permitted tap water *ad libitum*. The Animal Ethical Committee of the Hacettepe University, Ankara, Turkey approved the study.

The rats were divided into two groups. The treatment group ( $n=20$ ) was fed orally through a gastric tube with pregabalin twice daily for 60 days. The pregabalin mixture was prepared by dissolving pregabalin in distilled water. The treatment group rats received 40 mg/kg pregabalin solution twice daily. Control group animals received only distilled water. After 60 days, all animals were weighed and then were sacrificed by means of exsanguination under pentobarbital narcosis by abdominal artery puncture 6 hours after their last medication. Blood was collected and serum was frozen at  $-20^{\circ}\text{C}$  until analysis. Sperm samples were

collected for fresh analysis and then each testicle was fixed in 4% formaldehyde for pathological examination.

## HISTOLOGY

Testicular tissue specimens were fixed in 4% neutral buffered formaldehyde. The specimens were routinely processed, embedded in paraffin, and 5  $\mu\text{m}$  thick sections were cut and stained with hematoxylin and eosin for light microscopic evaluation. This procedure was performed in a blinded fashion.

## SPERM MOTILITY AND COUNT

To determine these parameters, 100 mg of cauda epididymides was minced in 2 mL of physiological saline. One drop of an evenly mixed sample was applied to a Neubauer's counting chamber under a cover slip. Quantitative motility expressed as a percentage was determined by counting both motile and immotile spermatozoa per unit area. Cauda epididymal and testicular sperm counts were made by routine procedure and were expressed as million/mL of suspension.<sup>10</sup>

## HORMONE ANALYSIS

Serum free testosterone (fT) concentrations were measured by radioimmunoassay using kits obtained from Biosource Europe S.A. (Nivelles, Belgium), and sex hormone binding globulin (SHBG) concentrations were analyzed by radioimmunoassay using kits obtained from ZenTech (Angleur, Belgium). Serum follicle-stimulating hormone (FSH) and luteinizing hormone (LH) levels were measured using kits obtained from Architect System (Abbott Laboratories, IL, USA).

## BIOCHEMICAL ANALYSIS

Serum aspartate aminotransferase (AST), alanine aminotransferase (ALT), total protein, triglycerides and cholesterol levels were measured using commercial kits.

## BODY AND TESTICULAR WEIGHTS

Initial and final body weights of the animals were recorded. Testicles of each animal were measured separately on an electronic balance.

## STATISTICAL ANALYSIS

Statistical comparisons were performed using the Mann-Whitney U test (SPSS 11.5, Chicago, USA, Computer Program). Data were expressed as mean  $\pm$  SD. Statistical significance was accepted at  $< 0.05$ .

## RESULTS

All animals tolerated the treatment and the gastric tube feeding without any signs of discomfort and no mortality was observed during the study. There was no reduction in motor activity or other changes in the behavior of the animals.

Pregabalin caused a slight decrease in body weight in the experimental group, when initial and final body weights were compared (Table 1), but the difference was not significant. Similarly, no significant difference in testicular weights of the study group animals was detected compared to the controls (Table 1). The histopathological findings in the testicles of the rats were classified as normal, slight, moderate and diffuse atrophy.<sup>11</sup> According to this classification, all animals in the study group were classified as normal.

Seminiferous tubule epithelium thickness was increased in the treatment group (53.45  $\mu$ m) compared to the controls (46.1  $\mu$ m) (Mann-Whitney U= 49.0,  $n_1= 20$ ,  $n_2= 10$ ,  $p< 0.05$ , two-tailed). On the other hand, tubule diameters were decreased in the treatment group (378.5  $\mu$ m) when compared to the control group (409.5  $\mu$ m) (Figure 1), but this difference also was not significant

(Mann-Whitney U= 78.0,  $n_1= 20$ ,  $n_2= 10$ ,  $p> 0.05$ , two-tailed) (Table 1).

Total sperm count and motility were similar in the treatment group and controls (Table 1). Serum fT levels were decreased in the pregabalin-treated group (1.22 nmol/L) when compared with the control group (9.69 nmol/L), and this was statistically significant (Mann-Whitney U= 19.0,  $n_1= 20$ ,  $n_2= 10$ ,  $p< 0.05$ , two-tailed) (Table 2). There was no significant difference between the pregabalin-treated rats and the rats receiving control solution regarding FSH, LH and SHBG levels (Table 2).

Serum biochemical markers including AST, ALT, total protein, triglycerides and cholesterol were within normal ranges.

## DISCUSSION

Today it is well known that sexual dysfunction is common among both men and women with epilepsy.<sup>1</sup> Not only the seizures, but the antiepileptic medications as well can disturb reproductive health.<sup>1</sup> The release of anterior pituitary gonadotropins is under the control of the hypothalamic gonadotropin-releasing hormone (GnRH). GnRH is released episodically to stimulate pulsatile release of the pituitary gonadotropins FSH and LH. Under LH stimulation, Leydig cells of the testes secrete testosterone. FSH drives the production of spermatozoa by Sertoli cells, which also secrete inhibin. Inhibin is the major feedback regulator of FSH secretion in man.<sup>12</sup>

Connell et al. showed that with carbamazepine administration for 7 days, levels of SHBG increased significantly in healthy males, whereas levels of testosterone, fT, DHEAS and androstenedione fell. The authors concluded that these changes might explain the sexual dysfunction in some patients with epilepsy receiving long-term AED therapy.<sup>13</sup>

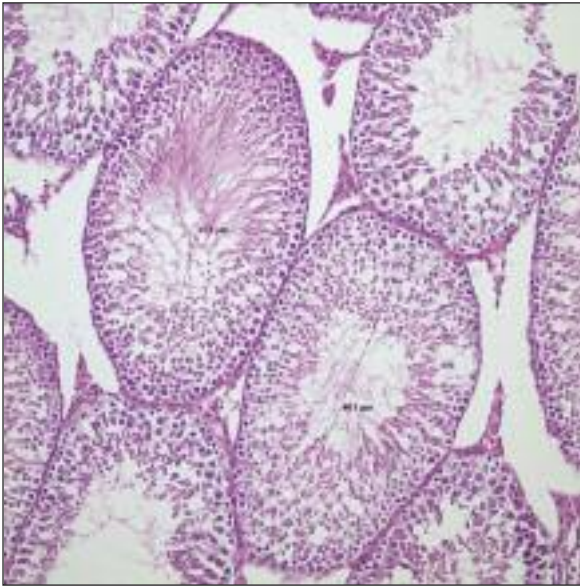
Decreased levels of fT in the treatment group in our study may point to a deterioration of Leydig cell function, lowering hormone-secreting capacity of the testis. Since testosterone levels of the treatment group did not fall below the normal range for adult male rats, the effect of pregabalin on hormo-

**TABLE 1:** Effects of pregabalin treatment on body weight and testicular morphology.

	Pregabalin (n= 20)	Control (n= 10)	U	p
Body weight (g)				
Initial	241.7 $\pm$ 8.07	241.6 $\pm$ 5.46	97.000	0.895
Final	241.5 $\pm$ 2.76	243.5 $\pm$ 3.27	42.500	0.010*
Testicular weight (g)	1.27 $\pm$ 0.67	1.33 $\pm$ 0.92	63.000	0.084
Total sperm count (x 10 <sup>6</sup> )	93.75 $\pm$ 27.16	94.9 $\pm$ 30.97	92.000	0.724
Sperm motility (x 10 <sup>6</sup> )	62.2 $\pm$ 1.96	75.3 $\pm$ 1.85	54.000	0.056
Seminifer tubule diameter ( $\mu$ m)	378.5 $\pm$ 96.5	409.5 $\pm$ 63.4	78.000	0.333
Seminifer epithelium thickness ( $\mu$ m)	53.45 $\pm$ 8.45	46.1 $\pm$ 8.73	49.000	0.025*

Results are expressed as mean  $\pm$  SD,

\*Statistically significant ( $p< 0.05$ ).



**FIGURE 1:** Seminiferous tubule epithelium thickness ( $53.45 \pm 8.45$ ; mean  $\pm$  SD) and tubule diameters ( $378.5 \pm 96.5$ ; mean  $\pm$  SD) are shown in the treatment group, stained with hematoxylin and eosin for light microscopic evaluation ( $\times 20$ ).

**TABLE 2:** Effects of pregabalin treatment on endocrine functions.

	Pregabalin (n= 20)	Control (n= 10)	U	p
Free Testosterone (nmol/l)	$1.22 \pm 1.08$	$9.69 \pm 7.96$	19.000	0.000*
SHBG (nmol/l)	$2.04 \pm 0.023$	$2.04 \pm 0.013$	90.000	0.654
FSH (ng/ml)	$0.047 \pm 0.004$	$0.046 \pm 0.002$	78.000	0.330
LH (ng/ml)	$0.067 \pm 0.02$	$0.066 \pm 0.002$	60.500	0.080

SHBG: Sex hormone binding globulin; FSH: Follicle-stimulating hormon; LH: Luteinizing hormone.

Results are expressed as mean  $\pm$  SD,

\* Statistically significant ( $p < 0.05$ ).

ne secretion, if any, should be mild, and it does not seem to induce overt hypogonadism. We also did not observe any change in the levels of LH and FSH in the treatment group in comparison to the controls. If the effect of pregabalin on testicular func-

tion was direct, we would expect an increase in levels of gonadotropins. These findings are consistent with a mild inhibitory influence of pregabalin on the hypothalamo-pituitary-gonad axis.

Levels of SHBG reflect the androgen effect. Its level decreases when there is androgenic effect, whereas lack of androgens or their effect lead to an increased level of SHBG. In the current study, we did not determine any significant difference in the levels of SHBG between the treatment and control groups. This is in accord with other findings suggesting that the negative effect of pregabalin on Leydig cell function is not dramatic.

Lack of significant change in sperm count and motility also suggests that the effect of pregabalin on testicular function is mild.

Seminiferous tubule epithelium thickness was increased and tubule diameters were decreased in the treatment group when compared with the control group. It is known that in conditions producing alterations in spermatogenesis, seminiferous tubule epithelium thickness may increase owing to the increase in the lamina propria. Thus, pathological findings may suggest altered spermatogenesis and a tendency toward testicular atrophy. This finding requires further analysis to elucidate whether connective tissue constituents of the basement membrane or the lamina propria cause the increase in the epithelium, suggesting atrophic changes in the testes.

In conclusion, we suggest that the Leydig cells, with a major function of secreting testosterone, are mildly affected by pregabalin. This effect seems to occur via inhibition of the hypothalamo-hypophyseal-gonadal axis rather than a direct effect on the testicles. Further studies are required to establish the effect, if any, of pregabalin on testicular tissue.

## REFERENCES

1. Isojärvi JI, Taubøll E, Herzog AG. Effect of antiepileptic drugs on reproductive endocrine function in individuals with epilepsy. *CNS Drugs* 2005;19(3):207-23.
2. Morrell MJ, Montouris GD. Reproductive disturbances in patients with epilepsy. *Cleve Clin J Med* 2004;71(Suppl 2):19-24.
3. Montouris G, Morris GL 3rd. Reproductive and sexual dysfunction in men with epilepsy. *Epilepsy Behav* 2005;7(Suppl 2):7-14.
4. Vartanian MG, Radulovic LL, Kinsora JJ, Serpa KA, Vergnes M, Bertram E, et al. Activity profile of pregabalin in rodent models of epilepsy and ataxia. *Epilepsy Res* 2006;68(3):189-205.
5. Hurley RW, Chatterjea D, Rose Feng M, Taylor CP, Hammond DL. Gabapentin and pregabalin can interact synergistically with naproxen to produce antihyperalgesia. *Anesthesiology* 2002;97(5):1263-73.
6. Partridge BJ, Chaplan SR, Sakamoto E, Yaksh TL. Characterization of the effects of gabapentin and 3-isobutyl-gamma-aminobutyric acid on substance P-induced thermal hyperalgesia. *Anesthesiology* 1998;88(1):196-205.
7. Field MJ, Oles RJ, Singh L. Pregabalin may represent a novel class of anxiolytic agents with a broad spectrum of activity. *Br J Pharmacol* 2001;132(1):1-4.
8. Pohl RB, Feltner DE, Fieve RR, Pande AC. Efficacy of pregabalin in the treatment of generalized anxiety disorder: double-blind, placebo-controlled comparison of BID versus TID dosing. *J Clin Psychopharmacol* 2005;25(2):151-8.
9. Feltner DE, Crockatt JG, Dubovsky SJ, Cohn CK, Shrivastava RK, Targum SD, et al. A randomized, double-blind, placebo-controlled, fixed-dose, multicenter study of pregabalin in patients with generalized anxiety disorder. *J Clin Psychopharmacol* 2003;23(3):240-9.
10. Prasad MR, Chinoy NJ, Kadam KM. Changes in succinic dehydrogenase levels in the rat epididymis under normal and altered physiological conditions. *Fertil Steril* 1972;23(3):186-90.
11. Sveberg Røste L, Taubøll E, Berner A, Berg KA, Aleksandersen M, Gjerstad L. Morphological changes in the testis after long-term valproate treatment in male Wistar rats. *Seizure* 2001;10(8):559-65.
12. McLachlan RI, Wreford NG, O'Donnell L, de Kretser DM, Robertson DM. The endocrine regulation of spermatogenesis: independent roles for testosterone and FSH. *J Endocrinol* 1996;148(1):1-9.
13. Connell JM, Rapeport WG, Beastall GH, Brodie MJ. Changes in circulating androgens during short term carbamazepine therapy. *Br J Clin Pharmacol* 1984;17(3):347-51.