

A Rare Cause of Dysphonia: Laryngeal Lipoma: Differential Diagnosis

Ses Kısıklığının Nadir Bir Nedeni: Laringeal Lipom

Cihan AKGÜL ÖZMEN, MD,^a
Hasan NAZAROĞLU, MD,^a
Müzeyyen YILDIRIM, MD,^b
Hatice ÖZTÜRKMEN AKAY, MD,^a
Aylin H. BAYRAK, MD^a

Department of ^aRadiology ^bEar-Nose-
Throat Diseases Dicle University
Faculty of Medicine, Diyarbakır

Geliş Tarihi/Received: 04.12.2008
Kabul Tarihi/Accepted: 06.04.2009

Yazışma Adresi/Correspondence:
Cihan AKGÜL ÖZMEN, MD
Dicle University Faculty of Medicine,
Department of Radiology, Diyarbakır,
TÜRKİYE/TURKEY
drcihanakgul@dicle.edu.tr

ABSTRACT Although lipomas are the most common benign tumors of mesenchymal origin, laryngeal lipomas are rare. We report a case of laryngeal lipoma with computed tomography (CT) and magnetic resonance imaging (MRI) findings. A mass filling the left pyriform sinus was detected on the examination of a 52-year-old man admitted with dysphonia. The mass was originated from lateral side of left aryepiglottic fold, extending to subglottic area on the neck CT and MRI scans. The radiologic findings were compatible with laryngeal lipoma. Laryngeal lipoma, although rare, should be kept in mind for the differential diagnosis of patients admitted with dysphonia.

Key Words: Lipoma; laryngeal neoplasms

ÖZET Lipomlar mezenseşimal kaynaklı en sık benign tümörler olmasına rağmen laringeal lipomlar nadirdir. Laringeal lipom olgusunu bilgisayarlı tomografi (BT) ve manyetik rezonans görüntüleme (MRG) bulguları ile sunduk. Ses kısıklığıyla başvuran 52 yaşında erkek hastanın muayenesinde sol piriform sinüsü dolduran kitle izlendi. Boyun BT ve MR incelemesinde kitlenin sol aryepiglottik fold lateralinden kaynaklandığı ve subglottik alana uzandığı izlendi. Radyolojik görünüm laringeal lipom ile uyumlu olarak değerlendirildi. Laringeal lipom nadir olmasına karşılık ses kısıklığı ile başvuran hastalarda ayırıcı tanıda akılda tutulmalıdır.

Anahtar Kelimeler: Lipom; larinks tümörleri

Türkiye Klinikleri J Med Sci 2009;29(6):1789-91

Lipomas are the most common benign tumors of mesenchymal origin.¹ About 13% of all lipomas occur in the head and neck and most commonly in the posterior neck.² Laryngeal lipomas represent less than 1% of benign tumors of the larynx with fewer than 100 reported cases in the literature up to date.¹⁻³ We reported a case of laryngeal lipoma with CT and MRI findings.

CASE REPORT

A 52-year-old man presented with dysphonia remitting and relapsing during the last 18 months. Dyspnea and cough have been added to the clinical picture a few weeks ago. On the larynx examination, a mass filling the left pyriform sinus was detected and left vocal cord was immobile. CT of the neck revealed that the mass involved the left aryepiglottic fold, filling the left pyriform sinus, coursing downward between paraglottic fat and lastly

extending to the subglottic area. In addition, the laryngeal air column was narrowed on CT. The 3.5x3x2.5 cm mass had fat attenuation (-98 Hounsfield units) (Figure 1). The lesion was hyperintense on T1 and T2 weighted images (Figure 2-4). The radiologic findings were compatible with laryngeal lipoma. Surgical excision of the mass was suggested, but the patient refused the surgical operation.

DISCUSSION

Lipomas occur predominantly in men, with a male to female ratio of 5 to 1 and develop most often in the sixth and seventh decades.⁴ About 13% of lipomas are located in the head and neck, most of

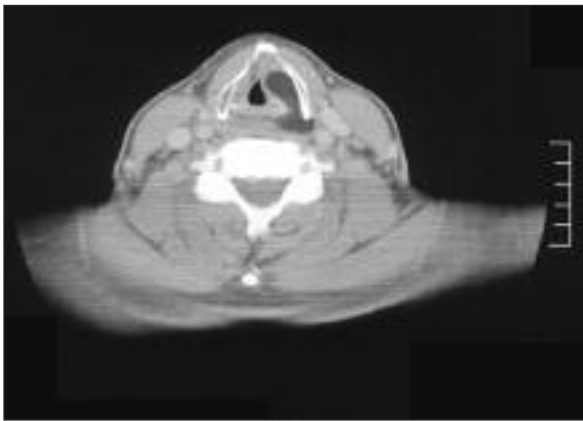


FIGURE 1: The lipoma extending from left vocal cord to posterior commissure is seen on axial CT image.

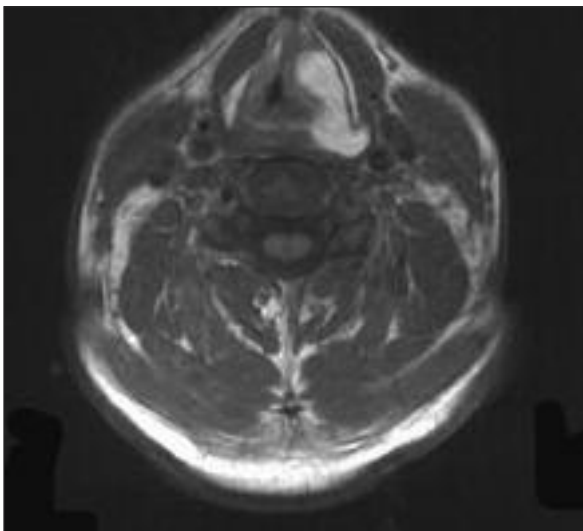


FIGURE 2: The hyperintense appearance secondary to the lipoma is seen on axial T1 weighted MR image obtained at the same level.

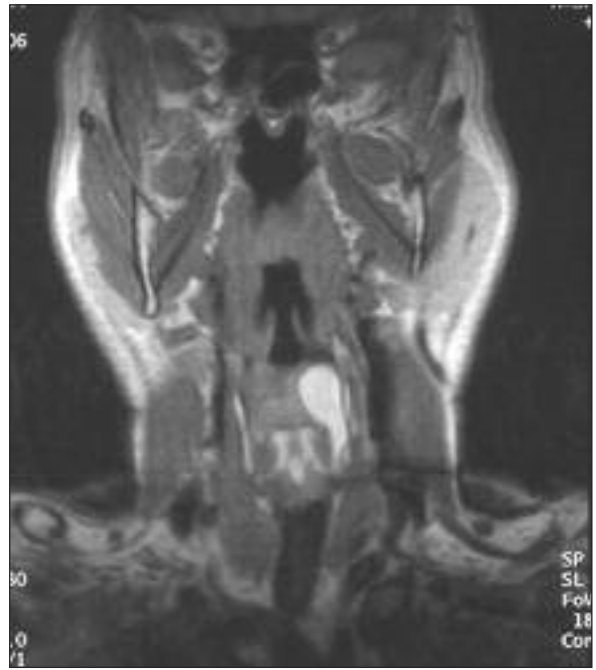

FIGURE 3: The subglottic extension of lipoma is demonstrated on coronal T1 weighted MR image.

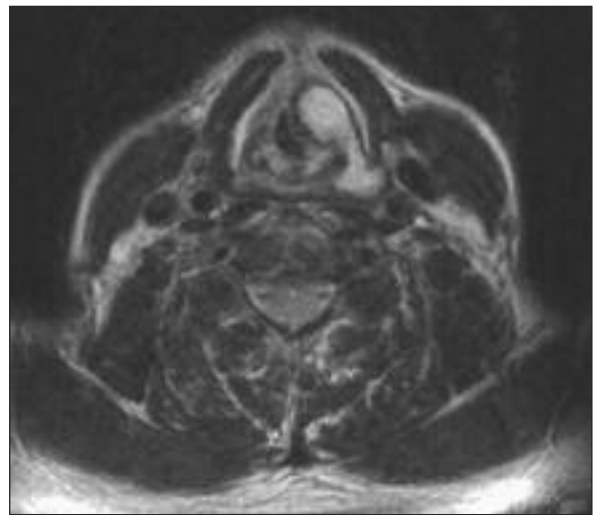


FIGURE 4: The lesion is also hyperintense on the axial T2 weighted MR image.

which are found in the posterior neck. Laryngeal lipomas may have extrinsic or intrinsic forms. The intrinsic form of laryngeal lipomas is rare; this occurs in regions where lipomatous tissues form a part of the subepithelial structures, such as in the false vocal cords, epiglottis, and aryepiglottic folds. The glottic manifestation was reported to be the

rarest form of the disease and was present in our case.⁵

Laryngeal lipomas may be pedunculated or submucosal.⁵ Pedunculated lipomas may cause airway obstruction. Submucosal lipomas deform the larynx and may cause partial airway obstruction and phonatory disturbance, which was the case in our patient, who most likely had a submucosal type lipoma causing partial airway obstruction. However, we could not definitely define the lesion as submucosal because no histological examination was done.

Lipomas tend to grow slowly, so that patients may not experience any major symptoms for a long time. Dyspnea is the most frequent complaint. Hoarseness is not as common.⁵ When clinical symptoms are present, the treatment of choice is total excision using conservative surgical removal, the extent of the procedure depending on the size and site of the tumor. The lipomatous mass should be removed completely because there is a chance of recurrence. The small ones may be excised by

endoscopic surgery, but open surgery is required for large masses.⁵

The CT appearance of a lipoma is that of a homogenous low attenuation mass that usually measures between -65 and -125 HU. The differential diagnosis includes benign tumors, such as neurofibroma, leiomyoma, chondroma, papilloma, cystic hygroma, and parenchymal cyst. However, none of these lesions has the attenuation values of lipoma. Although it is usually not difficult to differentiate lipoma from liposarcoma, it may be a challenge especially in case of well-differentiated liposarcomas.⁶ These tumors, may resemble lipomas on both CT scans and MR images but present internal septa that may be broader and more nodular than those seen in lipomas which was absent in our case.⁷

In conclusion, benign laryngeal tumors are rare and radiological imaging is important for the diagnosis and for the referral of the patient to surgery. Laryngeal lipoma, although rare, should be considered in the differential diagnosis of patients presenting with dysphonia.

REFERENCES

1. Yüksel Y, Erdem E, Gültekin SG. [Lipoma in the Cheek: Case report]. *Turkiye Klinikleri J Dental Sci* 2008;14(1):43-6.
2. Som PM, Scherl MP, Rao VM, Biller HF. Rare presentations of ordinary lipomas of the head and neck: a review. *AJNR Am J Neuroradiol* 1986;7(4):657-64.
3. El-Monem MH, Gaafar AH, Magdy EA. Lipomas of the head and neck: presentation variability and diagnostic work-up. *J Laryngol Otol* 2006;120(1):47-55.
4. Jones SR, Myers EN, Barnes L. Benign neoplasms of the larynx. *Otolaryngol Clin North Am* 1984;17(1):151-78.
5. Trizna Z, Forrai G, Toth B, Banhidly FG. Laryngeal lipoma. *Ear Nose Throat J* 1991;70(6):387-8.
6. Crim JR, Seeger LL, Yao L, Chandnani V, Eckardt JJ. Diagnosis of soft-tissue masses with MR imaging: can benign masses be differentiated from malignant ones? *Radiology* 1992;185(2):581-6.
7. Salvatore C, Antonio B, Del Vecchio W, Lanza A, Tartaro G, Giuseppe C. Giant infiltrating lipoma of the face: CT and MR imaging findings. *AJNR Am J Neuroradiol* 2003;24(2):283-6.