

Use of Two Different Classification Systems to Determine the Characteristics of Ectopic Eruption in the First Permanent Molars: A Retrospective Cross-Sectional Study

Daimi Birinci Molar Dişlerdeki Ektopik Erüpsiyon Özelliklerini Belirlemek İçin İki Farklı Sınıflandırma Sisteminin Kullanılması: Retrospektif Kesitsel Çalışma

 Deniz Sıla ÖZDEMİR^a,  Halenur ALTAN^b

^aDepartment of Pediatric Dentistry, Abant İzzet Baysal University Faculty of Dentistry, Bolu, Türkiye

^bDepartment of Pediatric Dentistry, Tokat Gaziosmanpaşa University, Faculty of Dentistry, Tokat, Türkiye

ABSTRACT Objective: The aim of this study is to determine the incidence of ectopic eruption in permanent first molar teeth retrospectively with 2 different classification methods, based on radiographic findings, during the transition from primary dentition to permanent dentition. **Material and Methods:** This study was conducted with children aged between 6-12 years admitted to pediatric dentistry department. The orthopantomographic radiographs of 2,516 patients were examined. The patients' age and gender, teeth with ectopic eruption and the jaw were recorded. In the classification of ectopic eruption, Young and Barberia-Leache et al.'s classification was used. Data were analyzed with IBM SPSS V23. Differences between teeth were examined with Cochran's Q test. The correlation between Barberia-Leache classification and Young's classification was evaluated with the chi-square test. Significance level was taken as $p < 0.05$. **Results:** A total of 2,516 patients were included in the study and ectopic eruption was seen in a total of 70 teeth in 47 (23 girls, 24 boys) patients. The prevalence of ectopic eruption was found to be 1.9%. Ectopic eruption of the permanent first molar tooth was seen more in the upper jaw than in the lower jaw. According to Young's classification, the prevalence of permanent first molar eruption in reversible type is higher, while the prevalence of Grade I permanent first molar ectopic eruption is higher according to Barberia-Leache et al.'s classification. **Conclusion:** Even in cases of ectopic eruption in permanent first molars that are considered severe according to Barberia-Leache et al. classification and Young's classification, spontaneous recovery can be observed with long-term follow-up.

ÖZET Giriş: Bu çalışmada amacımız; süt dişlenme döneminden daimi dişlenme dönemine geçişte, daimi 1. molar dişlerde ektopik erüpsiyon görülme sıklığını radyografik bulgulara dayanarak, 2 farklı sınıflandırma yöntemi ile retrospektif olarak belirlemektir. **Gereç ve Yöntemler:** Bu çalışma, çocuk diş hekimliği ana bilim dalına başvuran 6-12 yaş arası çocuklarla yapıldı. İki bin beş yüz on altı hastanın ortopantomografik radyografileri incelendi. Hastaların yaş ve cinsiyeti, ektopik erüpsiyon görülen dişleri ve çenesi kaydedildi. Ektopik erüpsiyon sınıflandırmasında Young ve Barberia-Leache ile ark.nın sınıflandırması kullanıldı. Veriler IBM SPSS V23 ile analiz edildi. Dişler arasındaki farklılıklar Cochran Q testi ile incelendi. Barberia-Leache sınıflaması ile Young sınıflaması arasındaki korelasyon ki-kare testi ile değerlendirildi. Anlamlılık düzeyi $p < 0,05$ olarak alındı. **Bulgular:** İki bin beş yüz on hasta çalışmaya dâhil edildi ve 47 (23 kız, 24 erkek) hastada toplam 70 dişte ektopik erüpsiyon görüldü. Ektopik erüpsiyon prevalansı %1,9 olarak bulundu. Daimi 1. molar dişin ektopik erüpsiyonu alt çeneye göre üst çenede daha fazla görüldü. Young sınıflamasına göre reversible tipte ektopik erüpsiyon görülen daimi 1. molar prevalansı daha fazlayken, Barberia-Leache ve ark.nın sınıflamasına göre Derece I daimi 1. molar ektopik erüpsiyon prevalansı daha fazladır. **Sonuç:** Çalışmamızda, Barberia-Leache sınıflandırmasına göre Derece I'den III'e doğru gidildikçe reversible olma eğilimi artmıştır. Daimi 1. molar dişlerde Barberia-Leache ve ark.nın sınıflamasına ve Young sınıflandırmasına göre şiddetli kabul edilen ektopik erüpsiyon vakalarında dahi uzun dönem takiple kendiliğinden düzelme görülebilir.

Keywords: Ectopic tooth eruption; prevalence; early diagnosis; mixed dentition

Anahtar Kelimeler: Ektopik diş erüpsiyonu; prevalans; erken teşhis; karışık dişlenme

Correspondence: Deniz Sıla ÖZDEMİR

Department of Pediatric Dentistry, Abant İzzet Baysal University Faculty of Dentistry, Bolu, Türkiye

E-mail: denizsilaozdemir@gmail.com



Peer review under responsibility of Türkiye Klinikleri Journal of Dental Sciences.

Received: 25 Oct 2021

Received in revised form: 15 Mar 2022

Accepted: 04 Apr 2022

Available online: 11 Apr 2022

2146-8966 / Copyright © 2022 by Türkiye Klinikleri. This is an open access article under the CC BY-NC-ND license (<http://creativecommons.org/licenses/by-nc-nd/4.0/>).

Ectopic eruption (EE) is the malposition of a permanent tooth that affects the primary teeth and causes premature loss of permanent teeth due to the lack of growth in the jaw or jaw segment.¹ The EE of maxillary first permanent molars (FPM) has a prevalence ranging from 0.75%-6%.²⁻⁵ The cause of EE in the maxillary FPM is not known exactly. But it is considered to have a multifactorial etiology.³ EE of molars may result from developmental disorders (EE, impaction, or ankylosis), pathological causes, or iatrogenic causes (displacement during extraction).^{2,3,6} FPM with EE may be asymptomatic and overlooked by clinicians.

A comprehensive clinical examination is required to diagnose the EE of the FPM. In children aged 7 years and older, the ectopic position of the FPM is determined on the radiograph by the superposed and compressed image of the primary second molar (PSM) with the distal root. Intraoral view, the delay in the eruption of unilateral or bilateral maxillary FPM, and the eruption of distal tubercles of these teeth before mesial tubercles should suggest the EE of these teeth.⁷

In general, FPM with EE are impacted below the distal roots of PSM.⁸ If they are not treated in time, they may lead to premature root resorption of PSM, pulp obliteration, neuralgic pain, or premature exfoliation, which may lead to premature loss of primary teeth, reduced arch length, and delayed eruption of permanent teeth.⁹ The determination of the incidence and severity of EE will help clinicians in predicting the need for treatment (as a predictor).

Our aim in this study was to retrospectively determine the incidence of EE in FPM during the transition from primary dentition to permanent dentition, based on radiographic findings and using 2 different classification methods.

MATERIAL AND METHOD

STUDY MODEL

The protocol of this study was approved by Tokat Gaziosmanpaşa University Clinical Research Ethics Committee (date: August 29, 2021, no: /18-KAEK-181). The study was conducted in accordance with

the principles of the Declaration of Helsinki. Informed consent form was not obtained since it was a retrospective study. Children aged 6-12 years were selected for the study. Considering the possible losses in the sample size determined by reference to the Barberia-Leache et al. studies according to the below formula, 50% reserve was added and the sample size was determined as 2869.³

$$n = \frac{(z^2) P (1-P)}{d^2} = 'z^2=1.96, p=0.02, d=0.05'$$

n=sample size,

Z=Z statistic for the level of confidence,

P=expected prevalence and,

D=allowable error.

FPM were examined by 2 different researchers (pediatric dentists) in orthopantomographic radiographs of 2,869 patients. Three hundred fifty three patients who did not meet the appropriate conditions were excluded from the study and 2,516 patients were included in the study (Figure 1). The patient's age and gender, teeth with EE, and the jaw with it were recorded.

PANORAMIC IMAGING

No extra radiographs were taken from the patients for this study, and the existing digital panoramic radiographs were used. The radiographs taken with the same dental panoramic device (Soredex, TUUSULA, Finlandiya) were included in the study.

EVALUATION OF RADIOGRAPHS

Two different classifications were used in the evaluation of FPM with EE. With the Young classification, EE of the FPM was classified in 2 forms: reversible (spontaneous recovery) and irreversible (called "skip" and "hold").¹⁰ Based on the classification of EE of the FPM defined by Barberia-Leache et al., the EE's observed in the FPM were classified into 4 categories.³

Grade I: Mild-Limited resorption of the cement or minimal dentin penetration

Grade II: Moderate-Resorption of dentin without pulp exposure

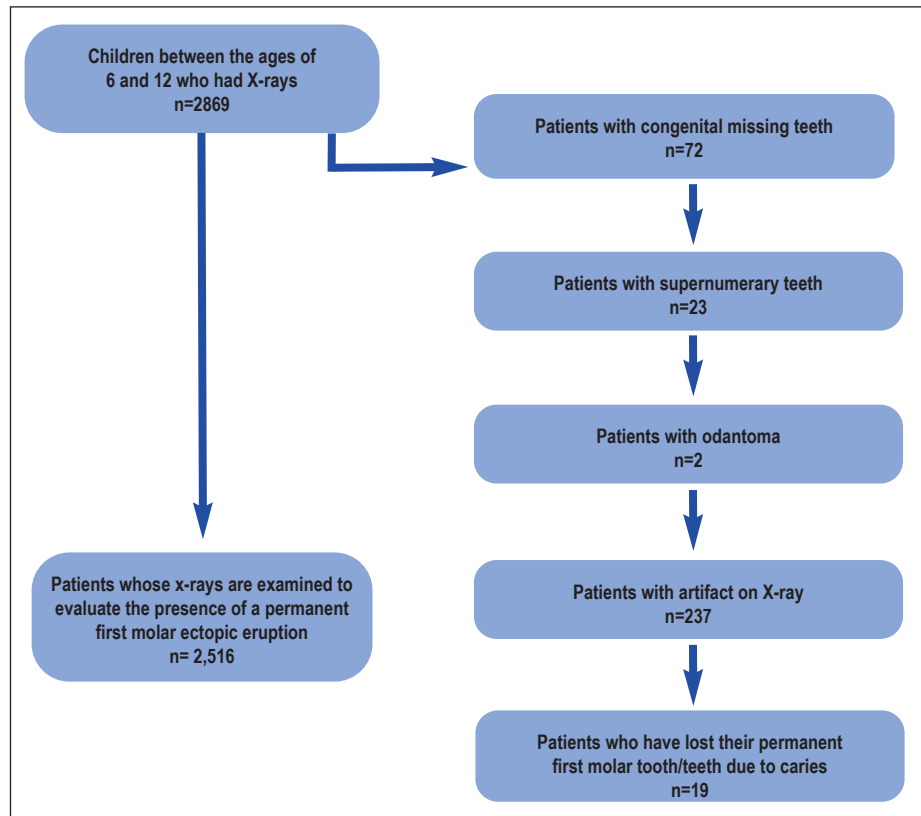


FIGURE 1: Flowchart of excluded patients.

Grade III: Severe-Distal root resorption causing pulp exposure

Grade IV: Very severe-Resorption affecting the mesial root of the PSM (Figure 1).

STATISTICAL METHOD

The data were analyzed using the SPSS software (version 23, IBM Corporation, Armonk, NY, USA). Whether there was a difference between the teeth was examined using the Cochran's Q test. The correlation between Barberia-Leache classification and Young classification was evaluated by the chi-square test. The level of significance was considered as $p < 0.05$. The inter-rater reliability coefficient of the study was 0.820. In this case, the data were found to be "Highly Reliable" since they were in the range of $0.60 \leq \alpha \leq 0.90$.

RESULTS

EE was observed in 47 (23 girls, 24 boys) patients of 2,516 patients included in the study, and the prevalence was found to be 1.9%. A total of 70 ectopic

teeth were found in 47 patients, including 1 ectopic tooth in 26 patients, 2 ectopic teeth in 19 patients, and 3 ectopic teeth in 2 patients. Among 47 ectopic patients, it was determined that the ratio of those with unilateral upper jaw was 51.1%, the ratio of bilateral upper jaw was 36.2%, the ratio of unilateral lower jaw was 4.3%, the ratio of bilateral lower jaw was 2.1%, and both lower and upper jaw ratio was 6.4%. According to the Barberia-Leache classification, it was determined that while 42.6% of the patients were Grade I, 21.3% of them were Grade II, 27.7% of them were Grade III and 8.5% of them were Grade IV. According to the Young classification, the rate of reversible ones was 53.2% (Table 1). It was determined that the mean age of 2,516 patients included in the study was 8.95 and the mean age of patients with EE was 7.53.

The incidence of EE was 1.1% in tooth 16, 1.4% in tooth 26, 0.1% in tooth 36, and 0.2% in tooth 46. When these ratios were examined, it was determined that there was no statistical difference between teeth

TABLE 1: Descriptive statistics.		
	n	%
Gender		
Female	1,210	48.1
Male	1,306	51.9
Ectopic		
No	2,469	98.1
Yes	47	1.9
Jaw		
Unilateral upper jaw	24	51.1
Bilateral upper jaw	17	36.2
Unilateral lower jaw	2	4.3
Bilateral lower jaw	1	2.1
Both lower and upper jaw	3	6.4
Barberia-Leache classification		
Grade I	20	42.6
Grade II	10	21.3
Grade III	13	27.7
Grade IV	4	8.5
Young classification		
Reversible	25	53.2
Irreversible	22	46.8

16 and 26, and similarly, there was no statistical difference between teeth 36 and 46. There was a difference between the 16-26 tooth group and the 36-46 tooth group ($p < 0.001$). EE of the FPM was more common in the upper jaw compared to the lower jaw (Table 2). There was a significant correlation between Young classification and the classification of Barberia-Leache et al. ($p = 0.016$). In the Barberia-Leache classification, while 30% of those with Grade I were reversible, this rate was 50% in Grade II, 84.6% in Grade III and 75% in Grade IV. There was a statistically significant difference between the rate obtained in Grade I and the rate obtained in Grade III. The rates of Grade 2 and Grade IV did not differ from the others (Table 3).

DISCUSSION

While Chen et al. reported that only 9.29% of patients with EE of the FPM were diagnosed, Mooney et al. reported that 35.7% of them were diagnosed.^{2,11} This reveals the importance of treatment and early diagnosis of FPM with EE. In our study, the EE of the

FPM was examined cross-sectionally and retrospectively by examining panoramic radiographs and then categorized with 2 different classifications. In the classification made by Barberia-Leache et al. with regard to prognosis, they reported that 69.4% of the patients tended to be irreversible; however, the FPM was irreversibly locked in place in 30.6%.³ In our study, reversible and irreversible cases were found to be 53.2% and 46.8%, respectively. These results are similar to those of Young.¹⁰

It has been reported that the different prevalence of EE among populations may be associated with variables such as ethnicity, geography, patient age, and gender.^{8,12} There are 2 different studies on this subject in Türkiye. Güven found that the prevalence of EE was 2.65%, however, Caliskan et al. found it to be 0.83%.^{13,14} In our study, similar to the literature, the prevalence of EE was found to be 1.9%, and no difference was found in the prevalence of EE between boys and girls.^{3,13,15,16}

An EE of the FPM is more common in the maxilla than in the mandible.^{10,14,17} The higher prevalence in the maxilla is associated with the absence of bone growth in the tuber region at the appropriate time for tooth eruption and the posterior position of the maxilla relative to the cranial base.¹⁴ A higher rate of EE was observed in the maxilla than in the mandible in the Turkish population. No significant difference was found between the left and right regions of the jaws.

TABLE 2: Descriptive statistics.			
	n	%	p ¹ value
Tooth no 16			
No	2,489	98.9	
Yes	27	1.1	
Tooth no 26			
No	2,480	98.6	
Yes	36	1.4	<0.001
Tooth no 36			
No	2,513	99.9	
Yes	3	0.1	
Tooth no 46			
No	2,512	99.8	
Yes	4	0.2	

¹Cochran's Q.

TABLE 3: Correlation between the Barberia-Leache classification and the young classification.

	Barberia-Leache Classification				p ¹ value
	Grade I	Grade II	Grade III	Grade IV	
Young classification					
Reversible	6 (30) ^a	5 (50) ^{ab}	11 (84.6) ^b	3 (75) ^{ab}	0.016
Irreversible	14 (70)	5 (50)	2 (15.4)	1 (25)	

^{a,b}There is no difference between Barberia-Leache classifications with the same letter on each line; ¹Chi-square; n (%).

There are differences in the literature regarding the bilateral or unilateral prevalence of EE.^{3,8,18,19} Mendoza et al. reported that EE was bilateral by 67.6% and unilateral by 32.4%.¹⁹ Sun et al. reported that the incidence of EE was bilateral by 42.6% and unilateral by 57.4%.¹⁸ In this study, similar to the study of Sun et al., a unilateral EE was more common by 55.4%.¹⁸

Barberia-Leache et al. reported that although there was resorption at the distal root of the PSM in Grades I and II, reversible improvement could be seen without any treatment.³ However, most of the Grade III and IV cases would remain irreversible without spontaneous improvement, although they indicated that there was no statistically significant correlation in this regard and that there were some reversible Grade III cases and irreversible Grade I cases. In our study, it was observed that the tendency to be reversible increased from Grades I to III, according to the Barberia-Leache classification.

When EE is detected at an early age, a case diagnosed as irreversible because jaw development is not yet at a sufficient level may become reversible with the development of the jaw and an increase in the arch length at a later age.

The limitation of this study is that the transition from irreversible to reversible ectopic FPM of the irreversible type by gaining a place in the arc with growth and development was not followed. Similarly, we considered that the fact that the tendency to be reversible increased from Grades I to III was related to the age at which the EE was diagnosed. If these patients were the patients under follow-up, time-depen-

dent (reversible-irreversible; Grades I, II, III, and IV) changes in the eruption types of the FPM with EE could be seen more clearly.

CONCLUSION

In our study, the tendency to be reversible increased from Grade I to III according to the Barberia-Leache classification. Even in cases of EE of the FPM, which are considered severe according to Barberia-Leache et al.'s classification and Young's classification, spontaneous recovery can be observed with long-term follow-up.

Source of Finance

During this study, no financial or spiritual support was received neither from any pharmaceutical company that has a direct connection with the research subject, nor from a company that provides or produces medical instruments and materials which may negatively affect the evaluation process of this study.

Conflict of Interest

No conflicts of interest between the authors and / or family members of the scientific and medical committee members or members of the potential conflicts of interest, counseling, expertise, working conditions, share holding and similar situations in any firm.

Authorship Contributions

Idea/Concept: Halenur Altan; **Design:** Hale Nur Altan, Deniz Sila Özdemir; **Control/Supervision:** Deniz Sila Özdemir; **Data Collection and/or Processing:** Deniz Sila Özdemir; **Analysis and/or Interpretation:** Hale Nur Altan, Deniz Sila Özdemir; **Literature Review:** Deniz Sila Özdemir; **Writing the Article:** Deniz Sila Özdemir; **Critical Review:** Hale Nur Altan, Deniz Sila Özdemir; **References and Fundings:** Hale Nur Altan, Deniz Sila Özdemir; **Materials:** Hale Nur Altan, Deniz Sila Özdemir.

REFERENCES

- Özdemir DS, Altan H. Ectopic eruption of permanent first molar teeth. *Yeditepe Dent J.* 2021;17(1):69-75. [[Crossref](#)]
- Chen X, Huo Y, Peng Y, Zhang Q, Zou J. Ectopic eruption of the first permanent molar: Predictive factors for irreversible outcome. *Am J Orthod Dentofacial Orthop.* 2021;159(2):e169-77. [[Crossref](#)] [[PubMed](#)]
- Barberia-Leache E, Suarez-Clúa MC, Saavedra-Ontiveros D. Ectopic eruption of the maxillary first permanent molar: characteristics and occurrence in growing children. *Angle Orthod.* 2005;75(4):610-5. [[PubMed](#)]
- Kupietzky A, Soxman JA. Ectopic eruption of maxillary first permanent molar. In: Soxman JA, et al. *Handbook of Clinical Techniques in Pediatric Dentistry.* 1st ed. Ames, Iowa: John Wiley & Sons, Inc; 2015. p.107-19. [[Crossref](#)]
- Kim WS, Kim Y, Cho JH, Oh H, Hwang HS. Unlocking ectopically erupting permanent first molars using light wires. *J Am Dent Assoc.* 2020;151(11):857-62. [[Crossref](#)] [[PubMed](#)]
- Wong YK, Liew JC, Tsui SH, Cheng JC. Ectopic molar near the coronoid process: case report. *Quintessence Int.* 2007;38(7):597-600. [[PubMed](#)]
- Rah Y, Lee J, Ra J. Association between ectopic eruption of the maxillary first permanent molar and skeletal malocclusion. *J Korean Acad Pediatr Dent.* 2017;44(2):147-53. [[Crossref](#)]
- Mucedero M, Rozzi M, Cardoni G, Ricchiuti MR, Cozza P. Dentoskeletal features in individuals with ectopic eruption of the permanent maxillary first molar. *Korean J Orthod.* 2015;45(4):190-7. [[Crossref](#)] [[PubMed](#)] [[PMC](#)]
- Yaseen SM, Naik S, Uloopi K. Ectopic eruption - A review and case report. *Contemp Clin Dent.* 2011;2(1):3. [[Crossref](#)] [[PubMed](#)] [[PMC](#)]
- Young DH. Ectopic eruption of the first permanent molar. *J Dent Child.* 1957;24:153-62.
- Mooney GC, Morgan AG, Rodd HD, North S. Ectopic eruption of first permanent molars: presenting features and associations. *Eur Arch Paediatr Dent.* 2007;8(3):153-7. [[Crossref](#)] [[PubMed](#)]
- Hsiao CC, Boynton JR. Etiology, Classification and management of ectopic eruption of permanent first molars. *J Mich Dent Assoc.* 2016;98(1):26-30. [[PubMed](#)]
- Güven Y. Prevalence of ectopic eruption of first permanent molars in a Turkish population. *Eur Oral Res.* 2018;52(1):1-5. [[Crossref](#)] [[PubMed](#)] [[PMC](#)]
- Caliskan S, Tuloglu N, Ozdemir C, Kizilaslan S, Bayrak S. Ectopic eruption of maxillary permanent first molars: Predictive factors for self-corrected and impacted outcome. *Int J Clin Pract.* 2021;75(3):e13880. [[Crossref](#)] [[PubMed](#)]
- Bondemark L, Tsiopa J. Prevalence of ectopic eruption, impaction, retention and agenesis of the permanent second molar. *Angle Orthod.* 2007;77(5):773-8. [[Crossref](#)] [[PubMed](#)]
- Salbach A, Schremmer B, Grabowski R, Stahl de Castrillon F. Correlation between the frequency of eruption disorders for first permanent molars and the occurrence of malocclusions in early mixed dentition. *J Orofac Orthop.* 2012;73(4):298-306. [[Crossref](#)] [[PubMed](#)]
- Hennessy J, Al-Awadhi EA, Dwyer LO, Leith R. Treatment of ectopic first permanent molar teeth. *Dent Update.* 2012 Nov;39(9):656-8, 660-1. [[Crossref](#)] [[PubMed](#)]
- Sun J, Nam O, Kim M, Lee H, Choi S. Predictive Factors of Ectopic Eruption of the Maxillary First Permanent Molar. *J Korean Acad Pediatr Dent.* 2016;43(3):284-91. [[Crossref](#)]
- Mendoza-Mendoza A, Villalon-Rivero G, González-Mallea E, Caleza-Jiménez C, Solan-Mendoza B, Ya-ez-Vico R, et al. Ectopic eruption of the permanent maxillary first molar: Study in a population of 505 South European children. *Edorium J Dent.* 2014;1:7-11. [[Crossref](#)]