

# An Unusual Presentation of Diffuse Lung Disease: Neurofibromatosis-Associated Diffuse Lung Disease: Case Report

## Diffüz Akciğer Hastalığının Alışılmadık Bir Sunumu: Nörofibromatozis-İlişkili Diffüz Akciğer Hastalığı

Fatma ÇİFTÇİ,<sup>a</sup>  
Cem ÇOMUNOĞLU,<sup>b</sup>  
Amber EKER,<sup>c</sup>  
Finn RASMUSSEN<sup>d</sup>

<sup>a</sup>Department of Thoracic Diseases,  
Ankara University Faculty of Medicine,  
Ankara

Departments of  
<sup>b</sup>Medical Pathology,

<sup>c</sup>Neurology,

<sup>d</sup>Thoracic Diseases,  
Near East University Faculty of Medicine,  
Lefkosa, TRNC

*This case report was presented as a thematic poster at 15<sup>th</sup> Annual Thorax Congress in 11-15 April 2012, Antalya.*

Geliş Tarihi/Received: 07.08.2012

Kabul Tarihi/Accepted: 19.11.2012

Yazışma Adresi/Correspondence:

Fatma ÇİFTÇİ

Ankara University Faculty of Medicine,  
Department of Thoracic Diseases, Ankara,  
TÜRKİYE/TURKEY

fatmarslann@yahoo.com

**ABSTRACT** Neurofibromatosis type 1 (NF1), formerly known von Recklinghausen's disease, is a common autosomal dominant neurocutaneous syndrome linked to a gene on the long arm of chromosome 17, which encodes a protein known as neurofibrin, a negative regulator of Ras oncogene. NF1 occurs in one of every 2000 live births. NF1 is characterised by a number of distinct clinical features which are usually present at birth and may undergo malignant transformation. It is not among diseases frequently associated with diffuse parenchymal lung disease. We report a case of a middle-aged female, who was referred to chest disease department with a complaint of cough and unexpectedly diagnosed as NF1 with associated diffuse lung disease.

**Key Words:** Lung diseases, interstitial; neurofibromatosis 1; pulmonary emphysema

**ÖZET** Nörofibromatozis tip 1 (NF1), daha önceden bilinen adıyla von Recklinghausen's hastalığı, sık görülen otozomal dominant geçişli, kromozom 17'nin uzun kolunda yerleşerek nörofibrin olarak bilinen bir proteini kodlayan ve Ras onkogenin negatif düzenleyicisi olan bu gen ilişkili bir nörookutanöz sendromdur. NF1 her 2000 canlı doğumda bir görülür. NF 1 genellikle doğumdan itibaren birçok farklı klinik bulguyla ortaya çıkar ve malign transformasyon görülebilir. Diffüz parankimal akciğer hastalıklarıyla ilişkili olarak sık tanımlanan bir hastalık değildir. Bu yazıda, göğüs hastalıkları departmanına öksürük şikayeti nedeniyle gönderilen ve beklenmedik şekilde NF1 ilişkili diffüz akciğer hastalığı tanısı konulan bir orta yaşlı kadın olguyu sunuyoruz.

**Anahtar Kelimeler:** Akciğer hastalıkları, interstisyel; nörofibromatozis 1; pulmoner amfizem

**Türkiye Klinikleri Arch Lung 2013;14(1):26-30**

**N**eurofibromatosis (NF) type I, known also as von Recklinghausen's disease is a relatively common familial disorder. It is an autosomal condition affecting the ectoderm and mesoderm characterized by neurofibromas, cutaneous lesions, and benign peripheral nerve tumors of Schwann cells and fibroblasts that develop in adolescence.<sup>1</sup> Neurofibromas typically arise from peripheral or intercostal nerves and appear as well-margined posterior mediastinal masses in the paravertebral region.<sup>2</sup> They may be associated with posterior vertebral scalloping with enlargement of the neural foramen, scoliosis, and rib dysplasia.<sup>3</sup> An apical intercostal neurofibroma may simulate a Pancoast's tumor on chest radiography. Direct involvement of the lungs or pleura is uncommon.<sup>4</sup> Sporadic cases of NF1 with diffuse lung disease have been published in case reports, but the overall

prevalence and clinical characteristics of lung involvement remain unclear.<sup>5</sup> The pulmonary manifestations of NF1 consist of diffuse interstitial fibrosis, ground-glass opacities, reticular opacities, bullae, cysts, emphysema, and honeycombing.<sup>6</sup> Respiratory symptoms are usually mild.

## CASE REPORT

We present a case of a 40 years old caucasian female patient who was referred to our clinic due to dry cough for 2 years. Her past medical history was unremarkable. She was a former smoker and had 10 package/year smoking history. Her chest X-ray revealed bilateral diffuse reticular infiltrations (Figure 1). High resolution computed tomography demonstrated bilateral thin walled air cysts with upper lobe predominance, bibasilar reticular opacities, interlobular septal thickening, and ground-glass opacities (Figure 2). Pulmonary function tests revealed normal spirometry (FVC: 94%, FEV<sub>1</sub>: 93%, FEV<sub>1</sub>/FVC: 86%), very slightly decreased lung volumes (TLC: 65% RV: 8%) and diffusion capacity (DLCO: 72%, DLCO/VA: 74%). Transcutaneous oxygen saturation was 97% at room air. Six minute walking distance was normal with a walking distance of 423 meters and with no desaturation. All blood tests including antinuclear antibodies, c- and p- antineutrophilic cytoplasmic antibodies, immunoglobulin levels and serum complement analysis were unremarkable. Cutaneous examination found multiple hyperpigmented macular rashes

(cafe-au-lait spots) and multiple soft, pedunculated neurofibromas on patient's back, trunk, and axillary regions (Figure 3). Ophthalmologic biomicroscopic examination showed pigmented hamartomas in the iris (Lish nodules). Axillary freckling was also seen (Figure 4). Kyphoscoliosis was diagnosed on her chest X-ray. A clinical diagnosis of neurofibromatosis had made on the basis of these multiple cafe-au-lait spots and neurofibromas.

Cranial MRI showed a hyperintensity lesion in right cerebellar hemisphere (Figure 5). Learning disability with cognitive function impairment was observed.

The patient underwent fiberoptic bronchoscopy which showed normal mucosa in the whole tracheobronchial tree. Bronchoalveolar lavage (BAL) was performed from the middle lobe medial segment. BAL fluid differential cell counts revealed 88% macrophages, 11% lymphocytes, 5% neutrophils, 1% eosinophils with  $17 \times 10^6$  total cell counts. Five punch biopsies, the greatest measuring 0.4x0.3x0.2 cm and the smallest measuring 0.1x0.1x0.1 cm, were sent to pathology laboratory. Histopathological evaluation revealed mild emphysematous alterations (Figure 6) and mild fibrosis (Figure 7). Immunohistochemical staining with S-100 was found negative.

Periodic neurologic and respiratory follow-up as well as stopping smoking were advised. Her only sibling, a 15-year-old female child, was also

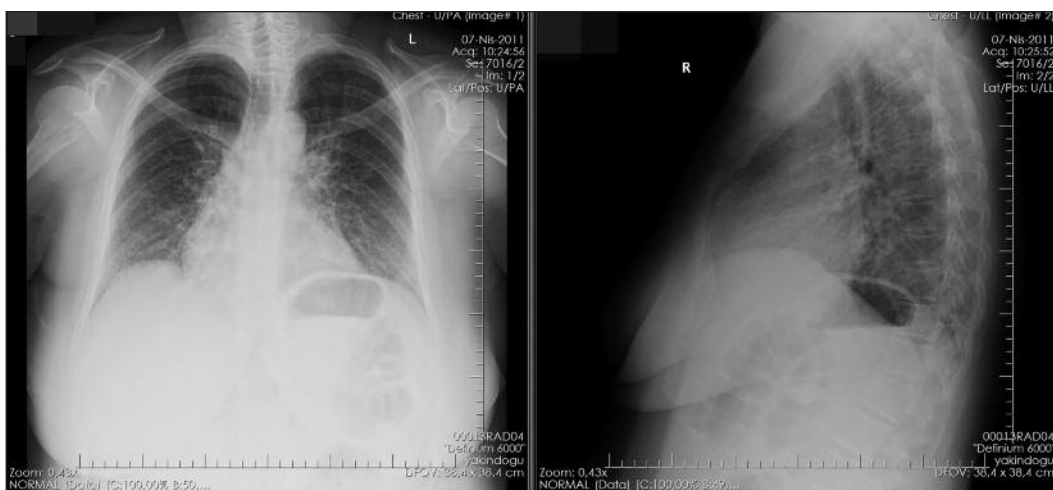


FIGURE 1: Chest X-ray revealed bilateral diffuse reticular infiltrations.

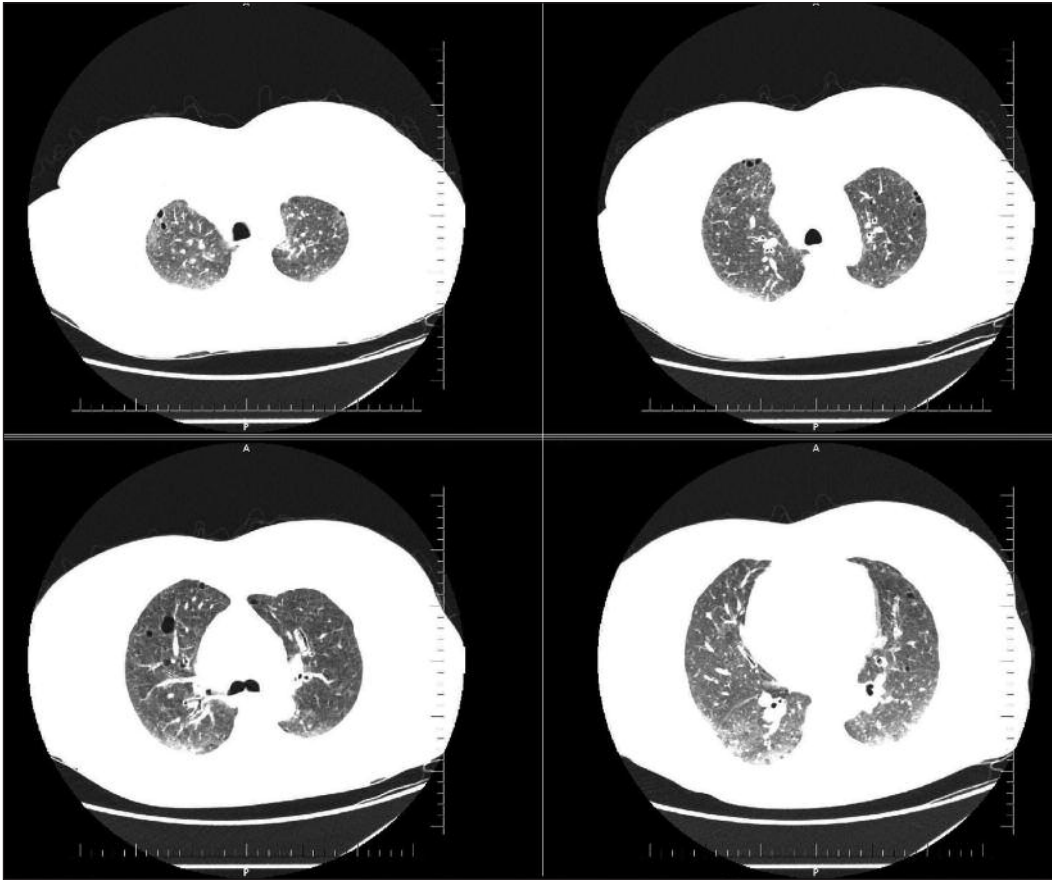


FIGURE 2: HRCT scan demonstrated bilateral thin walled air cysts with upper lobe predominancy.

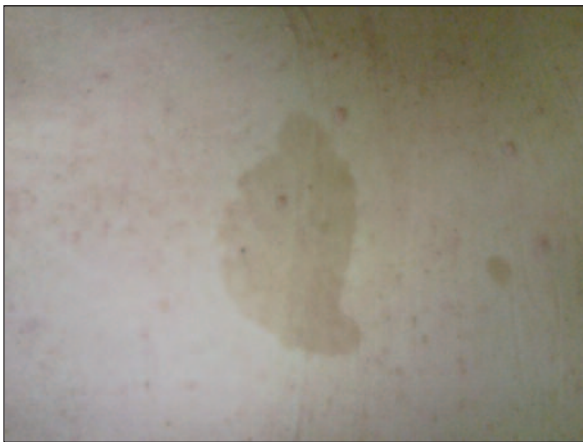

FIGURE 3: Multiple cafe-au-lait macules and neurofibromas on the patients back. (See for colored form <http://akcigerarsivi.turkiyeklinikleri.com/>)

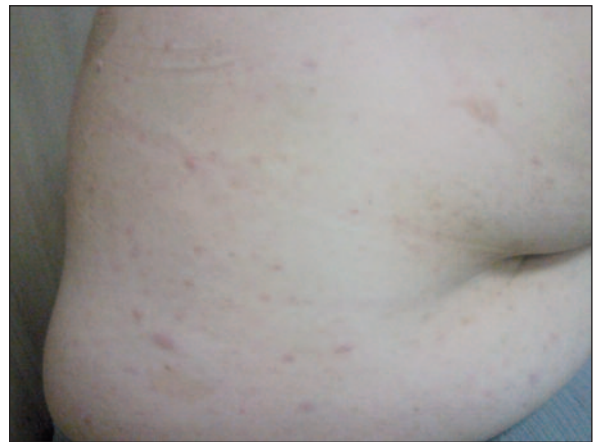

FIGURE 4: Axillary freckling. (See for colored form <http://akcigerarsivi.turkiyeklinikleri.com/>)

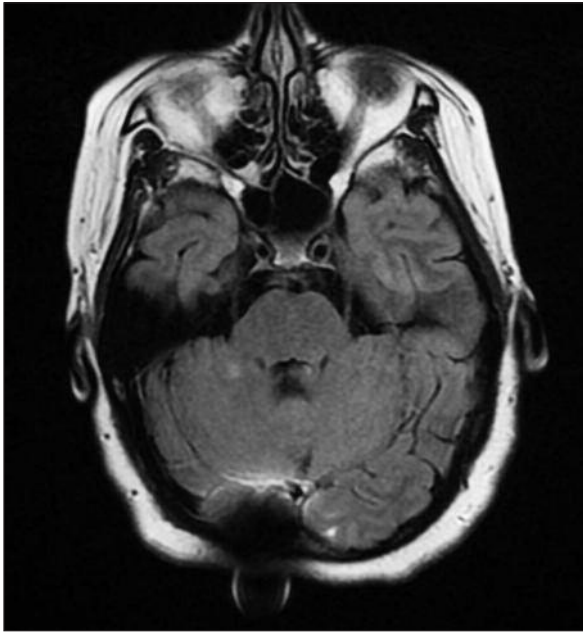
screened for NF-1, who was found to have NF-1 but no pulmonary disease.

## DISCUSSION

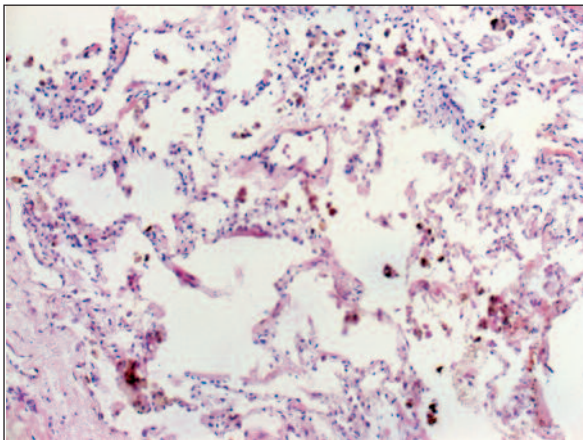
Neurofibromatosis type 1 exhibits extreme clinical variability in terms of its features of occurrence and

severity.<sup>7</sup> NF1 is mostly diagnosed in early ages with specific clinical features. The diagnosis is usually based on physical examination. The presented case is an example of late diagnosis of the disease.<sup>8</sup> Although transmitted as an autosomal dominant trait, there is no clear family history of this disease

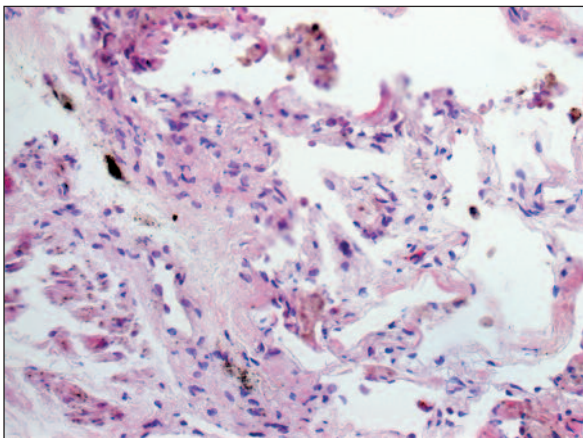




**FIGURE 5:** Cranial MRI showed a hyperintensity lesion in right cerebellar hemisphere.



**FIGURE 6:** Mild emphysematous alterations (x200, H-E).  
(See for colored form <http://akcigerarsivi.turkiyeklinikleri.com/>)



**FIGURE 7:** Mild fibrosis (x400, H-E).  
(See for colored form <http://akcigerarsivi.turkiyeklinikleri.com/>)

in approximately half of the patients. These sporadic cases probably arise from a new mutation in the germ cell of one of the parents, most commonly the father.<sup>9</sup>

NF-associated diffuse lung disease (NF-DLD) was first described nearly sixty years ago.<sup>10</sup> Since 1963, some reports have described this association with different interstitial involvements.<sup>11-13</sup> Conventional radiographic studies of NF1 patients using conventional chest radiography commonly report large apical asymmetric thin-walled bullae (73%), sometimes occupying a substantial portion of hemithorax and associated with areas of hypovascularity and bibasilar, subpleural reticular abnormality (61%).<sup>14</sup> Data regarding HRCT appearance in NF-DLD, is provide mainly from a large series complied by Zamora et al. who reviewed 64 NF-DLD. HRCT finding were ground-glass opacities (50%), bullae (50%), cysts (25%), and emphysema (25%). The studies concluded that neurofibromatosis with diffuse lung disease is a definable clinical entity, characterised by upper lobe cystic and bullous disease and lower lobe fibrosis.<sup>15,16</sup> Honeycombing mimicking idiopathic pulmonary fibrosis is rare but has been described.<sup>6</sup> Dyspnea, cough and chest pain are the most common symptoms when lung is involved.<sup>9</sup> Our patient presented with cough. There were distinct pulmonary characteristics in accordance with NF such as slightly decreased diffusion capacity and total lung capacity in addition to HRCT and biopsy findings in our patient. Although none of them are specific for NF they altogether suggest a pulmonary involvement of NF in this patient. Pulmonary function tests may demonstrate either an obstructive, restrictive or normal patterns.<sup>12,14</sup> A decreased diffusion capacity is almost always present and may be the first pulmonary function test to become abnormal.<sup>10</sup> It has been suggested that NF may increase the sensitivity of lungs to cigarette smoke, causing early development of emphysema-like changes.<sup>17</sup> This suggests smoking may actually be a risk factor for the development and severity of NF-DLD or NF1 itself may increase the sensitivity to smoking, though it has not been proved.<sup>18</sup> Several observations, however, suggest that NF-DLD is a

distinct clinical entity. First, non-smokers with NF have also pulmonary involvement. In accordance with this Zamora et al. found that there were no statistically significant differences in pulmonary function pattern or radiographic abnormalities between smokers and non-smokers.<sup>6</sup> Secondly, the radiologic appearance of HRCT of NF-DLD is atypical for a smoking-related disease; the borders of cysts and bullae are thicker and more sharply defined than smoking-related emphysema. The occurrence of NF-DLD in non-smokers, the presence of cysts different than smoking-related emphysema on HRCT, and histopathological pattern of NSIP all support that the cystic lung disease is a distinct manifestation of NF.<sup>19</sup>

The pathogenesis of lung fibrosis in NF was studied in some reports. Fabricant and Todaro found increased nerve growth factor in the serum of patients with NF. This factor directly activates fibroblasts, stimulating differentiation into more pro-fibrogenic myofibroblasts, a process which may contribute to lung fibrosis.<sup>20</sup> Motoyama et al. reported that nerve growth factor has protease activity and may contribute to the pathogenesis of emphysema in patients with NF1.<sup>21</sup>

## CONCLUSION

In patients with diffuse lung disease with lung cysts NF should be considered in differential diagnosis.

## REFERENCES

1. Ütine GE. [RASopathies: neuro-cardio-facio-cutaneous syndromes]. *Turkiye Klinikleri J Pediatr Sci* 2011;7(2):92-8.
2. Kaymak Y, Yüksel N, Karabulut AN, Ekşioğlu M. [Neurofibromatosis: a case report]. *Turkiye Klinikleri J Med Sci* 2004;24(6):702-6.
3. Fortman BJ, Kuszyk BS, Urban BA, Fishman EK. Neurofibromatosis type 1: a diagnostic mimicker at CT. *Radiographics* 2001;21(3):601-12.
4. Kang J, Litmanovich D, Bankier AA, Boiselle PM, Eisenberg RL. Manifestations of systemic diseases on thoracic imaging. *Curr Probl Diagn Radiol* 2010;39(6):247-61.
5. Szudek J, Birch P, Riccardi VM, Evans DG, Friedman JM. Associations of clinical features in neurofibromatosis 1 (NF1). *Genet Epidemiol* 2000;19(4):429-39.
6. Zamora AC, Collard HR, Wolters PJ, Webb WR, King TE. Neurofibromatosis-associated lung disease: a case series and literature review. *Eur Respir J* 2007;29(1):210-4.
7. Riccardi VM. Von Recklinghausen neurofibromatosis. *N Engl J Med* 1981;305(27):1617-27.
8. Dirican A, Yılmaz M, Ünal B, Ateş M, Kırımlioğlu H, Yılmaz S. Diffuse cecal ganglioneuromatosis in a patient with von Recklinghausen's disease: Case report *Turkiye Klinikleri J Med Sci* 2012;32(4):1105-8.
9. Bunin GR, Needle M, Riccardi VM. Paternal age and sporadic neurofibromatosis 1: a case-control study and consideration of the methodologic issues. *Genet Epidemiol* 1997;14(5):507-16.
10. Davies PDB. Diffuse pulmonary involvement in Von Recklinghausen's disease: a new syndrome. *Thorax* 1963; 18(2): 198-200.
11. Massaro D, Katz S, Matthews MJ, Higgins G. Von Recklinghausen's neurofibromatosis associated with cystic lung disease. *Am J Med* 1965;38:233-40.
12. Massaro D, Katz S. Fibrosing alveolitis: its occurrence, roentgenographic, and pathologic features in von Recklinghausen's neurofibromatosis. *Am Rev Respir Dis* 1966;93(6):934-42.
13. Burkhalter JL, Morano JJ, McCay MB. Diffuse interstitial lung disease in neurofibromatosis. *South Med J* 1986;79(8):944-6.
14. Hardcastle SW, Hendricks ML. Neurofibromatosis (von Recklinghausen's disease)--an unusual cause of parenchymal lung disease. A case report. *S Afr Med J* 1984;66(25):959-60.
15. Shino MY, Rabbani S, Belperio JA, Lynch JP 3rd, Weigt SS. Neurofibromatosis-associated diffuse lung disease: case report. *Semin Respir Crit Care Med* 2012;33(5):572-5.
16. Webb WR, Goodman PC. Fibrosing alveolitis in patients with neurofibromatosis. *Radiology* 1977;122(2):289-93.
17. Patchefsky AS, Atkinson WG, Hoch WS, Gordon G, Lipshitz HI. Interstitial pulmonary fibrosis and von Recklinghausen's disease. An ultrastructural and immunofluorescent study. *Chest* 1973;64(4):459-64.
18. Ryu JH, Parambil JG, McGrann PS, Aughenbaugh GL. Lack of evidence for an association between neurofibromatosis and pulmonary fibrosis. *Chest* 2005;128(4):2381-6.
19. Yokoyama A, Kohno N, Sakai K, Kondo K, Hirasawa Y, Hiwada K. Distal acinar emphysema and interstitial pneumonia in a patient with von Recklinghausen's disease: five-year observation following quitting smoking. *Intern Med* 1997;36(6):413-6.
20. Fabricant RN, Todaro GJ. Increased serum levels of nerve growth factor in von Recklinghausen's disease. *Arch Neurol* 1981;38(7):401-5.
21. Motoyama N, Ayashi T, Yano A. A case of von Recklinghausen's disease with progressive bullous emphysema. *Kokyu* 1987;35(19):1260.