

Multidisciplinary Treatment of Multiple Traumatized Anterior Teeth: 2 Year Follow-Up: Case Report

Çoklu Travmatize Anterior Dişlerin Multidisipliner Tedavisi: 2 Yıllık Takip

Nur BALCI,^a
Nurcan ALTAŞ,^a
Erhan ERKAN,^b
Hilal USLU TOYGAR^a

^aDepartment of Periodontology,
İstanbul Medipol University
School of Dentistry,

^bDepartment of Endodontics,
İstanbul Medipol University
Medipol Mega Hospital,
İstanbul

Geliş Tarihi/Received: 04.04.2016
Kabul Tarihi/Accepted: 11.07.2016

Yazışma Adresi/Correspondence:

Nur BALCI
İstanbul Medipol University
School of Dentistry,
Department of Periodontology, İstanbul,
TÜRKİYE/TURKEY
nbalci@medipol.edu.tr

ABSTRACT Traumatic injuries are common problem that may affect person's quality of life. Correct diagnosis and treatment procedures have an important role for the prognosis of traumatized teeth. This paper describes the multidisciplinary approach to a case of a 30-year-old male patient who exhibited laceration of labial mucosa and frenulum and horizontal root fracture and luxation of maxillary incisors. Periodontal and endodontic treatments of injured teeth and soft tissues were applied for the treatment strategy. The maintenance of anterior traumatized teeth was supplied without endodontic treatment although they had root fractures. At the 2 year follow up, clinical and radiographic evaluation revealed satisfactory functional and esthetic results.

Key Words: Tooth fractures; traumatology

ÖZET Travmatik yaralanmalar yaşam kalitesini etkileyebilen yaygın bir problemdir. Doğru tanı ve tedavi uygulamaları travmatize dişlerin prognozunda önemli bir rol oynamaktadır. Bu vaka raporu maksiller anterior dişlerinde horizontal kök kırığı ve luksasyon ve labial mukozasında laserasyonu bulunan 30 yaşında bir erkek hastaya multidisipliner yaklaşımı tanımlamaktadır. Tedavi stratejisi dahilinde, travmaya uğrayan dişler ve yumuşak dokuya periodontal ve endodontik tedavi uygulanmıştır. Kök kırığı bulunan anterior dişlerin sağlığı endodontik tedavi yapılmaksızın idame ettirilmiştir. 2 yıllık klinik ve radyolojik takip sonuçları hem fonksiyonel hem de estetik olarak tatmin edicidir.

Anahtar Kelimeler: Diş kırıkları; travmatoloji

Türkiye Klinikleri J Dental Sci Cases 2016;2(2):88-92

Dentoalveolar traumas are important public health problems that occur as common results of falls, sports, violence, and traffic accidents.^{1,2} In the permanent dentition, the most severe dental injury affects supporting tissues such as gingiva and underlying alveolar bone and causes esthetic, psychological, social, and functional disturbances.³ Current literatures emphasis that dental trauma are experienced by males more than females.⁴ The maxillary central incisors are the most frequently injured teeth for both the primary and permanent dentitions and root fracture is one of the results of traumatized permanent incisors.⁵⁻⁶ Root fracture healing shows various patterns which may be desirable such as no healing, healing with interposition of hard and soft tissue between the fragments, or,

doi: 10.5336/dentalcase.2016-51644

Copyright © 2016 by Türkiye Klinikleri

undesirable like the outgrowth of granulation tissue caused by infected or necrotic pulp.⁷

There are two types of root fracture: vertical and horizontal. Horizontal root fracture is perpendicular to the long axis of the tooth's root.⁸ Although horizontal root fracture is rarely seen (0.2–7%), it is difficult to manage because of the complex structure of the damage of combined dental tissues such as pulp, dentin, cementum.⁹ Pulp necrosis may occur (22%) as a result of horizontal root fracture, and the frequency of pulp necrosis following root fractures is higher in mature teeth than in teeth with open apices.¹⁰

Different treatment modalities for management of horizontal root fractures have been reported in the literature.^{2,5,8} The indications for treatment strategy mainly depends on the extent of fracture, pulp involvement, radicular fracture, biologic width infringement or violation, and presence of the fractured piece.¹¹

In case of spontaneous pain, endodontic treatment is indicated whereas a splinting may be necessary to reposition and stabilize the fractured fragments to provide periodontal and/ or pulp healing.¹² The adequate relief from occlusal loading is also essential for successful management of root fractures and successful management of root fractures often involves a multidisciplinary combination of endodontic, orthodontic, periodontal and prosthetic treatments.¹³ In conclusion, management of traumatic dental injuries should focus on the elimination or attenuation of the injury to avoid further complications and usually requires a multidisciplinary approach for correct diagnosis and effective treatment with a long term follow-up procedures.

Treatment of root fractures requires a multidisciplinary approach, which could be time consuming to achieve desired results. This case report presents the management of traumatized maxillary central incisors with horizontal fracture lines and emphasizes the importance of multidisciplinary approach involving periodontal and endodontic treatments for the management of dental traumatic injuries.

CASE REPORT

A 30-year-old male patient referred to Istanbul Medipol University, Faculty of Dentistry immediately after the dental trauma as a result of a fall accident with a complaint of pain and luxation of maxillary incisors. The clinical and radiological examinations showed a horizontal root fracture in maxillary right and left first incisors while a complicated crown fracture in maxillary right and left second incisors. Tooth mobility was recorded according to the Miller's mobility index.¹⁴ Class 3 mobility was observed in maxillary right and left first incisors whereas maxillary right and left second incisors showed class 2 mobility. In addition, maxillary right and left first incisors were vital while maxillary right and left second incisors were non-vital according to vitality test. All maxillary central and lateral incisors were tender to percussion. Additionally, laceration was observed on labial mucosa and frenulum and there was no damage to the adjacent alveolar bone (Figure 1a-c).

Under local anesthesia, laceration wound on lip and frenulum were debrided and sutured with 5-0 silk suture material and then traumatized teeth were splinted by using composite resin with orthodontic wire to provide periodontal healing and stabilize the teeth. Root canal treatments achieved with gutta-percha points and AH Plus sealer (Dentsply, DeTrey, Konstanz, Germany) for maxillary right and left second incisors and coronal restorations were achieved with 3M Filtek Ultimate composite resin filler (3M Espe, St. Paul, MN, USA). Premature contacts were removed by occlusal adjustment. 0.12% chlorhexidine solution and soft diet were recommended for 1 week after the patient was treated periodontally and instructed about oral hygiene methods. Splint was removed after 4 weeks and no antibiotic coverage was administered during a healing period.

The patient was recalled to reassess both dental and supporting tissue reassessment protocol followed with revisions at 3-6 months, a year and annual reviews for 2 years. Followed reassessment

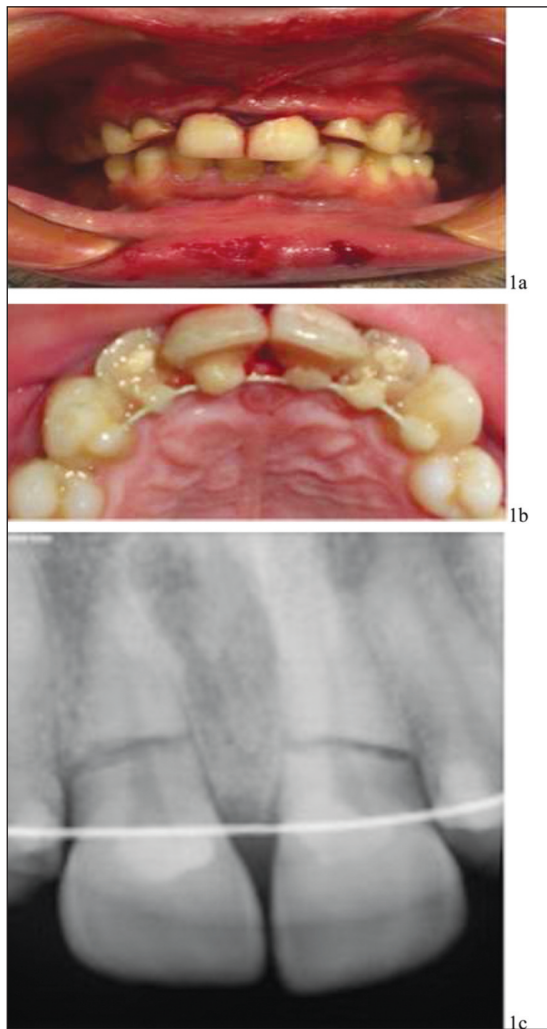


FIGURE 1: The initial radiological and clinical view **a)** Full-mouth view **b)** Temporary composite resin splint **c)** Initial periapical radiograph.

examinations revealed that composite restorations were excellent covering the fracture lines and there was no gingival recession, attachment loss and periodontal pocket formation (Figure 2).

All teeth were negative percussion responses. Radiographic examination of periapical X-rays revealed normal and unremarkable bone tissue surrounding teeth and there was calcified tissue healing at the fracture line (Figure 3). Additionally, all teeth exhibited Miller class 1 mobility. At 2 years follow up, there was an external root resorption for maxillary right first incisor and it remained its vitality as well as maxillary left first incisor. Satisfactory functional and esthetic treatment results were observed (Figure 4).

DISCUSSION

Dentoalveolar trauma involving treatment remains a challenge for professionals and rarely seen in multiple teeth.¹⁵ Dental traumas have many complications including, root, alveolar and jaw fractures, pulp necrosis, pulp canal obliteration, progressive root resorption, loss of supporting bone and tooth loss.¹⁶ This case report describes the management of dental trauma involving the complicated and uncomplicated root fractures and laceration of lip and labial frenulum.

The least type of horizontal root fractures is seen in the coronal part where as the most is in the middle third of the root (57%).¹⁷ The first step in the treatment of horizontal root-fracture cases is accurate diagnosis. Following the diagnosis with clinical and radiographical examinations, conservative treatment of teeth is repositioning, immobilization and relief of the occlusion.^{18,19} If the coronal fragment is nonvital or pathological symptoms develop during the follow-up period, endodontic treatment should be performed through the apical end of the coronal fragment.²⁰ Further dental treatment may involve intraradicular splinting and related restorative treatment. Various approaches for the treatment of horizontal root fractures are performed due to the vitality of the tooth and pulp vitality is seen in 60-80% of horizontal root fractures in dental trauma cases. The main reason of the tooth vitality could be explained by vascular relationship between pulp cells and periodontal tissues in this present case.

It is important to split the tooth as early as possible when horizontally fracture edges are in closed position for the ideal healing with a vital pulp. In this case, the patient referred to our clinic immediately after the accident and the segments were not displaced. Therefore, healing with vital pulp and also calcified tissue was expected. Consistent with previous reports, radiographic observation demonstrated no periapical radiolucency indicating that apical fragment may have retained its vitality during 2 years.^{21,22} Although there was some resorption on tooth 11 with the evidence of cementum covered root fracture surface with the pe-

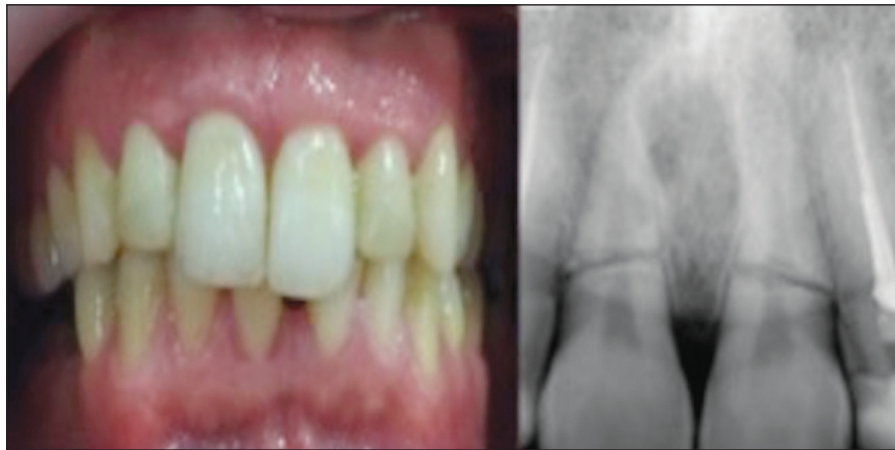

FIGURE 2: 6-month follow-up clinical and radiological views. Periapical radiograph revealed the normal periodontal ligament spaces and there was no radiolucent lesion in apical area of the injured maxillary right and left first incisors without any canal treatment.

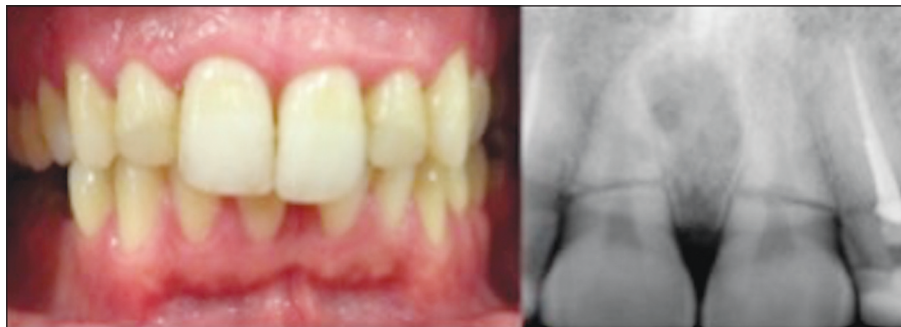

FIGURE 3: 1-year follow-up clinical and radiological views.

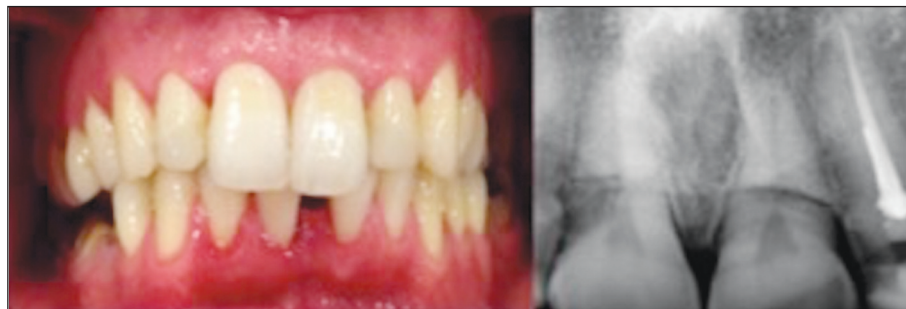

FIGURE 4: Clinical and radiological aspect showing the normal function of maxillary right and left first incisors after 2 years.

riodontal ligament healing. These radiological findings suggest that root fracture healed with interposition of hard and soft tissue between the fragments which is known as one of the root fracture healing patterns.

The stabilization of injured teeth using splints is the best practice to support the tooth right position and to promote healing of tooth supporting tis-

ues such as alveolar bone, periodontal ligament and pulp tissue.¹ The best splint made from orthodontic wire and resin composite that has the advantage of the lower risks of complications such as root resorption, and pulp obliteration and is generally available in dental offices, was passively performed in this present case to stabilize injured teeth.^{23,24}

Many literatures have been more based on evidence and mentioned on treatment guidelines of the repair of teeth.^{25,26} For example, Mazzoleni et al. (2010) reported that splints for shorter periods are more effective while the mechanical stimulus exerted by the light movement of the teeth favors the revascularization process. Accordingly, the ideal splint period for periodontal ligament treatment, as in this present case, should be 2-4 weeks to support the tooth right position and protect the teeth from traumatic forces during healing process. After an adequate repositioning and splinting was performed, single visit root canal treatment was performed and coronal restoration was performed by composite filling to avoid of tooth tissue loss and

consequently calcified tissue healing was observed according to radiological evaluation.²⁷

In this context, it should be kept in mind that horizontal root fracture following trauma should not be considered as an indication for extraction. Detailed diagnosis, systematic treatment plan, and appropriate treatment procedures are very important for the long-term success of dental traumas. Thus maintaining the health of injured dental tissues and enhancing patients' comfort both in esthetic and function. In conclusion, it is important that clinicians should be aware of multidisciplinary management of traumatic dental injuries and inform patients about all possible and long-lasting consequences of different dental injuries.

REFERENCES

- Honório HM, de Alencar CR, Pereira Júnior ES, de Oliveira GC, Rios D. Posttraumatic displacement management: lateral luxation and alveolar bone fracture in young permanent teeth with 5 years of follow-up. *Case Rep Dent* 2015;2015:634237.
- American Academy of Pediatric Dentistry Council on Clinical Affairs. Guideline on management of acute dental trauma. *Pediatr Dent* 2005-2006;27(7 Suppl):135-42.
- Pedriani D, Panzarini SR, Poi WR, Sundefeld ML, Tiveron AR. Dentists' level of knowledge of the treatment plans for periodontal ligament injuries after dentoalveolar trauma. *Braz Oral Res* 2011;25(4):307-13.
- Bastone EB, Freer TJ, McNamara JR. Epidemiology of dental trauma: a review of the literature. *Aust Dent J* 2000;45(1):2-9.
- Yousef MK. Reattachment of fractured teeth fragments in mandibular incisors: a case report. *Int Med Case Rep J* 2015;8:87-91.
- Malmgren B, Hübel S. Transient discoloration of the coronal fragment in intra-alveolar root fractures. *Dent Traumatol* 2012;28(3):200-4.
- Andreasen JO, Hjorting-Hansen E. Intraalveolar root fractures: radiographic and histologic study of 50 cases. *J Oral Surg* 1967;25(5):414-26.
- Aguiar CM, Mendes Dde A, Camara AC. Horizontal root fracture in a maxillary central incisor: a case report. *Gen Dent* 2013;61(2):12-4.
- Jacobsen I. Root fractures in permanent anterior teeth with incomplete root formation. *Scand J Dent Res* 1976;84(4):210-7.
- Andreasen JO, Andreasen FM, Mejgård I, Cvek M. Healing of 400 intra-alveolar root fractures. 2. Effect of treatment factors such as treatment delay, repositioning, splinting type and period and antibiotics. *Dent Traumatol* 2004;20(4):203-11.
- Reis A, Loguercio AD, Kraul A, Matson E. Reattachment of fractured teeth: a review of literature regarding techniques and materials. *Oper Dent* 2004;29(2):226-33.
- Kocak S, Cinar S, Kocak MM, Kayaoglu G. Intra-radicular splinting with endodontic instrument of horizontal root fracture--case report. *Dent Traumatol* 2008;24(5):578-80.
- Polat-Ozsoy O, Gülsahi K, Veziroğlu F. Treatment of horizontal root-fractured maxillary incisors--a case report. *Dent Traumatol* 2008;24(6):e91-5.
- Hanamura H, Houston F, Rylander H, Carlsson GE, Haraldson T, Nyman S. Periodontal status and bruxism. A comparative study of patients with periodontal disease and occlusal parafunctions. *J Periodontol* 1987;58(3):173-6.
- Koyuturk AE, Kusgoz A. Multiple dentoalveolar traumatic injury: a case report (3 years follow up). *Dent Traumatol*. 2008;24(4):e16-9.
- Andreasen JO. Etiology and pathogenesis of traumatic dental injuries. A clinical study of 1,289 cases. *Scand J Dent Res* 1970;78(4):329-42.
- Aras MH, Ozcan E, Zorba YO, Aslan M. Treatment of traumatized maxillary permanent lateral and central incisors horizontal root fractures. *Indian J Dent Res* 2008;19(4):354-6.
- Çalişkan MK, Pehlivan Y. Prognosis of root-fractured permanent incisors. *Endod Dent Traumatol* 1996;12(3):129-36.
- Ozbek M, Serper A, Calt S. Repair of untreated horizontal root fracture: a case report. *Dent Traumatol* 2003;19(5):296-7.
- Pan CS, Walker RT. Root fractures: a case of dental non-intervention. *Endod Dent Traumatol* 1988;4(4):186-8.
- Celikten B, Uzuntas CF, Safaralizadeh R, Demirel G, Sevimay S. Multidisciplinary approach for the treatment of horizontal root-fractured maxillary anterior teeth. *Case Rep Dent* 2014;2014:472759.
- Clarkson RM, John K, Moule AJ. Horizontal palatal root fracture in a vital upper first premolar. *J Endod* 2015;41(5):759-61.
- De Rossi M, De Rossi A, Queiroz AM, Nelson Filho P. Management of a complex dentoalveolar trauma: a case report. *Braz Dent J* 2009;20(3):259-62.
- Kahabuka FK, Willemsen W, van't Hof M, Ntabaye MK, Burgersdijk R, Frankenmolen F, et al. Initial treatment of traumatic dental injuries by dental practitioners. *Endod Dent Traumatol* 1998;14(5):206-9.
- Berthold C, Auer FJ, Potapov S, Petschelt A. Rigidity evaluation of quartz-fiber splints compared with wire-composite splints. *Dent Traumatol* 2012;28(1):65-74.
- Andreasen JO, Lauridsen E, Daugaard-Jensen J. Dental traumatology: an orphan in pediatric dentistry? *Pediatr Dent* 2009;31(2):133-6.
- Andreasen FM, Andreasen JO. Diagnosis of luxation injuries: the importance of standardized clinical, radiographic and photographic techniques in clinical investigation. *Endod Dent Traumatol* 1985;(5):160-9.