

CASE REPORT OLGU SUNUMU

DOI: 10.5336/pediatr.2025-110707

A Rare Case of Hereditary Sensory and Autonomic Neuropathy Type 4 in a 3-Year-Old: Clinical and Genetic Findings

Üç Yaşındaki Bir Çocukta Nadir Görülen Herediter Sensörial ve Otonom Nöropati Tip 4 Vakası: Klinik ve Genetik Bulgular

Arife Derda YÜCEL ŞEN^a, Havva Özüm KOLSUZ^b, Oğuz ÇİLİNGİR^c, Kürşat Bora ÇARMAN^a,
Coşkun YARAR^a

^aEskişehir Osmangazi University Faculty of Medicine, Department of Child Health and Diseases,
Department of Pediatric Neurology, Eskişehir, Türkiye

^bEskişehir Osmangazi University Faculty of Medicine, Department of Child Health and Diseases, Eskişehir, Türkiye

^cOsmangazi University Faculty of Medicine, Department of Medical Genetics, Eskişehir, Türkiye

ABSTRACT Hereditary sensory and autonomic neuropathy (HSAN) is a diverse collection of illnesses that impact sensory and autonomic neurons. HSAN Type 4 (HSAN-4), or congenital insensitivity to pain with anhidrosis (CIPA), is an uncommon autosomal recessive disorder marked by the lack of pain perception, self-injurious behaviour, and anhidrosis, resulting in repeated febrile episodes. Here, we report a case of a 3-year-old Afghan-born male with chronic non-healing wounds and recurrent febrile episodes due to anhidrosis. Genetic testing confirmed a homozygous mutation in the neurotrophic tyrosine kinase receptor-1 gene, supporting the diagnosis of HSAN-4. This case underscores the importance of early genetic diagnosis, highlights key clinical and therapeutic challenges in managing HSAN-4, and emphasizes the need for multidisciplinary approaches to improve patient outcomes.

Keywords: Hereditary sensory and autonomic neuropathy; congenital insensitivity to pain with anhidrosis; child

ÖZET Kalıtsal sensöriyel ve otonom nöropati [hereditary sensory and autonomic neuropathy (HSAN)], sensöriyel ve otonom nöronları etkileyen heterojen bir hastalık grubudur. HSAN Tip 4 (HSAN-4) veya doğuştan ağrıya duyarlılık ve anhidrozis [congenital insensitivity to pain with anhidrosis (CIPA)], ağrı algısının yokluğu, kendine zarar verme davranışları ve anhidroz ile karakterize nadir görülen otozomal resesif bir hastalıktır ve tekrarlayan febril ataklara yol açar. Bu çalışmada, kronik iyileşmeyen yaralar ve anhidroza bağlı tekrarlayan febril ataklar nedeniyle değerlendirilen, Afganistan doğumlu 3 yaşındaki erkek bir olgu sunulmaktadır. Genetik inceleme, nörotrofik tirozin kinaz reseptörü-1 geninde homozigot mutasyon olduğunu doğrulamış ve HSAN-4 tanısını desteklemiştir. Bu olgu, erken genetik tanının önemini vurgulamakta, HSAN-4 yönetiminde karşılaşılan klinik ve terapötik zorluklara dikkat çekmekte ve hasta sonuçlarını iyileştirmek için multidisipliner yaklaşımların gerekliliğini ortaya koymaktadır.

Anahtar Kelimeler: Kalıtsal sensöriyel ve otonom nöropati; doğuştan ağrı duyarlılığı ve anhidrozis; çocuk

Hereditary sensory and autonomic neuropathies (HSAN) include a category of neurodegenerative illnesses that impact the peripheral nervous system.¹ These illnesses differ according to the engagement of sensory and autonomic nerves and their hereditary

foundations. HSAN Type 4 (HSAN-4) is an autosomal recessive condition resulting from mutations in the neurotrophic tyrosine kinase receptor-1 (NTRK1) gene, which encodes the tyrosine kinase receptor-A TrkA receptor critical for neuronal survival mediated

TO CITE THIS ARTICLE:

Yücel Şen AD, Kolsuz HÖ, Çilingir O, Çarman KB, Yazar C. A rare case of hereditary sensory and autonomic neuropathy Type 4 in a 3-year-old: Clinical and genetic findings. Türkiye Klinikleri J Pediatr. 2025;34(2):72-6.

Correspondence: Arife Derda YÜCEL ŞEN

Eskişehir Osmangazi University Faculty of Medicine, Department of Child Health and Diseases, Department of Pediatric Neurology, Eskişehir, Türkiye

E-mail: derdayucel@hotmail.com



Peer review under responsibility of Türkiye Klinikleri Journal of Pediatrics.

Received: 25 Mar 2025

Received in revised form: 05 May 2025

Accepted: 05 May 2025

Available online: 28 May 2025

2146-8990 / Copyright © 2025 by Türkiye Klinikleri. This is an open access article under the CC BY-NC-ND license (<http://creativecommons.org/licenses/by-nc-nd/4.0/>).

by nerve growth factor (NGF).² The condition presents in early life with a lack of pain perception, repeated fever episodes caused by anhidrosis, and self-injurious behaviors, significantly affecting the fingers and lips. We present a case of HSAN-4 in a 3-year-old child, emphasizing the diagnostic and clinical aspects.

CASE REPORT

A 3-year-old male patient of Afghan descent presented to our pediatric neurology outpatient clinic with complaints of recurrent fever episodes since 3 months of age and chronic non-healing wounds that began at 8 months of age. The child was born to consanguineous parents. His medical history included self-biting behaviour, absence of pain sensation, and complete lack of sweating. On physical examination, the patient appeared cachectic, with a body weight-for-height ratio of 60%; his weight was 10.5 kg (<5th percentile), height was 95 cm (50th-75th percentile),

and head circumference was 49 cm (25th-50th percentile). The calculated body mass index was 11.64 kg/m², indicating undernutrition. The patient's neuromotor development was consistent with his chronological age, and no cognitive or intellectual delays were noted during follow-up evaluations. A dermatological examination revealed thickened and dry skin on the palms. Oral examination showed gingival atrophy, extensive dental caries, and loss of papillae on the tongue (Figure 1). Multiple self-inflicted injuries were noted, including distal phalanx loss in the right 2nd and 3rd fingers, ulceration on the left knee, and nail bed injuries (Figure 2, Figure 3). Mongolian spot-like lesions were observed on the back (Figure 4). Neurological examination revealed normal muscle tone, strength, and deep tendon reflexes, ruling out motor neuropathy. A skeletal survey showed no skeletal dysplasias; however, the left big toe noted a lytic lesion suggestive of osteomyelitis (Figure 5). Whole exome sequencing analysis revealed a pathogenic homozygous NM_002529.3:c.1077C>G (p.Tyr359Ter) nonsense variant in NTRK1 gene, resulting in a premature stop codon and establishing the diagnosis of HSAN Type 4. Prophylactic antibiotic therapy was initiated to prevent the progression of osteomyelitis. The diagnosis was established based on clinical findings and genetic confirmation, guiding the treatment approach. Following the diagnosis, a multidisciplinary rehabilitation plan was implemented. The patient was referred to pediatric dentistry for the management of dental caries and gingival atrophy. Orthopedic consultations were initiated to monitor bone health and prevent complications such as os-

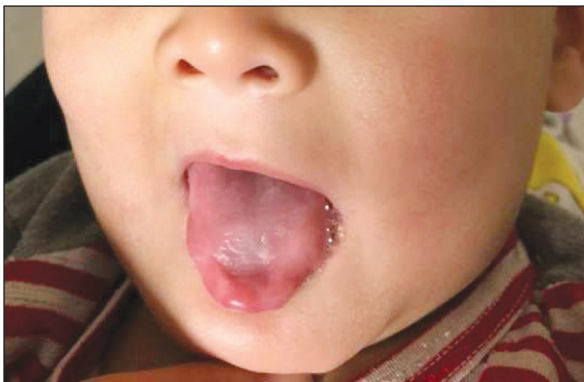

FIGURE 1: Loss of lingual papillae on the tongue

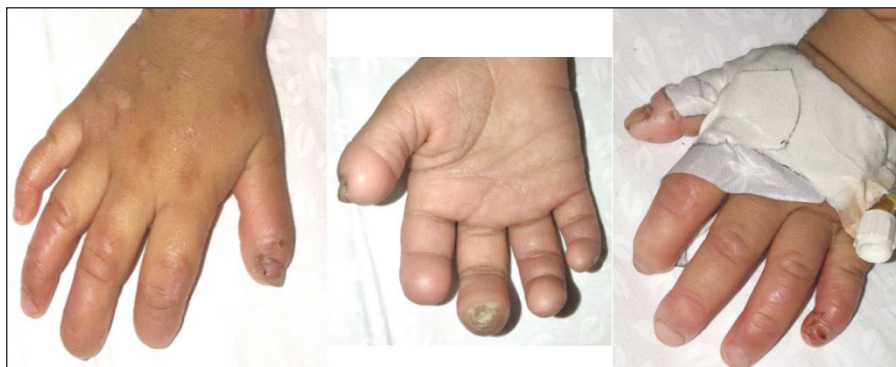

FIGURE 2: Absence of a distal phalanx in the patient's right-hand 2nd and 3rd fingers and left-hand 2nd finger

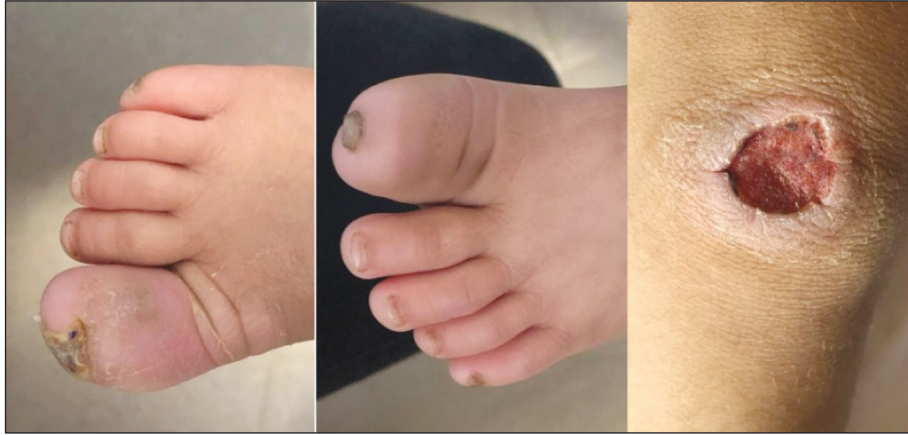

FIGURE 3: Deformity due to self-mutilation in the big toes and a 3x3 cm lesion with an ulcer in the middle and hyperemic surroundings on the knee

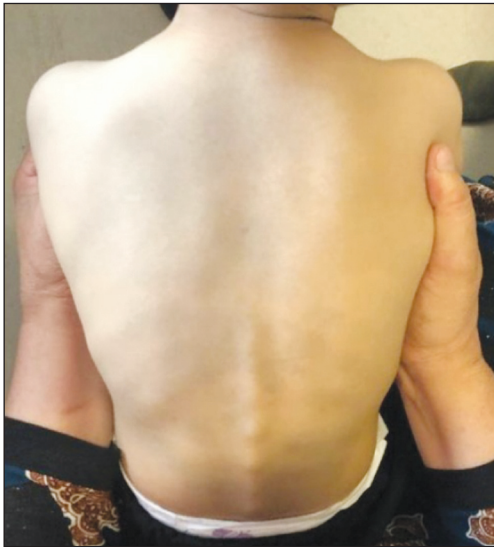

FIGURE 4: Mongolian spot on the back

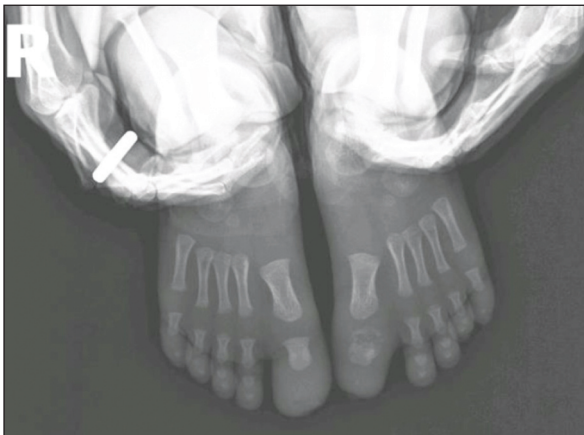


FIGURE 5: Image of suspected osteomyelitis on the first toe of the left foot

teomyelitis and fractures. A nutritionist was involved to address cachexia and support growth. Additionally, the family received education regarding injury prevention strategies to minimize self-mutilation. Neurology and pediatric psychology evaluations were planned to monitor neurodevelopment and emotional wellbeing. The patient's parents gave verbal and written informed consent for the publication of this case report.

DISCUSSION

HSAN-4 belongs to a category of uncommon illnesses referred to as HSAN. Only a limited number of cases have been previously documented in Türkiye.³⁻⁵ This diverse collection of disorders impacts small unmyelinated and specific myelinated neurons, resulting in diminished or nonexistent pain, temperature perception, and varying degrees of autonomic dysfunction.⁶ The NTRK1 gene on chromosome 1q23.1 encodes the TrkA receptor that interacts with NGF. Downstream signalling facilitates the growth and survival of nociceptive sensory and sympathetic neurons.⁷ As illustrated by our clinical report, a homozygous mutation in the NTRK1 gene was identified, consistent with the known genetic basis of HSAN-4.

Patients with HSAN-4 exhibit an elevated risk of corneal scarring and asymptomatic bone fractures, alongside intellectual disability and emotional instability. The significant lack of unmyelinated neurons

and sensory insensitivity in patients with HSAN-4 leads to a heightened incidence of self-harming behaviors, which may differentiate it from other HSANs.⁸ Retaining lacrimal and fungiform papillae on the tongue aids in differentiating HSAN-4 from HSAN-3. The emergence of anhidrosis and related dermatological alterations are significant distinguishing characteristics.⁹ Similarly, our patient exhibited self-mutilation behaviors, including distal phalanx loss, gingival atrophy, and dental damage, in alignment with the described clinical spectrum.

Hyperthermia is a significant problem and must constantly be factored into clinical care. These patients are susceptible to hyperthermia, with a 20% mortality rate within the first 3 years of life. Preventing hyperthermia necessitates vigilant temperature monitoring and appropriate adjustments to ambient temperature. Cooling blankets may be utilized if required. Fever may exhibit resistance to antipyretics.¹⁰ Our patient had recurrent febrile episodes from early infancy, consistent with the hyperthermia-related challenges described in the literature.

Anhidrosis was apparent from early infancy, leading to repeated fever episodes and dermatological symptoms, including thickened skin, dystrophic nails, and hypotrichosis. These dermatological characteristics correspond with previously documented cases.¹¹ Osteomyelitis in our patient further emphasizes the risk of impaired wound healing and susceptibility to infections, which are common in HSAN-4 due to defective immune responses in ectodermal structures.

HSAN-4 is predominantly linked to mutations in the NTRK1 gene at the genetic level. This gene, situated on chromosome 1q23.1, encodes the TrkA receptor, which is crucial for neuronal survival mediated by NGF. The mutations impair NGF signalling, resulting in the targeted degeneration of nociceptive and autonomic neurons.⁹ Our patient exhibited a homozygous NTRK1 mutation, which has been associated with severe phenotypes, including osteomyelitis and progressive auto-amputation. Compared to previous cases, the extent of self-mutilation in our patient appears more extensive, possibly indicating a more aggressive phenotype.

The disease's progressive nature results in auto-amputation, corneal scarring, and the development of Charcot joints. While no definitive treatment is available, management emphasizes injury prevention, wound care, and infection control.¹² In our case, prophylactic antibiotics were started to prevent osteomyelitis progression, highlighting the importance of early intervention.

Given the multisystemic nature of HSAN Type 4, patient management remains highly challenging and necessitates a proactive, multidisciplinary approach. Early genetic diagnosis plays a crucial role by enabling timely coordination among pediatric neurology, dermatology, orthopedics, dentistry, nutrition, psychology, and infectious disease specialists, facilitating preventive strategies and improving overall outcomes. Comprehensive care is essential to address the wide range of clinical complications, including recurrent infections, self-mutilation, bone fractures, growth failure, and hyperthermia. Although no disease-modifying therapies are currently available, early identification and multidisciplinary intervention significantly reduce morbidity and enhance the quality of life in affected individuals. This case underscores the importance of prompt genetic testing and integrated care to prevent severe complications such as osteomyelitis and autoamputation.

Source of Finance

During this study, no financial or spiritual support was received neither from any pharmaceutical company that has a direct connection with the research subject, nor from a company that provides or produces medical instruments and materials which may negatively affect the evaluation process of this study.

Conflict of Interest

No conflicts of interest between the authors and / or family members of the scientific and medical committee members or members of the potential conflicts of interest, counseling, expertise, working conditions, share holding and similar situations in any firm.

Authorship Contributions

Idea/Concept: Havva Özüm Kolsuz, Arife Derda Yücel Şen, Coşkun Yazar; **Design:** Kürşat Bora Çarman, Coşkun Yazar; **Control/Supervision:** Coşkun Yazar; **Data Collection and/or Processing:** Arife Derda Yücel Şen, Havva Özüm Kolsuz; **Anal-**

ysis and/or Interpretation: Oğuz Çilingir; **Literature Review:** Arife Derda Yücel Şen, Havva Özüm Kolsuz; **Writing the Arti-**

cle: Arife Derda Yücel Şen, Havva Özüm Kolsuz; **Critical Review:** Coşkun Yazar.

REFERENCES

1. Mirchi A, Richer J, Oskoui M, McMillan HJ. NTRK1-related hereditary sensory and autonomic neuropathy Type 4: the role of the histamine challenge test. *Child Neurol Open*. 2022;9:2329048X221108826. [PubMed] [PMC]
2. Indo Y, Tsuruta M, Hayashida Y, Karim MA, Ohta K, Kawano T, et al. Mutations in the TRKA/NGF receptor gene in patients with congenital insensitivity to pain with anhidrosis. *Nat Genet*. 1996;13(4):485-8. [Crossref] [PubMed]
3. Bali Ç, Özyılkan NB, Ergenoğlu P, Karslı A, Akin Ş. Konjenital ağrı duyarsızlığı olan bir olguda anestezi yönetimi [Nesthesia management of a patient with congenital insensitivity to pain]. *Journal of Anesthesia*. 2015;23(1):46-8. [Link]
4. Erkal H, Özyurt Y, Temizel F, Arslan G. Konjenital ağrı duyarsızlığı sendromunda anestezi uygulaması: olgu sunumu [Anesthesia management in congenital pain insensitivity syndrome: a case report]. *Bakırköy Tıp Dergisi*. 2013;9(2):78-80. [Crossref]
5. Abdullayev R, Sabuncu Ü, Yıldırım E. Important aspects of anesthetic management of a patient with hereditary sensorial and autonomic neuropathy Type 4: a case report. *Gazi Med J* 2018;29:244-5. [Link]
6. Yozu A, Haga N, Funato T, Owaki D, Chiba R, Ota J. Hereditary sensory and autonomic neuropathy types 4 and 5: Review and proposal of a new rehabilitation method. *Neurosci Res*. 2016;104:105-11. [Crossref] [PubMed]
7. Rothier A, Baets J, De Vriendt E, Jacobs A, Auer-Grumbach M, Lévy N, et al. Genes for hereditary sensory and autonomic neuropathies: a genotype-phenotype correlation. *Brain*. 2009;132(Pt 10):2699-711. [Crossref] [PubMed] [PMC]
8. Suthar R, Sharawat IK, Eggermann K, Padmanabha H, Saini AG, Bharti B, et al. Hereditary sensory and autonomic neuropathy: a case series of six children. *Neurol India*. 2022;70(1):231-7. [Crossref] [PubMed]
9. Echaniz-Laguna A, Altuzarra C, Verloes A, De La Banda MGG, Quijano-Roy S, Tudorache RA, et al. NTRK1 gene-related congenital insensitivity to pain with anhidrosis: a nationwide multicenter retrospective study. *Neurogenetics*. 2021;22(4):333-41. [Crossref] [PubMed]
10. Achouri E, Gribaa M, Bouguila J, Haddad S, Souayeh N, Saad A, et al. La neuropathie héréditaire sensitive et autonome de type IV : à propos de 2 observations [Hereditary sensory and autonomic neuropathy type IV: a report on two cases]. *Arch Pediatr*. 2011;18(4):390-3. French. [Crossref] [PubMed]
11. Toscano E, Andria G. Congenital insensitivity to pain with anhidrosis: an NGF/TrkA-related disorder. *Am J Med Genet*. 2001;99(2):164-5. [Crossref] [PubMed]
12. Axelrod FB, Gold-von Simson G. Hereditary sensory and autonomic neuropathies: types II, III, and IV. *Orphanet J Rare Dis*. 2007;2:39. [Crossref] [PubMed] [PMC]