

Surgical treatment of pulmonary sequestrations: Results of 10 surgically treated patients

Nurettin KARAOĞLANOĞLU, Can KÜRKÇÜOĞLU, Sedat DEMİRCAN, Ali ÖZDÜLGER, Akın KUZUCU, İrfan TAŞTEPE, Sadi KAYA, Mehmet ÜNLÜ, Güven ÇETİN

Dept. of Surgery, Atatürk Chest Diseases and Surgery Center, Ankara, TURKEY

Pulmonary sequestration (PS) is a rare congenital malformation. Between January 1984 and December 1993, 10 cases with PS, being 2 extralobar (ELS) and 8 intralobar (ILS) underwent surgical intervention in our institution. In 6 of the cases, we observed symptoms including recurrent pneumonia, cough and chest pain while 4 of them were completely asymptomatic and were diagnosed on routine chest radiograms. We performed total excision in cases with ELS and lower lobectomy in cases with ILS. [Turk J Med Res 1995; 13(6):185-188]

Key Words: Pulmonary Sequestration surgery

Pulmonary sequestration is a rare congenital malformation. In this malformation there is a nonfunctional lung tissue mass characterized with possessing an own systemic artery. It was first described in 1861 by Rochitansky and Rectorzik as "accessory pulmonary lobe" but it was re-named by Pryce as "pulmonary sequestration" in 1946(1).

Gerle et al described the bronchopulmonary foregut malformations as intralobar pulmonary sequestration, extralobar pulmonary sequestration and communicating sequestration (2).

Intralobar sequestration (ILS) is made from the accessory pulmonary tissue that is invested within adjacent normal lung tissue because of arising before pleural development.

Extralobar sequestration (ELS) is invested within its own pleura because it arises after pleura forms. It grows as a bud and separates from the adjacent lung.

Communicating bronchopulmonary malformation (CBPM) occurs usually between the distal esophagus and the lung.

The arterial supply comes in both ILS and ELS directly from systemic arterial system. ELS uses rarely pulmonary artery, too. The vascular supply in CBPM can be via systemic or pulmonary artery.

The venous drainage in ELS is through the systemic venous, in ILS through the pulmonary venous system and in CBPM through pulmonary or systemic venous system.

In children with recurrent pneumonitis the ILS constitutes a number of the possible causes. The ELS is usually accompanied by many other congenital anomalies and therefore it can be diagnosed quite early. However, if there are no other anomalies, the ELS can remain undiagnosed for a long time until pathology is observed on a routine chest radiograph as in our cases. A sequestration case which is combined with ELS and ILS is also reported (3).

MATERIALS AND METHODS

In Atatürk Chest Diseases and Surgery 10 patients with PS underwent surgical intervention between the years 1984-1993. The histories, the radiographic and operative findings of all cases have been analyzed. The age and gender of the patients and the type and localization of the anomaly in our series are shown on Table 1.

We observed ILS in 6 male in and 2 female patients with the mean age of 24.7 years (5-49 years). Three of the 6 symptomatic patients had recurrent pneumonitis, 2 had cough and 1 had chest pain. Their symptomatic period was between 1 month and 4 years. Two asymptomatic patients were hospitalized with the initial diagnosis of cystic pulmonary lesion recognized on routine chest radiographs.

Received: Nov. 3,1994

Accepted: Oct. 12,1995

Correspondence: Nurettin KARAOĞLANOĞLU
Department of Surgery,
Atatürk Chest Diseases and Surgery Center,
Keçiören, Ankara TURKEY

Table 1. Cases of the Pulmonary Sequestration

Patient	Age	Sex	Type and Localization	Symptom	Operation
1	9	M	ELS-LLL	—	excision
2	49	F	ELS-LLL	—	excision
3	49	M	ILS-RLL	Recurrent pneumonia	RLL
4	36	M	ILS-RLL	Recurrent pneumonia	RLL
5	9	M	ILS-RLL	Cough	RLL
6	26	F	ILS-RLL	Chest pain	RLL
7	40	F	ILS-RLL	Recurrent pneumonia	LLL
8	8	M	ILS-RLL	—	RLL
9	25	M	ILS-RLL	Cough	RLL
10	5	M	ILS-RLL	—	RLL

Localization: LLL; Lenf Lower Lobe
RLL; Right Lower Lobe

Operation: LLL; Left Lower Lobectomy
RLL; Right Lower Lobectomy

M; Male
F; Female

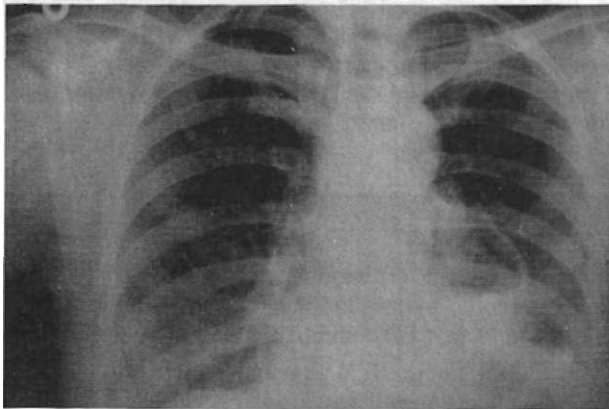


Figure 1. The radiologic appearance of the pulmonary sequestration in the posterioanterior chest radiograph.

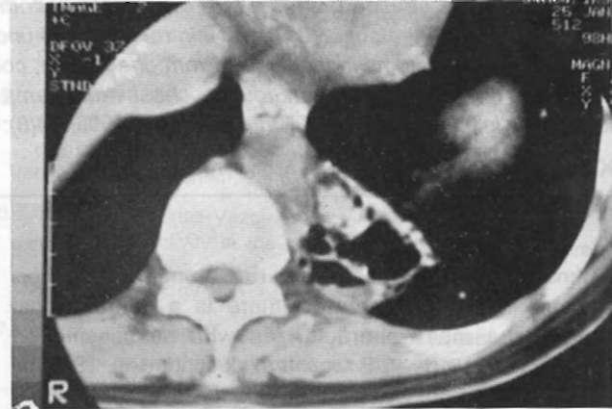

Figure 2. The computerized tomographic appearance of ILS in the left lower lobe.

RESULTS

In 7 of the 8 cases with ILS the lesions were in the right lower lobes and in one case in the left lower lobe. In 3 of the cases in this group, the lesions were reported as possible pulmonary sequestration according to computerized tomographic investigation; aortography could indicate the systemic arterial supply in these 3 patients. Peroperatively, we observed that the sequestrations were located in the lower lobes and we performed 7 right lower lobectomies and 1 left lower lobectomy with ligations of the abnormal arterial supplies.

The arterial supply originated from abdominal aorta in 3 patients and from thoracic aorta in 5. The venous drainage was to pulmonary vein 2 patients, to azygos and hemiazygos veins in 1 patients each and in 2 patients we could not identify the route of the venous drainage.

Our 2 patients with ELS were a 9-year old boy and a 49-year old woman. They were both asymptomatic and their lesions were on the left side. They were broncoscopically normal.

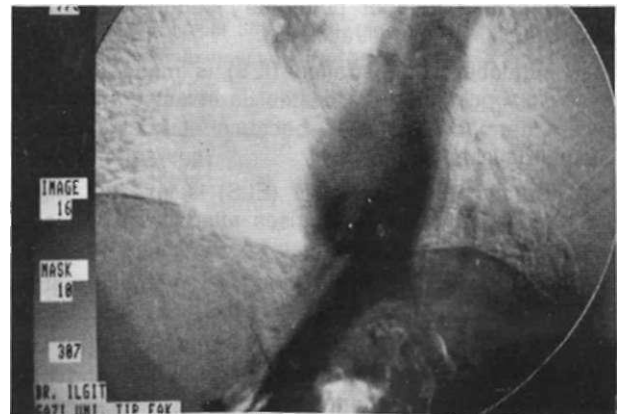


Figure 3. The aortography, showing the systemic arterial supply arising from the abdominal.

The operative exploration of the first patient revealed a mass of 5x5x7 cm in dimensions near the aortic arch. Its arterial supply originated from descending aorta. This artery was ligated and the mass was removed totally.

In the second case the sequestration was located between the lingular segment and the pericardium. It was 3x5x5 cm in size and it had an artery from descending aorta and a venous drainage to hemiazygos vein. In both cases the microscopic findings were compatible with PS.

All of these patients who underwent pulmonary resection, were discharged with no problem during postoperative period (an average of 10 days)

We followed the patients within periods varying from 1 year to 4 years, with routine physical examination and chest radiograms. Neither symptom nor recurrence was observed.

DISCUSSION

Savic et al (4) reported that ILS constitutes 0.15-1.7 % of all congenital anomalies and the incidence in males and females is 53.2 % and 46.8%, respectively. This anomaly is much more frequent on the left side. In 97.75% of the cases the lesions are located in lower lobes and especially in the medial and posterior basal segments. The accompanying congenital anomalies are rare in this type (5-7). In all of our patients the lesions were in the lower lobes but it is quite surprising that we observed this anomaly more frequently on the right side than on the left. ILS is an important cause of recurrent pneumonitis in children and only 15% of cases are completely asymptomatic (8). We established recurrent pneumonitis in 3 of our patients.

There is a general agreement that ELS is observed 50-60% with other congenital anomalies. The most frequent accompanying malformations involve diaphragm, cardiovascular system and bronchial tree (9). We did not observe any other congenital anomalies. There is no gender predominance in ELS cases (4).

The lesions are usually located between the lower lobe and the diaphragm and it is more often observed on the left side. There are mediastinal or even intraabdominal lesions (9-11).

In 1946, Pryce described and classified pulmonary sequestration and claimed that the both types were of congenital origin (12). Today some of the authors agree with him while some other are of the opinion that ILS is a consequence of a destructive bronchopulmonary disease (2,13,14).

Pulmonary sequestration is usually symptomatic. Even in patients without subjective complaints bronchopulmonary infection could be shown (15,16). Juettner et al (5) showed that tuberculosis, aspergillosis, bronchial carcinoid and even bronchogenic carcinoma could arise from the sequestered lung tissue. The risk of hemorrhage is also higher in these patients because of possibly accompanying A-V malformations (15,17).

The only treatment for PS is resection. During surgery great attention should be paid to the dissection of the arterial supply because mortal hemorrhage can occur (15). Although the risk of hemorrhage in the operation, preoperative routine aortography is controversial.

Pulmoner sekestrasyonun cerrahi tedavisi: Cerrahi olarak tedavi edilen 10 hastanın sonuçları

Pulmoner sekestrasyon nadir bir konjenital malformasyondur. Ocak 1984 ile Aralık 1993 tarihleri arasında ikisi extralober, 8'i intralober olmak üzere 10 pulmoner sekestrasyonlu hastada enstitü-müzde cerrahi düzeltme yapıldı. Vakaların 6'sında tekrarlayan pnömoni, öksürük ve göğüs ağrısı tespit edilirken, 4 tanesi tamamen asemptomatik ve rutin akciğer filminde tespit edilmişti. Ekstra lobar pulmoner sekestrasyonlu hastalarda toral eksizyon ve intralober pulmoner sekestrasyonlu hastalarda alt lobektomi yapıldı.

[TurkJMedP.es 1995; 13(6): 185-188]

REFERENCES

1. Shamji FM, Sachs HJ, Perkins Dg. Cystic disease of the lungs. Surg Clin North Am. 68: 581-620, 1988.
2. Gerle RD, Jaretzki A, Ashley CA et al. Congenital bronchopulmonary foregut malformation; preliminary sequestration communicating with the gastrointestinal tract. N.Engl. J.Med. 1968; 278:1413-1415.
3. Özdemir N, Akal M, Tuncözgür B et al. A new type of pulmonary sequestration (case report). Journal of Ankara Medical School. 1992; 14. 405-409.
4. Savic B, Birtel J, Tholen W, et al. Lung sequestration. Report of seven cases and a review of 540 published cases. Thorax 34: 96 1979.
5. Juettner FM, Pinter HH, Frieß GB et al. Bronchial carcinoid arising in intralobar bronchopulmonary sequestration with vascular supply from ten left gastric artery. J.Thoracic Cardio, vasc. Surg. 1985; 90.25.
6. Sabinston Jr, Spencer FC. Gibson's Surgery of the Chest WB. Saunders Company Philadelphia, 4. Edition. 1990; 789-795.
7. Savic B, Birtel FJ, Knoche R, et al. Pulmonary sequestration In: Frieß HH, Harnack GA, Martini GA et al. eds. Advances In Internal Medicine and Pediatrics. New York. Springer-Verlag. 1979: 58-92.
8. John PR, Beasley SW, Mayne V. Pulmonary sequestration and related congenital disorders. Pediatr.Radiol.1989;20: 4-9.
9. Stocker JT. Sequestrations of the lung. Semin.Diag.Pathol.1986;3:16-121.

10. Fu-Jan Ke, Shi-Chvan Chang, et al. Extralobar Pulmonary Sequestration Presenting as an Anterior Mediastinal Tumor in an Adult. *Chest* 1993; 104:303-04.
11. Black MD, Bass J, Martin DJ et al. Intraabdominal pulmonary sequestration. *J.Pediatr. Surg.* 1991; 26:1381-1383.
12. Pryce DM. Lower accessory pulmonary artery with intralobar sequestration of lung: A report of seven cases. *J.Pathol. Bacteriol* 1946; 58: 457-467.
13. Hruban RH, Shumway SJ, et al. Congenital bronchopulmonary foregut malformations. Intralobar and extralobar pulmonary sequestration communicating with the foregut. *Am.J.Clin.Path.* 1989; 91:403-409.
14. Gebaver PW, Mason CB. Intralobar pulmonary sequestration associated with anomalous pulmonary vessels. A nonentity. *Dis. Chest* 1959; 35: 282-288.
15. Sugio K, Kanetos, et al. Pulmonary sequestration in lower child and in adults. *Int. Surg.* 1992; 77:102-107.
16. Çetin G, Yüksel M, et al. Pulmonary Sequestration. *The Medical Bulletin of Numune Hospital* 1981; 21; 153-158.
17. Stocker JJ, Malczak HT. A Study of pulmonary ligament arteries relationship to intralobar pulmonary sequestration. *Chest.* 1984; 86: 611-615.