

Nodular Colloid Degeneration of the Skin: Differential Diagnosis

Derinin Nodüler Kolloid Dejenerasyonu

Adile Ferda DAĞLI, MD,^a
Mehmet Reşat ÖZERCAN, MD,^a
Demet ÇİÇEK, MD^b

Departments of
^aPathology,
^bDermatology
Fırat University Faculty of Medicine,
Elazığ

Geliş Tarihi/Received: 27.06.2008
Kabul Tarihi/Accepted: 18.12.2008

*This study was presented as a poster at
2nd Turkish Ecopathology Congress,
June 29-July 2, 2006, Elazığ.*

Yazışma Adresi/Correspondence:
Adile Ferda DAĞLI, MD
Fırat University Faculty of Medicine,
Department of Pathology, Elazığ,
TÜRKİYE/TURKEY
ferda58@yahoo.com

ABSTRACT Colloid milium is a rare disorder characterized by translucent papules occurring on sun exposed areas of the body. Nodular colloid degeneration is a very rare type of colloid milium. A sixty-nine year old male patient engaged in farming presented to our hospital with facial lesions, which were itchy at times, and which had started 3 years ago and had increased thereafter. His dermatological examination revealed yellow, translucent, and gelatinous papules and plaques, with purplish foci, on the forehead and around both eyes. Biopsies were obtained with a presumptive diagnosis of systemic amyloidosis. Histopathological examination revealed nodular colloid degeneration. Lesions regressed after cryotherapy. Since colloid milium and nodular colloid degeneration, which is a type of it, are very rare and thus are not recognized until definitive diagnosis. Therefore, they should be considered in cases that have a long history of exposure to sun, and in the differential diagnosis of amyloidosis. Colloid milium is amenable to treatment with cryotherapy, dermabrasion, diathermia and long-pulsed Er: YAG laser.

Key Words: Skin diseases, metabolic; pathology

ÖZET Kolloid milium, vücudun güneş gören bölgelerinde ortaya çıkan, translüsent papüllerle karakterize ender bir hastalıktır. Nodüler kolloid dejenerasyon, kolloid miliumun çok az rastlanan bir tipidir. Altmış dokuz yaşında, çiftçilikle uğraşan erkek hasta, yüzünde 3 yıl önce başlayan ve giderek artan, zaman zaman kaşıntılı, yara şikayetiyle hastanemize başvurdu. Dermatolojik muayenesinde, alında ve her iki göz çevresinde yer yer mor renkli odaklar içeren, sarı renkli, saydam, jelatinöz içerikli papüller ve plaklar görüldü. Sistemik amiloidoz düşünülerek biyopsi alındı. Histopatolojik incelemede nodüler kolloid dejenerasyon tanısı verildi. Kriyoterapiden sonra lezyonların gerilediği görüldü. Kolloid milium ve onun bir tipi olan nodüler kolloid dejenerasyon oldukça ender görüldüğünden genellikle histopatolojik tanı verilene kadar düşünülmez. Bu nedenle uzun süre güneşe maruz kalma hikayesi olan olgularda ve amiloidoz ayırıcı tanısında mutlaka düşünülmelidir. Kolloid milium kriyoterapi, dermabrazyon, diatermi ve Er: YAG lazer ile tedavi edilebilir.

Anahtar Kelimeler: Metabolik deri hastalıkları, patoloji

Türkiye Klinikleri J Med Sci 2009;29(2):562-5

Nodular colloid degeneration, a rare type of colloid milium, is characterized by a single, large nodule or multiple nodules. It most commonly develops on the face, chin, and scalp.¹ It is most frequently confused with systemic and primary cutaneous amyloidosis, both clinically and histopathologically.² This case with a clinical diagnosis of amyloidosis and a definitive histopathological diagnosis of nodular colloid degeneration was presented due to its rare occurrence.

A sixty-nine year old male patient engaged in farming presented to our hospital with facial lesions, which were itchy at times, and which had started 3 years ago and had increased thereafter. His dermatological examination revealed yellow, translucent, and gelatinous papules and plaques, with purplish foci, on the forehead and around both eyes (Figure 1). General physical examination, hematological and biochemical values of the patient were normal, except that he had tinea pedis. Biopsy was obtained with a presumptive clinical diagnosis of systemic amyloidosis. Histopathological examination revealed a pink, fissured, and homogenous material that filled the dermis almost entirely, below the occasionally flattened epidermis. Fibroblast nuclei were scattered here and there and fat and hair follicles were preserved (Figure 2). Nodular colloid degeneration diagnosis was made upon finding that the material filling the dermis stained negative with Congo red and positive with PAS and D-PAS in the histochemical analysis (Figure 3).

Colloid milium of the skin is a rare dermatosis that develops in areas exposed to sun, particularly on the face, neck and dorsal part of the hands. Together with amorphous material accumulation, dermis is observed to contain shiny, yellowish brown, firm, and translucent small (1-5 mm) papules, resembling wax. When the lesions are opened, gelatinous material may emerge.² It generally has no symptom other than itching. Although its etio-

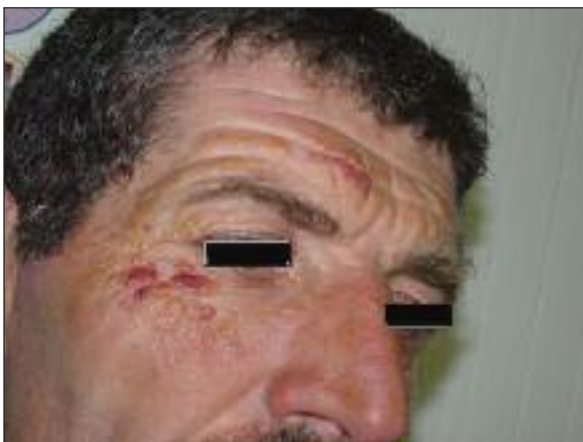

FIGURE 1: Yellow, translucent, and gelatinous papules and plaques with purplish foci, on the forehead and around both eyes.

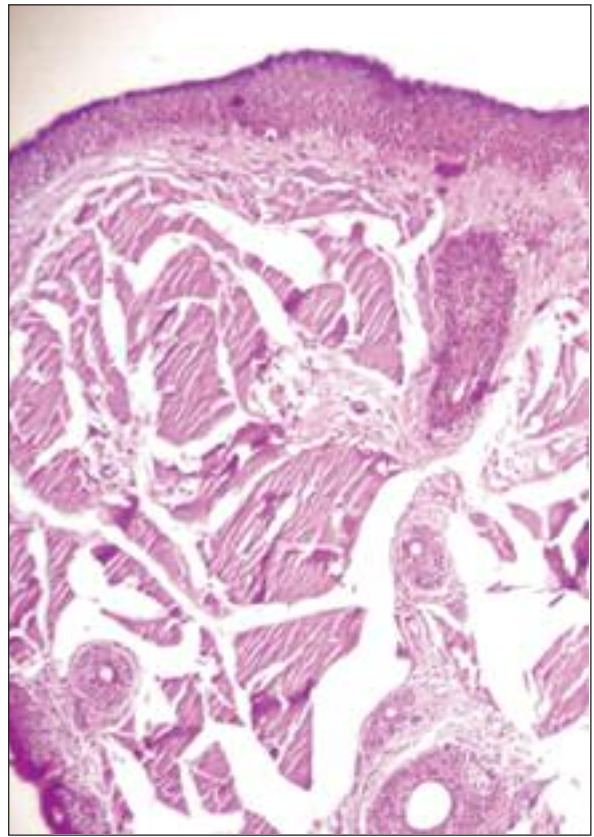


FIGURE 2: Amorphous colloid material occupies nearly the whole dermis in the nodular colloid degeneration of the skin (HE, X40).

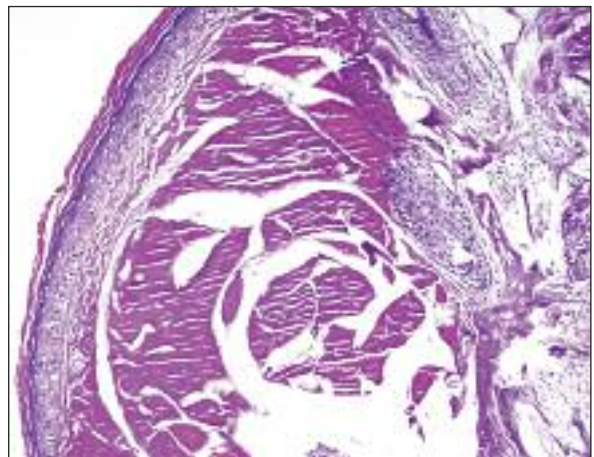


FIGURE 3: Amorphous colloid material stained positive with PAS (x100).

logy is not clear, long-term exposure to UV light is suggested as the triggering factor. In addition, exposure to oil products that are thought to intensify the effect of sunlight, creams that include hydroquinone, and machine oils, as well as genetic dispo-

sition are other factors that are held responsible.

Nodular colloid degeneration has 3 types, adult colloid milium, juvenile colloid milium, and nodular colloid degeneration.^{1,2} Recently a new type associated with hydroquinone use, and called pigmented colloid milium, has been described.² Adult colloid milium makes up most of the literature data about colloid milium, as it is the most common type. There is no detailed information about nodular colloid degeneration, which is extremely rare.

Adult colloid milium was first reported by Wagner in 1866. Wagner, who thought that this lesion originated from the distal portions of the acini of sebaceous glands, used the term colloid milium to differentiate it from sebaceous retention cyst.² Adult colloid milium is seen in people, particularly men (M/F: 4/1), with fair skin and between 30-50 years, who work outdoors.² Electron microscopic and immunohistochemical studies support the view that the triggering factor is sunrays.² The juvenile type, which starts before puberty is fairly rare, and is not different from the adult type clinically. Since half of the cases reported have the disease in family history, the possibility of a hereditary defect is considered.¹

Nodular colloid degeneration, which is seldom reported in the literature, was first defined by Labadie in 1927. It appears in the form of a single larger (0.5-5 mm) nodule or multiple soft, purplish-yellow smooth plaques or nodules.¹ There may also be telangiectasia and purpura. Although it is dominantly located on the face, it may also appear on the body and extremities. Despite a lack of sufficient data, it is claimed in some sources that exposure to sun does not have a part in its etiology, due to cases in whom the disease is limited to the body.¹ Our case has been engaged in farming for about 50 years, and had a story of long-term exposure to sun, as reported in other cases. Therefore, our case may contribute to the etiology of exposure to sun, which is suspected to play a role in the formation of nodular colloid degeneration.

Histopathological findings of colloid milium vary according to its type. In adult type colloid milium,

homogenous colloid material accumulates in upper-middle dermis, and is separated from the epidermis generally by a narrow connective tissue zone (Grenz zone).¹ In the juvenile type, colloid accumulated in the papillary dermis is adjacent to the basal layer of the epidermis. There is typically no Grenz zone and solar elastosis. In nodular colloid degeneration, the upper four thirds of the dermis, or even all of it, is filled with pale pink and fissured colloid.¹ Fibroblast nuclei scattered in the colloid and some expanded capillaries may be seen. Epidermis is usually flattened and hair follicles and sebaceous glands are preserved.¹ Histopathological appearance of our case with a clinical diagnosis of amyloidosis and clinically identical to adult colloid milium, clinically, was consistent with nodular colloid degeneration.

Previously colloid was assumed an abnormal product of degenerated collagen, elastic fibers, serum proteins, or fibroblasts. Presently, it is known that colloid is produced by elastic fibers or fibroblasts, which have undergone actinic degeneration.² Colloid is of epidermal origin in the juvenile type and of dermal origin in other types.¹ Due to this pathogenetic difference, histochemical and immunohistochemical characteristics also differ between adult and juvenile types. Histopathologically, colloid is PAS and D-PAS positive.¹ It does not stain with Congo red in the adult type, but can stain positive in the juvenile type.¹ In the histochemical examination of our case, while Congo red stained negative, PAS and D-PAS were positive. However, immunohistochemical differentiation of amyloid was not possible due to its lack in our laboratory.

Differential diagnoses of colloid milium include amyloidosis, sebaceous hyperplasia, sarcoidosis, trichoepithelioma, tuberous-sclerosis, syringoma, steatocystoma multiplex, lipoid proteinosis, retention cyst, molluscum contagiosum, and papular mucinosis. Of these, colloid milium is most frequently confused with systemic and primary cutaneous amyloidosis, both clinically and histopathologically.²

Success with dermabrasion, cryotherapy and diathermia is limited in the treatment of colloid

milium. Long-pulsed Er: YAG laser should be considered an effective alternative to dermabrasion for facial colloid milium.³ Currently we do not have dermabrasion, diathermia and Long-pulsed Er: YAG facilities in our department; thus cryotherapy was chosen as an appropriate and inexpensive treatment modality. In our case, lesions regressed after cryotherapy. Cryotherapy is a widely used treatment modality in dermatology. Its place in cutaneous malignant and premalignant diseases is well established; however, it also has great utility with benign lesions. Sun-damaged skin and sun-induced neoplasms are amenable to treatment with cryotherapy. Solar keratoses, solar lentigines sebaceous hyperplasia, colloid milium, diffusely pigmented skin and fine wrinkles of solar ageing all respond to cryotherapy.⁴ Cryotherapy works by destroying tissue by freezing. The mechanism of treatment involves inducing tissue damage, vascular

stasis and occlusion, as well as inflammation, to destroy unwanted tissue. Tissue injury results from intracellular and extracellular formation of ice, disruption of cell membranes, and circulatory changes in the skin caused by freezing and thawing.⁵ Critical factors influencing cellular necrosis are rate of freezing, temperature, duration of freezing, and rate of thawing. After destruction of epidermal lesions, healing involves rapid re-epithelialization over a relatively cold insensitive dermal network.⁴

In conclusion, since colloid milium and nodular colloid degeneration, which is a type of it, are rare and are not suspected until definitive diagnosis. Therefore, they should be considered in cases that have a long history of exposure to sun, and in the differential diagnosis of amyloidosis. Additionally colloid milium is amenable to treatment with cryotherapy, dermabrasion, diathermia and long-pulsed Er: YAG laser.

REFERENCES

1. Maize J, Metcalf J. Metabolic diseases of the skin. In: Elder D, Elenitsas R, Jaworsky C, Johnson B, eds. *Lever's Histopathology of the Skin*. 8th ed. Philadelphia: Lipincott-Raven; 1997. p.369-403.
2. Kirtak N, Inaloz HS, Karakok M, Ozgoztasi O. A case of adult colloid milium with chronic sun exposure. *Int J Dermatol* 2002;41(12):936-8.
3. Ammirati CT, Giancola JM, Hruza GJ. Adult-onset facial colloid milium successfully treated with the long-pulsed Er: YAG laser. *Dermatol Surg* 2002;28(3):215-9.
4. Thai KE, Sinclair RD. Cryosurgery of benign skin lesions. *Australas J Dermatol* 1999;40(4): 175-84.
5. Wetmore SJ. Cryosurgery for common skin lesions. Treatment in family physicians' offices. *Can Fam Physician* 1999;45:964-74.