

A Case Report of Three Dimensional Transthoracic Echocardiographic View of Acute Proximal Type Aortic Dissection

Akut Proksimal Tip Aort Diseksiyonunun Üç Boyutlu Transtorasik Ekokardiyografi ile Görünümü

Özgül MALÇOK GÜREL,^a
Nurcan BAŞAR,^b
Hikmet Selçuk GEDİK,^c
Kemal KORKMAZ,^c
Bora DEMİRÇELİK^a

^aDepartment of Cardiology,
Turgut Özal University Faculty of Medicine,

^bClinic of Cardiology,
Türkiye Yüksek İhtisas Training and
Research Hospital,

^cClinic of Cardiovascular Surgery,
Ankara Numune Training and
Research Hospital,
Ankara

Geliş Tarihi/Received: 27.05.2013
Kabul Tarihi/Accepted: 31.10.2013

Yazışma Adresi/Correspondence:
Özgül MALÇOK GÜREL
Turgut Özal University Faculty of Medicine,
Department of Cardiology, Ankara,
TÜRKİYE/TURKEY
drdemircelik@yahoo.com,

For the video/videos of the article:



doi: 10.5336/caserep.2013-36307

Copyright © 2015 by Türkiye Klinikleri

ABSTRACT A 67 year-old female patient was admitted to our emergency room with the complaint of severe and sudden onset tearing like chest pain lasting for an hour. Immediately performing two-dimensional transthoracic echocardiography (2DTTE), pericardial effusion and an undulating intimal flap within the aortic lumen starting from the non-coronary cuspid were visualized. Ascending aorta was 7.6 cm in diameter. Real-time three-dimensional (RT 3D) TTE confirmed the diagnosis. Once the diagnosis of acute proximal type aortic dissection is suspected which modality to be chosen depends on clinical status of the patient and technical availability of the hospital. Non-invasive diagnostic modalities like contrast enhanced computed tomography (CECT), magnetic resonance imaging (MRI) may be preferred over invasive aortography. As transesophageal echocardiography (TEE) is a semi-invasive procedure and is mostly used intraoperatively, TTE may be preferred instead of TEE. RT 3DTTE is a helpful equipment in confirming the diagnosis of aortic dissection by 2DTTE. RT 3DTTE is advantageous in terms of accessibility and applicability at bedside and being a non-invasive procedure.

Key Words: Dissection; echocardiography, three-dimensional; diagnostic equipment

ÖZET Altmış yedi yaşında kadın hasta bir saattir devam eden, yırtıcı karakterde, ani göğüs ağrısı ile acil servisimize başvurdu. İvedilikle yapılan transtorasik ekokardiyografi (TTE) incelemesinde perikardiyal effüzyon ve non-koronar küspisten başlayıp aortik lümene uzanan intimal flep görüldü. Hastanın asendan aortası 7,6 cm ölçüldü. Eş zamanlı üç boyutlu (3B) TTE ile tanı doğrulandı. Diseksiyon tanısında, klinik durum ve teknik yeterliliğe göre non-invaziv tanı yöntemlerinden bilgisayarlı tomografi (BT), manyetik rezonans görüntüleme (MRG) hatta invaziv angiografi yapılabilir. Daha çok intraoperatif kullanımı ön planda olan transözofageal ekokardiyografi (TÖE)'nin yarı invaziv de olması nedeniyle, yatak başı tanıda TÖE yerine, TTE tercih edilebilir. Gerçek zamanlı 3BTTE, aort diseksiyonu tanısını doğrulamada 2BTTE'ye yardımcı bir araçtır. 3BTTE ulaşılabilirlik, non-invaziv olması ve yatak başı uygulanabilmesi yönünden avantajlıdır.

Anahtar Kelimeler: Diseksiyon; ekokardiyografi, üç boyutlu; tanı cihazı

Türkiye Klinikleri J Case Rep 2015;23(1):73-5

Acute proximal type aortic dissection is one of the cardiac emergency situations. Mortality increases dramatically if diagnosis and management delay. The diagnostic method should be carefully chosen. Here we present an acute proximal type aortic dissection case immediately diagnosed by both the 2D and 3DTTE.

CASE REPORT

A 67-year-old female patient was admitted to our emergency room with the complaint of severe and sudden onset tearing like chest pain lasting for an hour. On physical examination, heart rate was 109 beats/min and rhythmic, arterial blood pressure of both arms were 170/100 mmHg. Right and left radial and femoral pulses were palpable normally and she was neurologically intact.

Immediately performing 2DTTE, pericardial effusion and an undulating intimal flap within the aortic lumen starting from the non-coronary cusp were visualized (Figure 1, Video 1). Ascending aorta was 7.6 cm in diameter. RT 3DTTE confirmed the diagnosis (Figure 2, Video 2).

Necessitating no other imaging modality, she was emergently taken to the operating room by the cardiovascular surgery team because of impending cardiac tamponade. Door-to-operating room for this -relatively lucky-patient was approximately 45 minutes.

DISCUSSION

Once the diagnosis of acute proximal type aortic dissection is suspected, it is essential to confirm the diagnosis promptly and accurately as mortality increases in progressing hours. Mortality is very high being 1-2% per hour during the first two days, if not managed.¹ Diagnostic modalities currently available for this purpose include aortography, CECT, MRI, and TTE or TEE. Which modality to be chosen depends on clinical status of the patient and technical availability of the hospital.² Non-invasive diagnostic modalities like CECT, MRI may be preferred over invasive aortography.³ However, in a case with impending cardiac tamponade, transferring the patient for CECT or MRI may be time consuming. TEE, as it's a semi-invasive diagnostic tool may be preferred especially in the operating room. In recent years, 3DTEE started to be used more often as it maintains more accurate diagnosis compared with 2DTEE. Sasaki et al. emphasized in their study that coronary involvement is better evaluated by 3DTEE, rather than by computed tomography and 2DTEE in the operating room.⁴ Similarly, Joshi et al displayed that

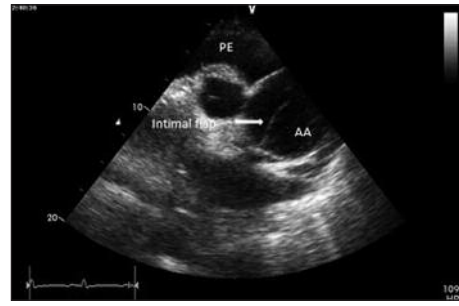

FIGURE 1: Modified parasternal long axis view of two dimensional transthoracic echocardiography demonstrating intimal dissection flap.

AA: Ascending aorta; PE: Pericardial effusion.

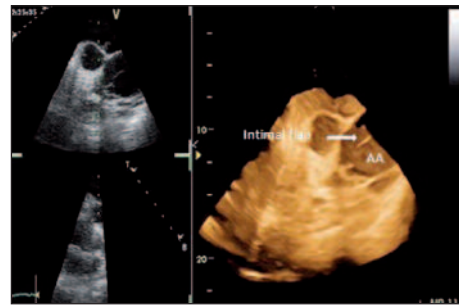


FIGURE 2: Modified parasternal long axis view of real time three dimensional transthoracic echocardiography demonstrating intimal dissection flap.

AA: Ascending aorta.

intraoperatively, 3DTEE provides more confident diagnosis compared with 2DTEE in patients with aortic aneurysm and dissection.⁵ In order not to waste time at bedside, TTE may be applied as it's non-invasive and easily performed. 3DTTE may be preferred in available clinics as it detects exact location of the rupture site and displays the dissection flap like a sheet in a 3D view rather than just a line in 2D view. Artifacts seen like dissection flap in 2D view may be overcome by 3D view. Htay et al. present in a study that they couldn't promptly diagnose five of ten aortic dissection cases by only 2DTTE but 3DTTE aid them.⁶ In our case, 3DTTE was also helpful in confirming the diagnosis of aortic dissection and sending our patient to operating room immediately.

CONCLUSION

Real time 3DTTE aids 2DTTE in diagnosing aortic dissection. It is an advantageous and acceptable tool as it is non-invasive and could easily be performed at bedside in the technically available clinics.

REFERENCES

1. Prêtre R, Von Segesser LK. Aortic dissection. *Lancet* 1997;349(9063):1461-4.
2. Erbel R, Alfonso F, Boileau C, Dirsch O, Eber B, Haverich A, et al. Diagnosis and management of aortic dissection. *Eur Heart J* 2001; 22(18):1642-81.
3. Cigarroa JE, Isselbacher EM, DeSanctis RW, Eagle KA. Diagnostic imaging in the evaluation of suspected aortic dissection. Old standards and new directions. *N Engl J Med* 1993;328(1):35-43.
4. Sasaki S, Watanabe H, Shibayama K, Mahara K, Tabata M, Fukui T, et al. Three-dimensional transesophageal echocardiographic evaluation of coronary involvement in patients with acute type A aortic dissection. *J Am Soc Echocardiogr* 2013;26(8):837-45.
5. Joshi D, Bicer EI, Donmez C, Hsiung MC, Nanda NC, Sadat K, et al. Incremental value of live/real time three-dimensional transesophageal echocardiography over the two-dimensional technique in the assessment of aortic aneurysm and dissection. *Echocardiography* 2012;29(5):620-30.
6. Htay T, Nanda NC, Agrawal G, Ravi BS, Dod HS, McGiffin D. Live three-dimensional transthoracic echocardiographic assessment of aortic dissection. *Echocardiography* 2003; 20(6):573-7.