

Inhaled Hydrogen Gas Therapy for Prevention of Renal Ischemia/Reperfusion Injury in Rat Model

Sıçan Modelinde Böbrek İskemi-Reperfüzyon Hasarının Önlenmesinde Hidrojen Gazı İnhalasyonunun Etkisi

Ekrem AKDENİZ,^a
Yakup BOSTANCI,^a
Ender ÖZDEN,^a
Bilge Can MEYDAN,^b
Ali Faik YILMAZ,^a
Şaban SARIKAYA,^a
Yarkin Kamil YAKUPOĞLU^a

^aUrology,
^bPathology,
Ondokuz Mayıs University
Faculty of Medicine, Samsun

Geliş Tarihi/Received: 07.11.2012
Kabul Tarihi/Accepted: 04.04.2013

Yazışma Adresi/Correspondence:
Yakup BOSTANCI
Ondokuz Mayıs University
Faculty of Medicine
Department of Urology, Samsun,
TÜRKİYE/TURKEY
dryakupbostan@yahoo.com

ABSTRACT Objective: We aimed to show the short- and long-term protective effects of inhaled hydrogen gas on renal ischemia/reperfusion (I/R) injury in a rat model. **Material and Methods:** Thirty Sprague-Dawley rats were randomly divided into 3 major experimental groups (Group 1, sham; Group 2, I/R; Group 3, hydrogen-I/R). Subsequently, Group 2 and 3 were divided into subgroups as early (E) and late (L) periods. Group 2 and 3 underwent 45 minutes of renal ischemia. Group 3 was administered 182.5 min (175-185 min) 2% hydrogen gas (2 L/min) in total (1 h before ischemia, by ischemia period and 1 h after reperfusion). Left nephrectomy was performed 6 hours after reperfusion in the early groups and at the 14th day of reperfusion in the late groups. We performed histopathological examination. **Results:** Kidneys from control rats (Group 2) exhibit significant injury characterized by marked histological changes characteristic of I/R injury in the outer medulla and cortex regions. Histological alterations were markedly reduced and all histological scores for renal injury were significantly lower in specimens from the hydrogen-I/R group compared to the control group (p=0.001). **Conclusion:** In this study, we demonstrated that hydrogen gas significantly attenuated renal I/R injury in early and late periods, and may have therapeutic potential against various clinical conditions involving I/R injury.

Key Words: Kidney; oxidative stress; reactive oxygen species; reperfusion injury

ÖZET Amaç: Bu deneysel çalışmada, bir sıçan modelinde böbrekteki iskemi/reperfüzyon (İ/R) hasarında hidrojen gazı inhalasyonunun erken ve geç dönemdeki doku koruyucu etkisinin araştırılması amaçlandı. **Gereç ve Yöntemler:** Otuz adet Sprague Dawley tipi sıçan rastgele 3 ana cerrahi gruba ayrıldı (Grup 1, sham; Grup 2, İ/R; Grup 3 hidrojen-İ/R). Daha sonra Grup 2 ve 3 erken (E) ve geç (G) dönem olarak alt gruplara ayrıldı. Grup 2 ve 3'teki sıçanların sol renal pedikülleri 45 dakika tam oklüzyona uğrattıldı. Grup 3'teki sıçanlara ise iskemiden 1 saat önce, iskemi süresince ve iskemiden 1 saat sonra toplam 182,5 (175-185) dakika %2 hidrojen gazı verildi (2 L/dak). Erken dönem gruplarda reperfüzyonun 6. saatinde, geç dönem gruplarda ise 14. gününde sol nefrektomi yapıldı. Böbrekte gelişen İ/R hasarına hidrojen gazının erken ve geç dönemdeki etkileri histopatolojik olarak değerlendirildi. **Bulgular:** Kontrol grubundaki sıçanların (Grup 2) böbrek dış medulla ve korteks bölgelerinde İ/R hasarının belirgin histolojik değişiklikleri ile karakterize ciddi yaralanma bulguları izlendi. Hidrojen-İ/R Grubunda (Grup 3) ise kontrol grubu ile karşılaştırıldığında bu değişikliklerde belirgin azalma ve renal hasar için tüm histolojik skorlarda anlamlı olarak düşüklük saptandı (p=0,001). **Sonuç:** Bu çalışmada hidrojen gazının böbrekteki İ/R hasarını erken ve geç dönemde önemli ölçüde azalttığını saptadık. Hidrojen gazının, İ/R hasarı içeren çeşitli klinik koşullarda terapötik potansiyeli olabileceği düşüncesindeyiz.

Anahtar Kelimeler: Böbrek; oksidatif stres; reaktif oksijen türleri; reperfüzyon hasarı

Türkiye Klinikleri J Med Sci 2013;33(4):1097-102

doi: 10.5336/medsci.2012-32626

Copyright © 2013 by Türkiye Klinikleri

Ischemia/reperfusion (I/R) injury, including arterial occlusion, shock, and organ transplantation, is a common finding in clinical settings. I/R of native and transplant kidneys is a major cause of acute kidney injury

and an important determinant of long-term kidney dysfunction.^{1,2} Increasing evidence has accumulated over the past decade indicating that oxidative stress resulting from the production of reactive oxygen species (ROS), such as hydrogen peroxide, superoxide and hydroxyl radicals, contribute to renal I/R injury.^{3,4} Tissue damage from ROS activates several defense mechanisms that include the production of anti-oxidants, such as superoxide dismutase (SOD), catalase and glutathione peroxidase (GSH).⁵ Treatments with exogenous anti-oxidants or scavengers of ROS have shown the ability to minimize the renal dysfunction and injury associated with I/R injury.⁶

In recent years, there has been a dramatic expansion of knowledge about the pathophysiology of renal I/R injury. However, despite this growing body of research, the means by which clinicians can detect, prevent or treat I/R injury remain limited. Sound reproducible models of renal I/R are an important step in helping us to further understand the pathophysiology and treatment of this condition.⁷

Inhaled hydrogen gas was recently discovered to have antioxidant and antiapoptotic properties. A number of experimental and clinical studies have been initiated during previous years, resulting in accumulated evidence that hydrogen gas can protect organs against I/R injury by neutralizing ROS.⁸⁻¹²

To our knowledge, the protective effects of inhaled hydrogen gas in renal I/R injury have not been reported and remain largely unknown. In the present study, we hypothesized that hydrogen gas, at a safe concentration, could mitigate renal I/R injury. We used a I/R model in rats and tested this hypothesis with inhaled 2% hydrogen gas and kidney histopathology was assessed. We aimed to show the short- and long-term protective effects of hydrogen gas on I/R injury.

MATERIAL AND METHODS

SURGICAL TECHNIQUE AND GROUPS

Eight-week-old male Sprague-Dawley rats weighing 225 (202-246) g were used in the study. All rats were housed under standard conditions in a light-dark-cycle- and temperature-controlled environ-

ment with free access to food and water prior to and after the treatment protocol. All protocols conformed to the National Institute of Health (NIH) guidelines, with all rats receiving humane care in compliance with the Principles of Laboratory Animal Care. This study was approved by the ethical committee on animal research at our institution.

The rats were randomly divided into 3 major experimental groups. Subsequently, Group 2 and 3 were divided into subgroups as early (E) and late (L) periods (Group 1, sham; Group 2E and Group 2L, I/R; Group 3E and Group 3L, hydrogen-I/R). Intramuscular ketamine (40 mg/kg) and xylazine chloride (5 mg/kg) anesthesia were used during procedures. After shaving, the abdominal skin was disinfected with 70% alcohol and all procedures were performed under sterile conditions. A 5 cm midline laparotomy was performed, the left kidney was exposed, and the renal pedicle was bluntly dissected from underlying adipose tissue. Ischemia was induced by clamping the left pedicle for 45 min using atraumatic vascular microclamps. The left kidney was briefly observed for color change. The right kidney was not manipulated. The wound was temporarily sutured during the ischemic interval. At the end of the ischemic interval, the wound was reopened and the clamp was removed in order to reestablish blood flow to the left kidney. After clamp removal, the left kidney was inspected for restoration of blood flow. The surgical incision was sutured, and rats were allowed to recover.

Group 1, comprising the sham group (n= 6 rats), underwent exposure of renal pedicles but did not receive I/R. During sham operations, the left renal pedicle was explored and nephrectomy was performed. Group 2 (n= 12 rats) and 3 (n= 12 rats) were subjected to I/R. Group 3 comprised the hydrogen treatment group and treated with 2% hydrogen gas (2 L/min). Gas inhalation started 1 h before ischemia, continued during surgery and 1 h after reperfusion. Left nephrectomy was performed by the end of the six hours in the early groups and at 14th day of reperfusion in the late groups.

All rats were killed while anesthetized with thiopental sodium (40 mg/kg, intraperitoneal-i.p.)

after the surgical removal of the kidneys. The kidney was isolated, dissected coronally into two parts, and fixed over night in 10% formaldehyde at room temperature and processed for histological analysis.

HISTOLOGIC EVALUATION

For light microscopic investigations, paraffin-embedded samples were cut into 4- μ m sections with a microtome. Paraffin sections were stained with haematoxylin&eosin (H&E) and periodic acid-Schiff (PAS). Samples were blindly analyzed by a single pathologist who was unaware of groups.

Histopathological analysis was performed to evaluate and quantify tubular necrosis. Slides were examined under a light microscope (Olympus BX50, Olympus Co., Japan). Chronic tubular injury was defined by tubular atrophy with irregular thickening of the tubular basement membrane (stained by PAS; $\times 200$). The percentage of tubular necrosis in all kidneys was defined by brush border loss and desquamation of tubular epithelial cells, cellular debris in the tubular lumen with cast formation and tubular dilatation (revealed by H&E; $\times 20$). For purposes of quantitative analysis of histological pattern, tissue changes after I/R were ranked by scores that ranged from 0 to 4 (0=normal kidney, 0% injury; 1=minimal damage, <10% injury; 2=mild damage, 10-25% injury; 3=moderate damage, 26-75% injury; 4= severe damage, >75% injury).

STATISTICAL ANALYSIS

Data were expressed as median (min-max) values. The data were analyzed with Kruskal-Wallis analysis and the Mann-Whitney *U* test, and differences with a *p* value of less than 0.05 were considered statistically significant.

RESULTS

Light microscopy revealed normal kidney morphology in the sham group (Group 1) (Figure 1A). In contrast, kidneys from control rats (Group 2) exhibited significant injury characterized by marked histological changes characteristic of I/R injury in the outer medulla and cortex regions (Figure 1B, early groups; Figure 1C, late groups). These

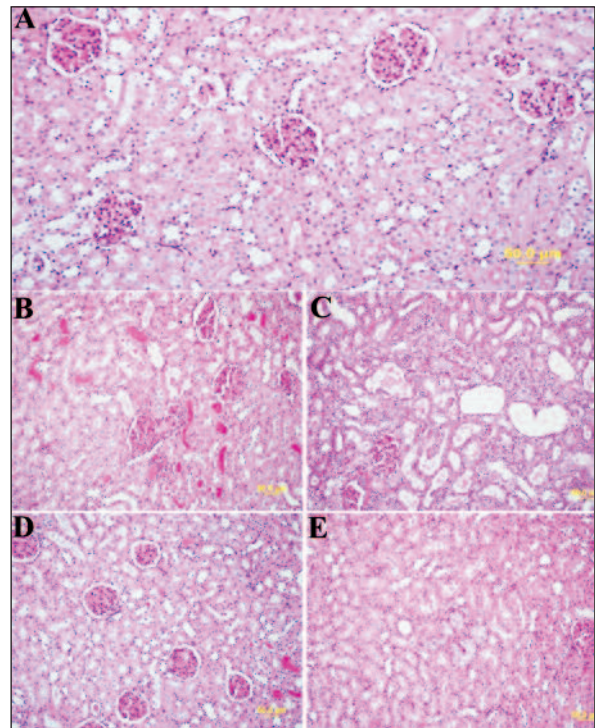


FIGURE 1: Pathological evaluation of rat kidneys ($\times 200$ magnification) (A). Representative Periodic acid-Schiff stained sections of rat kidneys showing normal morphology in the sham group (B, C). After ischemia/reperfusion (I/R), kidneys from rats in the control groups showed increased severe tubular necrosis, cellular sloughing, and cast formation. (D, E) I/R group treated with hydrogen gas.

(See color figure at <http://tipbilimleri.turkiyeklinikleri.com/>)

histopathological changes were characterized by widespread loss of brush border, tubular epithelial necrosis, tubular dilation, cellular sloughing and hyaline casts. These types of histological alterations were markedly reduced in specimens from the hydrogen-I/R group (Group 3) (Figure 1D, early groups; Figure 1E, late groups).

Histological changes were graded and showed in Figure 2. The median score values of the groups were 0.30 (range 0.07-0.61) for Group 1, 2.60 (range 1.65-3.32) for Group 2E, 2.80 (range 1.93-3.51) for Group 2L, 1.31 (range 1.11-1.75) for Group 3E, and 1.57 (range 0.92-2.39) for Group 3L.

All histological scores for renal injury were significantly higher in specimens from the I/R group (Group 2) compared to the sham group (Group 1), whereas intermediate scores were obtained in specimens from the hydrogen-I/R group (Group 3) ($p=0.001$) (Table 1).

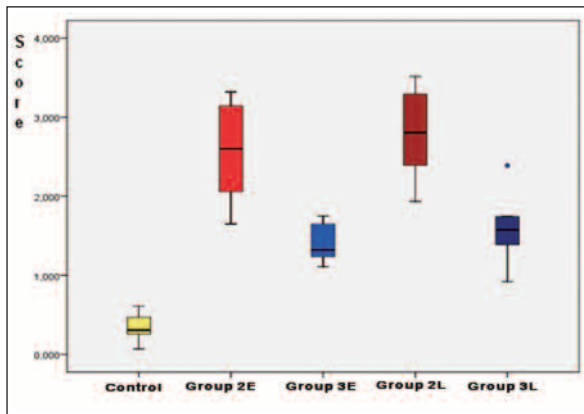


FIGURE 2: Scores of histopathological changes in groups.
(See color figure at <http://tipbilimleri.turkiyeklinikleri.com/>)

DISCUSSION

Although disparate mechanisms leading to tissue and organ dysfunction after I/R injury have been proposed, copious ROS, such as superoxide anion, hydrogen peroxide, and hydroxyl radicals, are generated at the time of vascular reperfusion and undoubtedly play important roles in the I/R process.¹³ Numerous studies suggest that ROS can cause direct cellular damage through protein oxidation and degradation, lipid peroxidation and DNA damage and lipid peroxidation is believed to be an important cause of the destruction and damage to cell structure and function.^{4,14-17} Oxidative stress-induced cell injury is not only mediated by increased ROS production, but also by a decreased antioxidant defense system.¹⁴ SOD is a class of enzymes that prevents damage from ROS during normal conditions by converting superoxide into hydrogen peroxide. However, I/R injury leads to a high production of ROS resulting in a rapid depletion of SOD and subsequent tissue injury.

Following I/R, morphological changes occur in the proximal tubules that are characterized by the loss of polarity, loss of the brush border, and redistribution of integrins and Na⁺/K⁺-ATPase to the apical surface. Calcium and ROS may also have a role in these morphological changes, in addition to subsequent cell death resulting from necrosis and apoptosis.¹⁸ As a result, both viable and nonviable cells are shed into the tubular lumen, resulting in formation of casts and luminal obstruction. In this study, we demonstrated that kidneys from control rats (Group 2) exhibit significant injury characterized by marked histological changes characteristic of I/R injury in the outer medulla and cortex regions.

The most important factor in the return of organ function appears to be the time of ischemia. It has been demonstrated in experimental studies that the maximum duration of warm ischemia, associated with complete recovery of renal function is 30 minutes, but some authors postulate that this time can be extended up to 90 minutes.¹⁹⁻²¹ In the present work the time of renal ischemia in the experimental model was 45 minutes.

Research efforts designed to prevent or ameliorate I/R injury have focused on the pharmacological inhibition of free radical injury. Antioxidants have been found to protect renal cells from cellular injury induced by I/R.²²⁻²⁴

The finding of the anti-oxidant effect of hydrogen and its therapeutic value led us to suggest that endogenous hydrogen may play an important physiological role in maintaining homeostasis. Several studies have shown that hydrogen exerts cytoprotective effects after various types of

TABLE 1: Comparison of the histological scores for renal injury.

Group	Group 1 median (min-max)	Group 2 median (min-max)	Group 3 median (min-max)	p
Early period	0.30 (0.07-0.61)	2.60 (1.65-3.32)	1.31 (1.11-1.75)	G1-G2 0.004 G1-G3 0.004 G2-G3 0.006
Late period		2.80 (1.93-3.51)	1.57 (0.92-2.39)	G1-G2 0.004 G1-G3 0.004 G2-G3 0.006

injuries.⁸⁻¹¹ For this reason in this study we hypothesized that hydrogen, could mitigate renal I/R injury.

It is generally accepted that hydrogen is a gas with reducing reactivity. In radiochemistry, hydrogen reacts directly with hydroxyl radicals. However, in the field of biological medicine, hydrogen has always been considered to be physiologically inert gas and it is often used in diving medicine. However, recent studies have demonstrated that hydrogen is also a potent anti-oxidative and anti-inflammatory agent with potential for medical application, particularly given that hydrogen treatment effectively protects cells, tissues and organs against oxidative injury.²⁵ Hydrogen may scavenge or mitigate excessive free radicals and maintain them at basal physiological levels, like most other endogenous antioxidants. High levels of free radicals are produced in the body under ischemic, inflammatory or other pathological conditions, resulting in oxidative damage to cells and tissues. The anti-oxidant capacity of tissues is relatively low under these conditions and hydrogen treatment may increase this capacity, balancing out the oxidation state and thus protecting cells, tissues and organs against oxidative injury and restoring physiological function. In this study, histological alterations were markedly reduced and all histological scores for renal injury were significantly lower in specimens from the hydrogen-I/R group compared to the control group, ($p=0.001$). This observation supports the suggesting that hydrogen gas ameliorates damage induced by I/R.

Medical gas therapy is a novel and relatively unexplored field of science, and to our knowledge, hydrogen inhalation therapy has never been tested in any model of renal I/R injury. Clinically, hydrogen gas therapy could be delivered by a variety of systems including, simple inhalation using a ventilator circuit, a face mask or a nasal cannula.²⁵ In addition, hydrogen gas therapy could be administered via a parental hydrogen-releasing moiety and/or a hydrogen enriched fluid.²⁶ There is evidence that inhaled hydrogen gas has anti-oxidant and antiapoptotic properties to protect organs against IR

induced injury.⁸ Inhalation of hydrogen acts rapidly, because hydrogen diffuses immediately into tissues. Furthermore, it has been reported that inhaled hydrogen gas has antioxidant and antiapoptotic properties that can protect the brain and liver against I/R injury by selectively neutralizing hydroxyl radicals.^{8,9} Therefore, in this study, we tested our hypothesis with inhaled 2% hydrogen gas therapy.

However, hydrogen gas is highly flammable and burns in the air over a wide concentration range (4-75% by volume in air). Hydrogen gas mixtures can be detonated by sparks, heat or sunlight and hydrogen gas leaking into the air may ignite spontaneously. Moreover, extremely hot hydrogen fire is almost invisible, which may result in accidental burns.²⁶ The concentration of gaseous molecular hydrogen used in the studies (approximately 4%) is lower than the threshold at which it is known to be flammable in air (4.6%).⁸ We used 2% hydrogen gas for this study and did not see any adverse effects. Because hydrogen has no risk of explosion at concentrations less than 4%.²⁶

Several limitations of our study should be noted. First, because of the technical deficiencies we have not studied markers of TNF- α , 4-hidroksinonenal (4-HNE), which are very important to identify I/R injury. Second, our rat model of renal I/R injury is not entirely analogous to clinical I/R conditions seen in patients. Third, we have neither established serum hydrogen levels nor its safety for long-term administration. We know that the balance between oxidation and anti-oxidation is important. Even though we consider hydrogen resuscitation as a safe treatment, over resuscitation may worsen the damage. Thus, we need to know more about the dose effects and side-effects of hydrogen gas, especially in humans.

CONCLUSION

In this study, we demonstrated that hydrogen gas significantly attenuated renal I/R injury in early and late periods, maintaining tissue structure, potentially through an antioxidant effect in a rat

model. Taken together, our findings are in line with published results which show that hydrogen has a protective effect against I/R induced organ dysfunction and may have therapeutic potential against various clinical conditions involving I/R injury. Further investigations are needed to establish

the feasibility and efficacy of hydrogen gas in clinical renal I/R settings.

Acknowledgment

We are very grateful to Dr. Erhan Cetin CETİNOĞLU for statistical help.

REFERENCES

- Perico N, Cattaneo D, Sayegh MH, Remuzzi G. Delayed graft function in kidney transplantation. *Lancet* 2004;364(9447):1814-27.
- Sharples EJ, Thiemermann C, Yaqoob MM. Mechanisms of disease: Cell death in acute renal failure and emerging evidence for a protective role of erythropoietin. *Nat Clin Pract Nephrol* 2005;1(2):87-97.
- Lameire N, Vanholder R. Pathophysiologic features and prevention of human and experimental acute tubular necrosis. *J Am Soc Nephrol* 2001;12(Suppl 17):S20-32.
- Nath KA, Norby SM. Reactive oxygen species and acute renal failure. *Am J Med* 2000; 109(8):665-78.
- Ho YS, Magnenat JL, Gargano M, Cao J. The nature of antioxidant defense mechanisms: a lesson from transgenic studies. *Environ Health Perspect* 1998;106 (Suppl 5):1219-28.
- Yin M, Wheeler MD, Connor HD, Zhong Z, Bunzendahl H, Dikalova A, et al. Cu/Zn-superoxide dismutase gene attenuates ischemia-reperfusion injury in the rat kidney. *J Am Soc Nephrol* 2001;12(12):2691-700.
- Dursun B. [Ischemic acute kidney injury models]. *Turkiye Klinikleri J Nephrol-Special Topics* 2010;3(3):1-10.
- Ohsawa I, Ishikawa M, Takahashi K, Watanabe M, Nishimaki K, Yamagata K, et al. Hydrogen acts as a therapeutic antioxidant by selectively reducing cytotoxic oxygen radicals. *Nat Med* 2007;13(6):688-94.
- Fukuda K, Asoh S, Ishikawa M, Yamamoto Y, Ohsawa I, Ohta S. Inhalation of hydrogen gas suppresses hepatic injury caused by ischemia/reperfusion through reducing oxidative stress. *Biochem Biophys Res Commun* 2007;361(3):670-4.
- Cai J, Kang Z, Liu WW, Luo X, Qiang S, Zhang JH, et al. Hydrogen therapy reduces apoptosis in neonatal hypoxia-ischemia rat model. *Neurosci Lett* 2008;441(2):167-72.
- Hayashida K, Sano M, Ohsawa I, Shinmura K, Tamaki K, Kimura K, et al. Inhalation of hydrogen gas reduces infarct size in the rat model of myocardial ischemia-reperfusion injury. *Biochem Biophys Res Commun* 2008;373(1): 30-5.
- Buchholz BM, Kaczorowski DJ, Sugimoto R, Yang R, Wang Y, Billiar TR, et al. Hydrogen inhalation ameliorates oxidative stress in transplantation induced intestinal graft injury. *Am J Transplant* 2008;8(10):2015-24.
- Land WG. The role of postischemic reperfusion injury and other nonantigen-dependent inflammatory pathways in transplantation. *Transplantation* 2005;79(5):505-14.
- Thadhani R, Pascual M, Bonventre JV. Acute renal failure. *N Engl J Med* 1996;334(22): 1448-60.
- Paller MS. The cell biology of reperfusion injury in the kidney. *J Investig Med* 1994;42(4): 632-9.
- Eum HA, Lee SM. Effects of Trolox on the activity and gene expression of cytochrome P450 in hepatic ischemia/reperfusion. *Br J Pharmacol* 2004;142(1):35-42.
- Avunduk MC, Yurdakul T, Erdemli E, Yavuz A. Prevention of renal damage by alpha-tocopherol in ischemia and reperfusion models of rats. *Urol Res* 2003;31(4):280-5.
- Akbas H, Ozden M, Kanko M, Maral H, Bulbul S, Yavuz S, et al. Protective antioxidant effects of carvedilol in a rat model of ischaemia-reperfusion injury. *J Int Med Res* 2005;33(5): 528-36.
- Humphreys MR, Castle EP, Lohse CM, Sebo TJ, Leslie KO, Andrews PE. Renal ischemia time in laparoscopic surgery: an experimental study in a porcine model. *Int J Urol* 2009;16(1):105-9.
- Baldwin DD, Maynes LJ, Berger KA, Desai PJ, Zuppan CW, Zimmerman GJ, et al. Laparoscopic warm renal ischemia in the solitary porcine kidney model. *Urology* 2004;64(3): 592-7.
- Orvieto MA, Tolhurst SR, Chuang MS, Lyon MB, Ritch CR, Rapp DE, et al. Defining maximal renal tolerance to warm ischemia in porcine laparoscopic and open surgery model. *Urology* 2005;66(5):1111-5.
- Giovannini L, Migliori M, Longoni BM, Das DK, Bertelli AA, Panichi V, et al. Resveratrol, a polyphenol found in wine, reduces ischemia reperfusion injury in rat kidneys. *J Cardiovasc Pharmacol* 2001;37(3):262-70.
- Rhoden EL, Pereira-Lima L, Telöken C, Lucas ML, Belló-Klein A, Rhoden CR. Beneficial effect of alpha-tocopherol in renal ischemia-reperfusion in rats. *Jpn J Pharmacol* 2001;87(2): 164-6.
- Seth P, Kumari R, Madhavan S, Singh AK, Mani H, Banaudha KK, et al. Prevention of renal ischemia-reperfusion-induced injury in rats by picroliv. *Biochem Pharmacol* 2000;59(10): 1315-22.
- Huang CS, Kawamura T, Toyoda Y, Nakao A. Recent advances in hydrogen research as a therapeutic medical gas. *Free Radic Res* 2010;44(9):971-82.
- Zheng XF, Sun XJ, Xia ZF. Hydrogen resuscitation, a new cytoprotective approach. *Clin Exp Pharmacol Physiol* 2011;38(3): 155-63.