

# Warfarin-Induced Chest Wall and Breast Hematoma in an Elderly Female Patient with Atrial Fibrillation: Original Image

## Warfarine Bağlı Göğüs Duvarı ve Memede Hematom Gelişen Atriyal Fibrilasyonlu Yaşlı Bayan Hasta

Bülent ÖZDEMİR, MD,<sup>a</sup>  
Ahmet Sami BAYRAM, MD,<sup>b</sup>  
Naile BOLCA, MD,<sup>c</sup>  
Ethem KUMBAY, MD<sup>a</sup>

<sup>a</sup>Department of Cardiology,  
<sup>b</sup>Department of Thoracic Surgery,  
<sup>c</sup>Department of Radiology,  
Uludağ University, Faculty of Medicine  
Bursa

Geliş Tarihi/Received: 28.05.2008  
Kabul Tarihi/Accepted: 21.08.2008

Yazışma Adresi/Correspondence:  
Bülent ÖZDEMİR, MD  
Uludağ University,  
Faculty of Medicine,  
Department of Thoracic Surgery,  
Bursa,  
TÜRKİYE/TURKEY  
asbayram2@yahoo.com

**ABSTRACT** Atrial fibrillation is the most common sustained cardiac rhythm disorder. Current treatment guidelines recommend long-term oral anticoagulation with a vitamin K antagonist, such as warfarin, in patients with atrial fibrillation who are at moderate to high risk of stroke. Bleeding is a common side effect of warfarin. The risk of severe bleeding is a small but definite (1-2% annually) result of warfarin use. Risk of bleeding is augmented if the international normalization ratio (INR) is high. We presented a case with warfarin induced chest wall and breast hematoma, which is a rare condition.

**Key Words:** Warfarin; hematoma

**ÖZET** Atriyal fibrilasyon (AF) en sık görülen inatçı nitelikte ki kardiyak ritim hastalığıdır. AF'nin tedavisine yeni yaklaşımda; özellikle orta dereceden yüksek dereceye kadar felç riski olan AF'li hastalarda warfarin gibi vitamin K antagonisti oral antikoagülanların uzun süre kullanımı tavsiye edilir. Warfarin kullanımına bağlı kanama görülme riski düşük olmakla beraber kanama olduğu zaman bu hayatı tehdit edecek düzeydedir (yıllık %1-2). Kanama riski eğer INR yüksekse daha ciddi boyutlara ulaşır. Warfarine bağlı göğüs duvarı ve memede hematom gelişmesi nadir bir durum olduğu için bu olgu sunumunda warfarine bağlı göğüs duvarı ve memede hematom gelişen bir olguyu sunmayı uygun gördük.

**Anahtar Kelimeler:** Warfarin; hematom

**Türkiye Klinikleri J Med Sci 2008;28(6):992-4**

**A**trial fibrillation (AF) is the most common sustained cardiac rhythm disorder. AF is a strong, independent risk factor for stroke because it leads to formation and embolism of thrombi in the left atrial appendage.<sup>1</sup> Current treatment guidelines recommend long-term oral anticoagulation with a vitamin K antagonist, such as warfarin, in patients with AF who are at moderate to high risk of stroke.<sup>2</sup> Several major risk factors for bleeding with warfarin have been identified, including uncontrolled anticoagulation, recent hemorrhage, liver and kidney disease, concomitant use of aspirin and non-steroidal anti-inflammatory agents, uncontrolled hypertension and non-Caucasian origin.<sup>3</sup> In this report, we presented a case with warfarin-induced chest wall and breast hematoma.

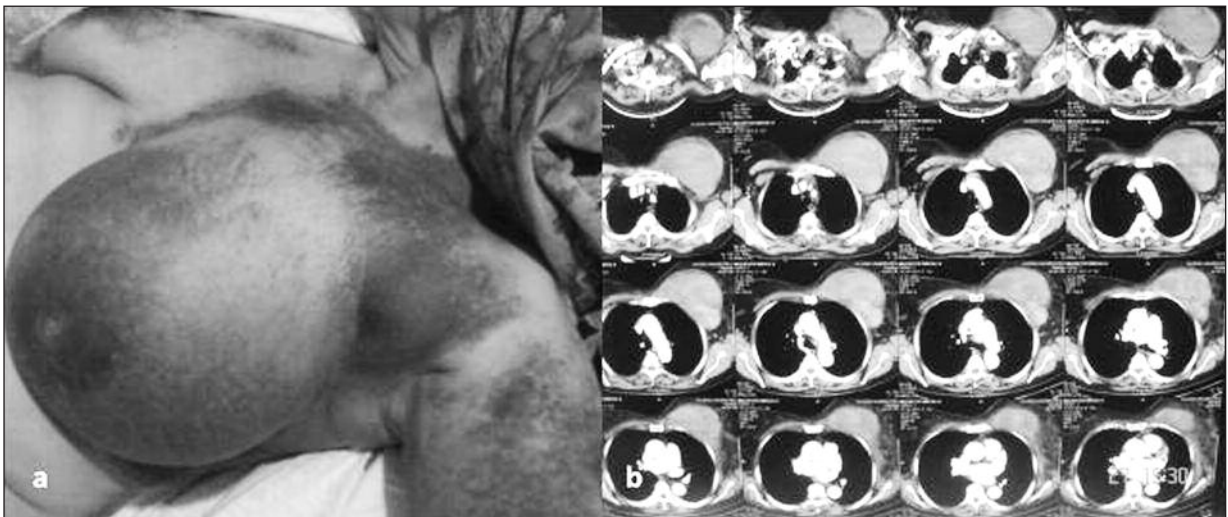A 74-years-old female patient with AF for 10 years was admitted to our clinic. She has had hypertension for 10 years. The anticoagulation the-

rapy of the patient had started 3 weeks ago. At physical examination, the breast was swollen and tender. Swelling and a purple-red discoloration of the left breast, sternum, part of the right breast and left axilla was evident on inspection (Figure 1a). The hematoma caused pain and limited the activity of the patient and she was uncomfortable particularly when lying down. The hemoglobin level was 7.1 g/dL and the hematocrit level was 20%. The activated partial thromboplastin time was 106 sec (normal values were in the range of 20-31 sec) and the international normalization ratio (INR) was too high to be measured by the device. Her liver and renal function tests were within normal limits. She received 3 units of erythrocyte suspension and the hemoglobin level increased to 10.4 g/dL. An ultrasonographic examination revealed different phases of bleeding with multiple loci of hematoma in the thoracic wall and the breast. The largest hematoma was localized in the anterior thoracic wall under the left breast and its dimensions were 126 x 73 mm. In order to obtain detailed view of the hematomas and possible intra-thoracic bleeding, a thorax computerized tomography (CT) was performed. A large hematoma under the left breast was clearly visible in the CT images (Figure 1b). During her stay, the INR levels returned to normal with administration of vitamin K and 4 units of fresh frozen plasma. Then she was operated with a left supra-

mammarian incision and 600 mL of coagulum was evacuated from the thoracic wall hematoma and the left breast. She was left with a hemovac drain and the clinic was uneventful. She had a control thoracic CT that revealed no collections in the postoperative period and in the physical examination, the swelling had disappeared (Figure 2a and 2b). The hemovac drain was removed and she was discharged after discontinuation of oral anticoagulant therapy.

Warfarin inhibits the synthesis of biologically active forms of the vitamin K-dependent clotting factors II, VII, IX and X, as well as the regulatory factors protein C, protein S, and protein Z. Bleeding is a common side effect of warfarin. The risk of severe bleeding is small but definite (1-2% annually) and any benefit needs to outweigh this risk when warfarin is considered as a therapeutic measure. Risk of bleeding is augmented if the INR is high. Concomitant use of warfarin with antiplatelet drugs such as aspirin or nonsteroidal anti-inflammatory drugs increases the risk of hemorrhage. The risk is also increased in the elderly patients.

Warfarin therapy can be given temporarily or for life long. Patients on warfarin must have regular laboratory monitoring for prothrombin time (PT) and INR. PT is a test to determine the time needed for blood to clot by measuring the activity of clotting factors I, II, V, VII, and X.



**FIGURE 1:** a. Swelling and a purple-red discoloration of the left breast, sternum, part of the right breast, left axilla, b. The large hematoma under the left breast on CT.

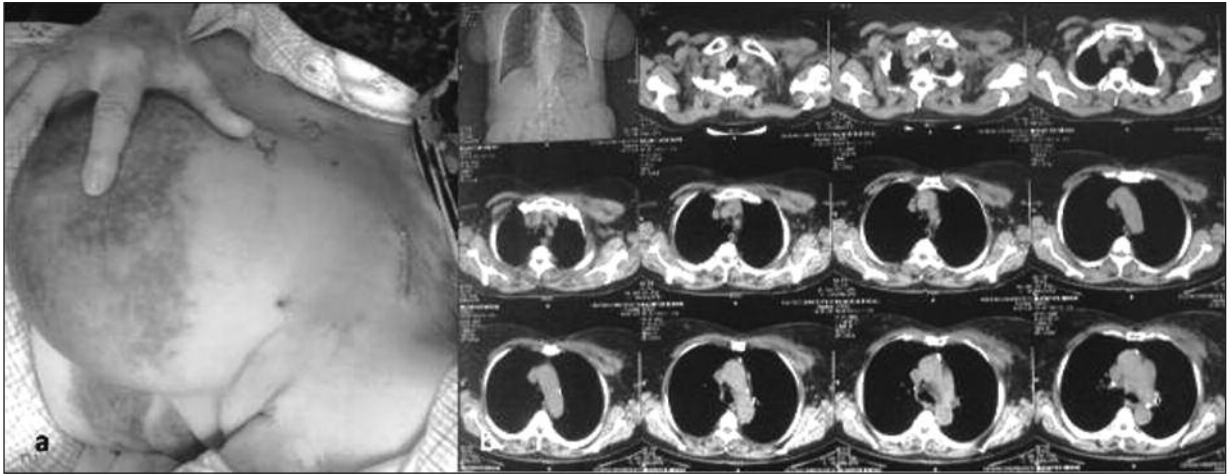


FIGURE 2: a. Postoperative appearance of patient b. Control thoracic CT that revealed no collections in the postoperative period .

Finh et al found that the most common risk factors for warfarin-associated bleeding included an INR between 4.6 and 5.3 or greater, variability in readings, a shorter duration of anticoagulation therapy (3 months or less), and the presence of 3 or more comorbid conditions, such as hypertension, diabetes, or peptic ulcer disease.<sup>4</sup>

In our case, the bleeding was due to high INR possibly because of nonadherence to prescriptions and a short duration of therapy as stated above. Initiating anticoagulation therapy needs higher attention for both the physician and the patient. The patient should be encouraged and feel ready to pay regular and frequent visits. In addition, patient education should be a major target.

Breast hematoma without a history of recent trauma is rare. It may be observed in patients with thrombocytopenia or coagulation disorder or it may occur in patients who take anticoagulant medicati-

on. The resultant edema of hemorrhage causes a palpable mass or a located dense image. It can stimulate or hide a carcinoma, necessitating a complete investigation.<sup>5</sup> In this case, definitive diagnosis is usually made based on large swelling, tenderness, purple-red discoloration of the skin and patient history without any need for further imaging techniques. However, in our patient, hematoma was predominantly in the thoracic wall and caused additional swelling that included the axillary region. The hematoma was just beneath the mammary gland and it extended in this area. The bleeding was massive to require erythrocyte transfusion and surgery.

In conclusion, close follow-up in elderly patients and at the onset of warfarin therapy due to higher risk of bleeding in such conditions. Hematoma should be considered in patients with a swelling and discoloration, especially in those using antithrombotic and anticoagulant therapy.

## REFERENCES

1. Lamassa M, Di Carlo A, Pracucci G, Basile AM, Trefoloni G, Vanni P, et al. Characteristics, outcome, and care of stroke associated with atrial fibrillation in Europe: data from a multicenter multinational hospital-based registry (The European Community Stroke Project). *Stroke* 2001;32:392-8.
2. Singer DE, Albers GW, Dalen JE, Go AS, Halperin JL, Manning WJ. Antithrombotic therapy in atrial fibrillation: the Seventh ACCP Conference on Antithrombotic and Thrombolytic Therapy. *Chest* 2004;126(3 Suppl):429S-56S.
3. Hylek EM, Evans-Molina C, Shea C, Henault LE, Regan S. Major hemorrhage and tolerability of warfarin in the first year of therapy among elderly patients with atrial fibrillation. *Circulation* 2007;115:2689-96.
4. Fihn SD, McDonell M, Martin D, Henikoff J, Ver-
5. Kanegusuku MS, Rodrigues D, Urban LA, Romanus AB, Pimenta RP, De Assis MG, et al. Recurrent spontaneous breast hematoma: report of a case and review of the literature. *Rev Hosp Clin Fac Med Sao Paulo* 2001;56:179-82.