

Invasive Breast Carcinoma Occuring Within Fibroadenoma: Case Report

Fibroadenomadan Gelişen İnvaziv Meme Kanseri

Özgür DANDİN,^a
Dursun Özgür KARAKAŞ,^b
Ahmet Ziya BALTA,^c
Batuhan HAZER,^b
Tuncer ERGİN^d

Clinics of

^aGeneral Surgery,

^dRadiology

Bursa Military Hospital, Bursa,

^bClinic of General Surgery,

Kasımpaşa Military Hospital,

^cClinic of General Surgery,

Gülhane Military Medical Academy Haydarpaşa Training Hospital, İstanbul

Geliş Tarihi/Received: 03.10.2013

Kabul Tarihi/Accepted: 23.02.2014

Yazışma Adresi/Correspondence:

Dursun Özgür KARAKAŞ

Kasımpaşa Military Hospital,

Clinic of General Surgery, İstanbul,

TÜRKİYE/TURKEY

drdok1978@hotmail.com

ABSTRACT Fibroadenomas are the most common benign tumors of the breast. Carcinomas occurring within fibroadenoma are very rare. Fibroadenomas present in approximately 10% of women at autopsy, also occurs 20% of all the benign breast mass and usually identified as circumscribed masses at physical examination or mammography. The most common histologic type is lobular carcinoma in situ, followed by ductal carcinoma in situ, invasive ductal carcinoma and invasive lobular carcinoma. Positive family history, complex fibroadenomas, proliferative disease adjacent fibroadenomas and BRCA mutation are the risk factors for malign transformation within fibroadenomas. Histopathological examination should be performed routinely to rule out malignancy because of no definitive clinical or radiological criteria for diagnosing carcinoma occurring within fibroadenoma. We presented a case of invasive breast carcinoma occurring within fibroadenoma.

Key Words: Fibroadenoma; carcinoma, ductal; carcinoma, lobular

ÖZET Fibroadenomalar memenin en sık benign tümörleridir. Fibroadenomadan kanser gelişimi oldukça nadirdir. Fibroadenoma, genellikle fizik muayene ve mamografide sınırlı kitleler olarak tanımlanıp, kadınların otopsisinde yaklaşık %10 oranında saptanırken tüm iyi huylu meme kitlelerinin % 20'sini oluşturur. En sık görülen histolojik tip lobular karsinoma in situ'dur, bunu duktal karsinoma in situ, invaziv duktal karsinom, invazif lobüler karsinom takip eder. Pozitif aile öyküsü, karmaşık fibroadenomalar, fibroadenomaya komşu proliferatif hastalık ve BRCA mutasyonu fibroadenomanın malign transformasyonu için risk faktörleridir. Fibroadenomadan karsinom gelişiminin tanısında kesin bir klinik ve radyolojik kriter olmadığından maligniteyi dışlamak için histopatolojik değerlendirme yapılmalıdır. Burada fibroadenomadan gelişen invaziv meme kanserli bir olguyu sunmaktayız.

Anahtar Kelimeler: Fibroadenom; karsinom, duktal; karsinom, lobüler

Türkiye Klinikleri J Case Rep 2015;23(2):149-52

Fibroadenomas are the benign tumours of the breast.¹⁻⁴ They are the second most common tumours of the breast after carcinoma and the most common benign tumours of the breast in adolescent girls and young women.^{1,3} Malignant transformation of fibroadenoma to carcinoma is very rare (equal or less than 0.5%), and the mean age is fifth decade.^{2,4-7} The most common malignant histologic type coexistence with fibroadenoma is lobular carcinoma in situ (66.9%), followed by ductal carcinoma in situ (12.4%), invasive ductal carcinoma (11%), and invasive lobular carcinoma (3.4%).⁴ Positive family history, complex fibroadenomas, proliferative disease adjacent fibroadenomas and BRCA mutation are associated with

doi: 10.5336/caserep.2013-37780

Copyright © 2015 by Türkiye Klinikleri

fibroadenomas mild increase risk of subsequent breast cancer.⁸ Histopathological examination should be performed routinely to rule out malignancy because of no definitive clinical or radiological criteria for diagnosing carcinoma occurring within fibroadenoma.⁶ We presented a case of invasive carcinoma of the breast that occurring within fibroadenoma.

CASE REPORT

A thirty-five year old woman was applied with well defined palpable mass in the upper outer quadrant of the left breast, that was presented one and a half month. She was pre-menopausal and there was no family history of cancer, no history of trauma or previous surgery. A mobile palpable mass with an oval shape (fibroadenoma?), no palpable axillary lymph node was revealed at physical examination. A 10x14 mm irregular countoured, heterogeneous hypoechoic mass with fibrotic shrinkage around was reported at ultrasonography (USG) (Figure 1). Invasive ductal carcinoma reported at incisional biopsy. There was no distant metastasis in thoraco-abdominal computerized tomography and whole body bone sintigraphy. A left breast-conserving mastectomy and axillar dissection was performed. A mixed invasive carcinoma (ductal component 90%, lobular component 10%) within fibroadenoma was reported at microscopic

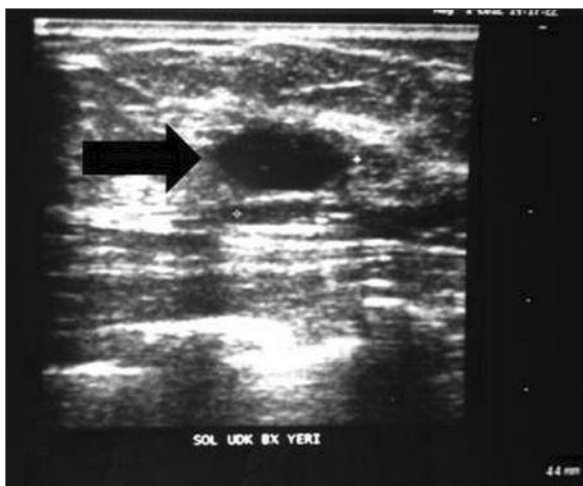

FIGURE 1: Ultrasonography of breast shows a heterogeneous hypoechoic mass measuring 10x14 mm with irregular contours which had fibrotic shrinkage around.

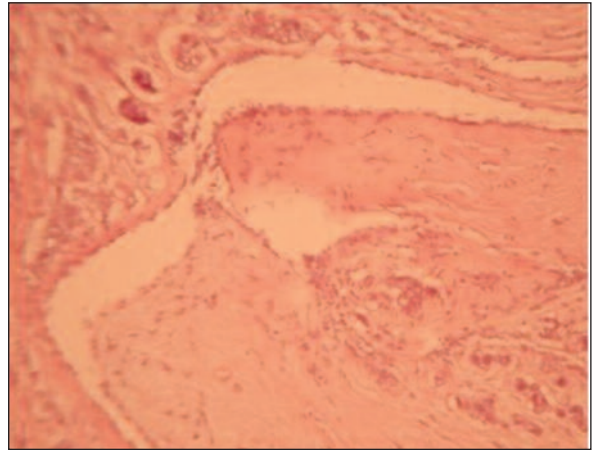


FIGURE 2: x100 microscopic magnification of hematoxylin-eosin stained whole mounted section from the fibroadenoma. In addition to classical fibroadenomatoid areas, an invasive ductal and lobular carcinoma were also present.

examination (Figure 2). Tumour was patchy foci independent from each other, in an area of 1.8 cm in diameter. Lobular components were not in the fibroadenoma. Also ductal carcinoma in situ (DCIS) was diffuse. Tumour was negative for estrogen receptor, positive for progesterone receptor (90%), positive for E-cadherin immunostaining and Her2/neu score was 1. There was no metastasis to the harvested 11 axillary lymph nodes. Her post-operative recovery was uneventful. Also adjuvant chemotherapy was planned after primary treatment. Postoperative follow up at the sixth month was normal.

DISCUSSION

Invasive ductal carcinoma is the most common malignant breast cancer with 70-80% rate. Invasive lobular carcinoma, inflammatory carcinoma, tubular carcinoma, medullary carcinoma, mucinous carcinoma are the less common malignant cancers respectively. Fibroadenomas are the most common benign breast tumors in adolescent and young women with incidence of 7-13% and usually with a single breast mass.^{1,3,5,7,9,10,11} Fibroadenomas occur as a result of an abnormal proliferation and involution of the breast because of hormonal fluctuations and are not really neoplastic. Fibroadenomas are biphasic tumours characterized by both stromal

and epithelial proliferation.^{7,10} Carcinoma occurring within a fibroadenoma is a very rare condition.^{1,3,5} The incidence of carcinoma occurring within fibroadenoma is between 0.1–0.3%, and mean age is 44 years (range from 15 to 83 years) and higher from single fibroadenoma.^{1,3} The age of our case is compatible with literature.

There are many theories for explaining to malignant transformation or carcinoma occurring within fibroadenomas. These theories includes (1) delay in removing the fibroadenoma may be a cause of the subsequent growth of an in-situ malignant neoplasm, (2) the two lesions, the benign and the malignant, occur independently of each other, and (3) as Azzopardi et. al. suggested that carcinoma arising in an adjacent breast tissue engulfing or infiltrating a fibroadenoma or carcinoma in the crevices of a fibroadenoma as well as in the adjacent breast tissue or carcinoma restricted entirely, or at least dominantly, to a fibroadenoma as well as in the adjacent breast tissue.^{7,11}

Ultrasonography seems more useful than mammography or magnetic resonance imaging (MRI) because of performing easily, non-invasively and repeatedly at fibroadenomas imaging. Fibroadenoma is seen as an oval or lobulated mass with a circumscribed margin, homogeneous hypoechoic and a relatively low depth:width ratio at USG typically. Doppler USG often shows marginal vascularities surrounding the mass, and slightly increased vascularity in fibroadenomas is different from cancers from the vascular infiltration into the mass.¹ The mammographic features of carcinoma originating within a fibroadenoma include round, oval or lobulated mass, margin irregularity, suspicious linear or pleomorphic calcifications.¹² Fibroadenomas are seen as a focal round or oval shaped mass with smooth margins at MRI.¹² In our case radiologic imaging was reported as irregular countoured, heterogeneous hypoechoic mass with fibrotic shrinkage around at USG.

Fine needle aspiration cytology (FNAC), core nuclear biopsy (CNB) are not always sufficient for excluding malignancy because of the heterogeneity of the lesion in benign breast tumours or mass that

are at risk of developing cancer open biopsy is often mandatory.¹ The detection of malignancy occurring within a fibroadenoma can be difficult.^{2,10} Although malignant transformation of a fibroadenoma is very rare, fibroadenoma in a woman with a positive family history may have greater clinical importance than fibroadenoma occurring in a woman with no additional risk factors.^{1,3,6,10} Fibroadenomas observed cysts, sclerosing adenosis, epithelial calcifications or papillary apocrine changes. These are classified as complex and a long-term risk factor for breast cancer.^{1,3,10} Positive family history, complex fibroadenomas, proliferative disease adjacent fibroadenomas and BRCA mutation are important risks for carcinoma occurring within fibroadenomas.⁸

The most common histologic type is lobular carcinoma in situ (66.9%), followed by ductal carcinoma in situ (12.4%), invasive ductal carcinoma (11%), and invasive lobular carcinoma (3.4%). Other types of carcinomas are very uncommon.⁴ The higher incidence of lobular carcinoma may be cause of the common origin of the epithelial components of both the fibroadenoma and the lobular carcinoma.⁴ There is a few literature knowledge about the status of receptor positivity.⁴ Axillary lymph node metastasis vary from 6,25–7,7%.⁴ In our case pathology was reported as a mixed invasive carcinoma (ductal component 90%, lobular component 10%) within fibroadenoma.

Carcinomas occurring within fibroadenoma act similar as regular breast cancer, so there is no difference in the treatment modality.² The surgical treatment is depend on the stage and the presence of axillary or distant metastasis. Breast conservative surgery like as lumpectomy or wide local excision with or without axillary lymph node dissection can be selected if the tumor is small or modified radical mastectomy with axillar dissection can be selected for greater tumors or patient's willingness.^{6,13} Follow up of both the breasts is recommended because of the high incidence of contralateral breast cancer.¹⁴

In conclusion; although carcinomas occurring within fibroadenoma are rare conditions, histopatho-

logical examination should be performed routinely to rule out malignancy because of no definitive clinical or radiological criteria for diagnosing carcinoma occurring within fibroadenoma in women older than 35 years for changing diameter or echogenity of fi-

broadeomas. It should be kept in mind that positive family history, complex fibroadenomas, proliferative disease adjacent fibroadenomas and BRCA mutation are the risk factors for malign transformation within fibroadenomas.

REFERENCES

- Ooe A, Takahara S, Sumiyoshi K, Yamamoto H, Shiba E, Kawai J. Preoperative diagnosis of ductal carcinoma in situ arising within a mammary fibroadenoma: a case report. *Jpn J Clin Oncol* 2011;41(7):918-23.
- Rao S, Latha PS, Ravi A, Thanka J. Ductal carcinoma in a multiple fibroadenoma: diagnostic inaccuracies. *J Cancer Res Ther* 2010; 6(3):385-7.
- Abu-Rahmeh Z, Nseir W, Naroditzky I. Invasive ductal carcinoma within fibroadenoma and lung metastases. *Int J Gen Med* 2012; 5:19-21.
- Abe H, Hanasawa K, Naitoh H, Endo Y, Tani T, Kushima R. Invasive ductal carcinoma within a fibroadenoma of the breast. *Int J Clin Oncol* 2004;9(4):334-8.
- Tajima S, Kanemaki Y, Kurihara Y, Okamoto K, Shimamoto H, Okazaki H, et al. A case of a fibroadenoma coexisting with an invasive lobular carcinoma in the breast. *Breast Cancer* 2011;18(4):319-23.
- Chintamani, Khandelwal R, Tandon M, Yashwant K, Kulshreshtha P, Aeron T, et al. Carcinoma developing in a fibroadenoma in a woman with a family history of breast cancer: a case report and review of literature. *Cases J* 2009;2:9348. doi: 10.1186/1757-1626-2-9348.
- Charfi L, Mrad K, Sellami R, Driss M, Sassi S, Abbes I, et al. Invasive mucinous carcinoma arising within breast fibroadenoma. *Pathologica* 2008;100(3):199-201.
- Dupont WD, Page DL, Parl FF, Vnencak-Jones CL, Plummer WD Jr, Rados MS, et al. Long-term risk of breast cancer in women with fibroadenoma. *N Engl J Med* 1994;331(1):10-5.
- Ellis IO, Elston CW. Histologic grade. In: O'Malley FP, Pinder SE, eds. *Breast Pathology*. 1st ed. Philadelphia: Churchill Livingstone; 2006. p.225-33.
- Kuijper A, Preisler-Adams SS, Rahusen FD, Gille JJ, van der Wall E, van Diest PJ. Multiple fibroadenomas harbouring carcinoma in situ in a woman with a family history of breast/ovarian cancer. *J Clin Pathol* 2002;55(10): 795-7.
- Azzopardi JG, Ahmed A, Millis RR. Problems in breast pathology. *Major Probl Pathol* 1979; 11:i-xvi, 1-466.
- Kato F, Omatsu T, Matsumura W, Takahashi M, Hosoda M, Takahashi H, et al. Dynamic MR findings of ductal carcinoma in situ within a fibroadenoma. *Magn Reson Med Sci* 2011; 10(2):129-32.
- Pick PW, Iossifides IA. Occurrence of breast carcinoma within a fibroadenoma. A review. *Arch Pathol Lab Med* 1984;108(7):590-4.
- Goldman RL, Friedman NB. Carcinoma of the breast arising in fibroadenomas, with emphasis on lobular carcinoma. A clinicopathologic study. *Cancer* 1969;23(3):544-50.