





Huge Complex Odontoma and Treatment

Büyük Kompleks Odontoma ve Tedavisi

 Kübra ÖZTÜRK^a,
 Ertan DELİLBAŞI^a,
 Sevil KAHRAMAN^a,
 Tolga KODAZ^a

^aDepartment of Oral and Maxillofacial Surgery, Gazi University Faculty of Dentistry, Ankara, TURKEY

Received: 02.01.2018

Accepted: 17.04.2018

Available online: 28.02.2019

Correspondence:

Kübra ÖZTÜRK

Gazi University Faculty of Dentistry, Department of Oral and Maxillofacial Surgery, Ankara, TURKEY/TÜRKİYE
 kbrotur89@gmail.com

ABSTRACT Odontomas are the most common benign tumors of odontogenic origin. Due to the absence of symptoms, they are usually diagnosed on routine radiographs. Odontomas are divided based on their radiographic, clinical and histological features; compound odontoma and complex odontoma. The region can be reconstructed according to the destruction area of these lesions. Large bone defect in the jaw bone is usually reconstructed with autogenous bone graft from extraoral donor sites. In such cases, anterior iliac grafts are preferred most frequently. We reported 32-year-old man was referred to the Department of Oral and Maxillofacial Surgery, asymmetry with the facial swelling in the region of the posterior right maxilla. The first diagnostic hypothesis was complex odontoma. In decision of surgical excision of the lesion, followed by the rehabilitation of the zone with dental implants. The resulting defects were enriched with anterior iliac crest bone graft.

Keywords: Odontoma; ilium; therapy

ÖZET Odontoma en sık görülen benign odontojenik tümörlerdir. Semptom vermedikleri için rutin radyografilerde teşhis edilirler. Odontomalar radyografik, klinik ve histolojik özelliklerine göre sınıflandırılır; kompozit odontoma ve kompleks odontoma. Lezyonların destrükte ettikleri alanın rekonstrükte edilmesi gerekebilir. Geniş kemik defektleri ekstraoral donör alanlardan alınan otojen kemik greftleri ile rekonstrükstreükte edilebilir. Böyle vakalarda sıklıkla anterior iliak greftleri tercih edilmektedir. Biz bu olguda sağ posterio maksillada şişlik ve fasiyal asimetri şikayetiyle Ağız, Diş ve Çene Cerrahisi kliniğine başvuran hastayı sunmaktayız. İlk diagnostik teşhisimiz kompleks odontoma oldu. Lezyonun eksizyonundan sonra dental implantlarla bölgenin rehabilitasyonuna karar verildi. Defektin rekonstrüksiyonunda anterior iliak grefti kullanıldı.

Anahtar Kelimeler: Odontoma; ilium; tedavi

The complex type odontoma is a tumor-like malformation in which all the dental tissues are represented, although in a more or less disorganized pattern. Odontoma is the most common tumor of odontogenic tumors and is seen 5-30%.^{1,2} There are two types of odontomas, complex and compound, according to the radiographic, microscopic and clinical characteristics. Complex odontomas have irregular patterns that create irregular mass, whereas compound odontomas are tooth-like structures that form small stacks. Growth is usually slow and asymptomatic. The choice of treatment is surgical removal of the odontoma, followed by histological analysis.²⁻⁴ In these cases, after surgical treatment of the lesion, defect area should be reconstructed depending on its size. Graft materials used in oral surgery are divided into 4 categories; autogenous, allogenic, xenogenic

bones, and alloplastic materials. Autogenous grafts are considered the gold standard due to the inclusion of osteogenesis, osteoconductive, and osteoinductive properties. Autogenous grafts have some limitations because they have a risk of morbidity and resorption.^{5,6} Large bone defects in the jaw are usually reconstructed with autogenous bone graft from extraoral donor sites. In these operations, most common bone used is iliac crest. Graft operations must not only meet the functional and aesthetic requirements of the face, but also sufficiency to bone volume that support dental implants.^{6,7}

CASE REPORT

A 32-year-old male patient referred to the Department of Oral and Maxillofacial Surgery due to facial swelling causing asymmetry. Patient said that stiffness existed in the right maxilla for twenty years and that show slow growth. He was admitted to our hospital because he is suffering from asymmetry caused by the swelling.

Clinical examination revealed that there is an expansion in the right maxilla. Bone continuity was intact and lesion that caused asymmetry was detected. Panoramic radiographs reconstructed from Cone Beam Computed Tomography (CBCT) showed an irregular radiopaque lesion surrounded by a distinct radiolucent rim associated with the upper right premolars and molars, which was progressed into the maxillary sinus.

The first diagnostic hypothesis was complex odontoma. In decision of surgical excision of the lesion, CBCT images were obtained. The CBCT images revealed a 2.7x3.2x4.8 cm³ hyperdense mass interspersed with areas of hypodensity (Figure 1). Lesion caused the canine and premolar teeth to be impacted, and deciduous canine was still present. The lesion extended over from the alveolar ridge to the right maxillary sinus, displacing the upper right premolar and canine upper to the lesion.

Informed consent form was taken from the patient. Under general anesthesia, the lesion was surgically excised. Embedded canine and premolar teeth were extracted. The specimen was sent for

histopathological evaluation (Figure 2). Histologic sections revealed a mixture of radiopaque material composed mainly of dental tissues, consisting of immature dentin, enamel, enamel matrix, cementum, and pulp tissue. Histopathologic examination confirmed the diagnosis of complex odontoma. As the patient requested the rehabilitation of the region with dental implants after resection of the tumor, we augmented defected region with autogenous graft. We preferred anterior iliac crest from autogenous graft sources. Patient was under general anesthesia while the second team took 3x2x1 cm³ grafts from the left anterior iliac region. After dividing to appropriate sizes, the graft was fixated to the defected zone. After grafting the area, horizontal bone thickness measurements were obtained. 4 months after the surgery, the same area

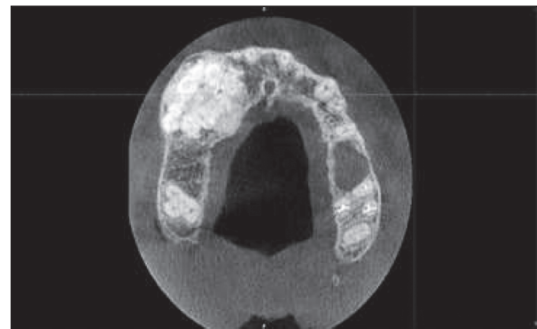


FIGURE 1: Preoperative CBCT- Transversal view.

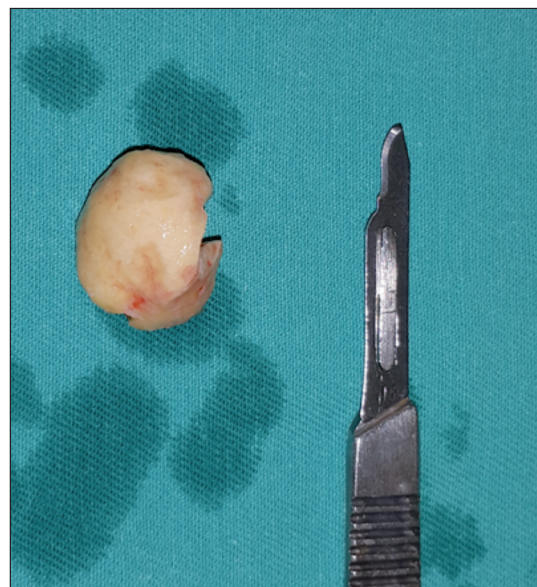

FIGURE 2: Excisional lesion.

was opened and plates and screws were removed under local anesthesia (Figure 3).

The remaining bone thickness measurements after early stage of horizontal bone resorption was taken. The first measurements in the region are as follows; canine region 0mm, first premolar region 0mm, second premolar region 0mm, first molar region 5mm. The second measurements after defective field grafting was as follows; canine region 10mm, first premolar region 11mm, second premolar region 10mm, first molar region 12mm. After 3 months, the measurements at the time of the implant placement were; canine region 7.5mm, first premolar region 9mm, second premolar region 9mm, first molar region 10mm. Early anterior iliac graft resorption rate was 17.5% for this case.

Three dental implants were placed and the area was primary closed. Diameters of the implants used were 3.8 mm in the canine, 4.1 mm in the premolar, 5 mm in the molar. The length of the implants were 13 mm in the canine, 13 mm in premolars, 9.5 mm in the molar region (Figure 4). After 3 months, prosthetic loading was done.

DISCUSSION

Odontomas are common and usually asymptomatic tumors in oral pathology and can be detected in routine radiography. They can cause symptoms such as pain, asymmetry and infection.³ In this case, the patient did not have any pain but he was suffering from asymmetry caused by the swelling. X-ray radiography is usually diagnostic. However, during the development of complex odontoma, it may resemble ameloblastic fibroma or fibro-odontoma; or miscible with osteoma or other high calcified bone lesions. Because of this, our team thought preliminary diagnosis might be odontoma, cementoma or cementoblastoma based on the radiographic findings. With histopathologic examination, definitive diagnosis must be made on oral lesions.¹ The most common approach to treatment have been raised with conservative surgery. If the tumor is completely cleared, the possibility of recurrence is almost zero. Alveolar bone grafting should be done if implant surgery is planned for

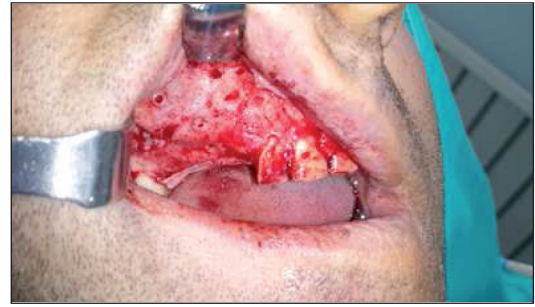

FIGURE 3: 4 months later image without plate and screws.

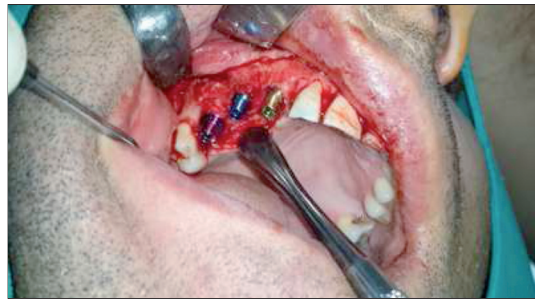


FIGURE 4: Image of placed 3 implants.

oral rehabilitation when there is a defect in alveolar bone. So, after the lesion is completely cleaned, we decided to reconstruct the defect in the region with iliac crest grafts.⁸ Mertens et al. report iliac graft has lower risk in terms of morbidity and dysfunction compared to the fibular graft.⁸

According to the defect size and nutritional capacity of region, we decided that it was appropriate to use iliac crest graft. Follow-up to ridge resorption and bone grafting is very important in these patients.^{5,9} Successful bone reconstruction provide not only the facial contours, but sufficient support for implant placement or the restoration of oral biological functions at the same time. Literature shows that 3-4 months after grafting is appropriate to make the implants.¹⁰

Acknowledgement

We would like to thank Mehmet Murat Zafer for the language control of the article.

Source of Finance

During this study, no financial or spiritual support was received neither from any pharmaceutical company that has a direct

connection with the research subject, nor from a company that provides or produces medical instruments and materials which may negatively affect the evaluation process of this study.

Conflict of Interest

No conflicts of interest between the authors and / or family members of the scientific and medical committee members or members of the potential conflicts of interest, counseling, expertise, working conditions, share holding and similar situations in any firm.

Authorship Contributions

Idea/Concept: Kübra Öztürk, Ertan Delilbaşı, Sevil Kahraman, **Design:** Ertan Delilbaşı, Tolga Kodaz; **Control/Supervision:** Kübra Öztürk, Ertan Delilbaşı, Sevil Kahraman; **Data Collection and/or Processing:** Kübra Öztürk, Ertan Delilbaşı, Sevil Kahraman; **Analysis and/or Interpretation:** Kübra Öztürk, Tolga Kodaz; **Literature Review:** Kübra Öztürk; **Writing the Article:** Kübra Öztürk, **Critical Review:** Kübra Öztürk, Ertan Delilbaşı, **References and Fundings:** Kübra Öztürk, Ertan Delilbaşı, **Materials:** Ertan Delilbaşı.

REFERENCES

1. Verma S, Arul AS, Arul AS, Chitra S. Erupted complex odontoma of the posterior maxilla: a rarity. J Nat Sci Biol Med. 2015;6(Suppl 1): S167-9. [[Crossref](#)] [[PubMed](#)] [[PMC](#)]
2. Santos LA, Lopes LJ, Roque-Torres GD, Oliveira VF, Freitas DQ. Complex odontoma: a case report with micro-computed tomography findings. Case Rep Dent. 2016;2016: 3584751. [[Crossref](#)]
3. Bereket C, Çakır-Özkan N, Şener İ, Bulut E, Tek M. Complex and compound odontomas: analysis of 69 cases and a rare case of erupted compound odontoma. Niger J Clin Pract. 2015;18(6):726-30. [[Crossref](#)] [[PubMed](#)]
4. Gujjar PK, Sahni P, Pereira T, Zingade J. Multiple compound odontomas in the jaws: a rare case report. J Clin Diagn Res. 2015;9(12): ZD5-6.
5. Lee J, Lee EY, Park EJ, Kim ES. An alternative treatment option for a bony defect from large odontoma using recycled demineralization at chairside. J Korean Assoc Oral Maxillofac Surg. 2015;41(2):109-15. [[Crossref](#)] [[PubMed](#)] [[PMC](#)]
6. Mertens C, Decker C, Seeberger R, Hoffmann J, Sander A, Freier K. Early bone resorption after vertical bone augmentation-a comparison of calvarial and iliac grafts. Clin Oral Implants Res. 2013;24(7):820-5. [[Crossref](#)] [[PubMed](#)]
7. Fretwurst T, Nack C, Al-Ghrai M, Raguse JD, Stricker A, Schmelzeisen R, et al. Long-term retrospective evaluation of the peri-implant bone level in onlay grafted patients with iliac bone from the anterior superior iliac crest. J Craniomaxillofac Surg. 2015;43(6):956-60. [[Crossref](#)] [[PubMed](#)]
8. Mertens C, Decker C, Engel M, Sander A, Hoffmann J, Freier K. Early bone resorption of free microvascular reanastomized bone grafts for mandibular reconstruction--a comparison of iliac crest and fibula grafts. J Craniomaxillofac Surg. 2014;42(5):e217-23. [[Crossref](#)] [[PubMed](#)]
9. Fang QG, Shi S, Sun CF. Odontogenic lesions in pediatric patients. J Craniomaxillofac Surg. 2014; 25(3):e248-51. [[Crossref](#)] [[PubMed](#)]
10. Zou D, Huang W, Wang F, Wang S, Zhang Z, Zhang C, et al. Autologous ilium grafts: long-term results on immediate or staged functional rehabilitation of mandibular segmental defects using dental implants after tumor resection. Clin Implant Dent Relat Res. 2015;17(4):779-89. [[Crossref](#)] [[PubMed](#)]