

Acute Thrombus Formation on an Occlutech ASD Occluder Device During Transcatheter Closure: Case Report

Transkateter Kapatma Sırasında Occlutech ASD Kapatma Cihazı Üzerinde Oluşan Akut Trombüs

Mehmet Zihni BİLİK,^a
 Mehmet Ata AKIL,^a
 Halit ACET,^a
 Hasan KAYA,^a
 Faruk ERTAŞ^a

^aDepartment of Cardiology,
 Dicle University Faculty of Medicine,
 Diyarbakır

Geliş Tarihi/Received: 14.10.2015
 Kabul Tarihi/Accepted: 09.02.2016

Yazışma Adresi/Correspondence:
 Mehmet Zihni BİLİK
 Dicle University Faculty of Medicine,
 Department of Cardiology,
 Diyarbakır,
 TÜRKİYE/TURKEY
 mzbilik@mynet.com

ABSTRACT Acute thrombosis during transcatheter device closure of atrial septal defect is a very rare but important complication. A 67-year-old woman with secundum type atrial septal defect underwent closure with the Occlutech Figula device. Acetilsalicylic acid and clopidogrel had been started one day before procedure and heparin was given at the beginning of the procedure. During the intervention a thrombus on the left atrial disk was detected by transesophageal echocardiography (TEE). The delivery system and thrombus were successfully removed from circulation. Additional heparin bolus was given and the procedure was completed successfully. The control TEE showed good device position and no thrombus formation on the device. The patient was discharged without any complication.

Key Words: Heart septal defects, atrial; thrombosis; septal occluder device; echocardiography, transesophageal

ÖZET Transkateter atriyal septal defekt kapatma sırasında akut trombüs oluşumu nadir görülür, ancak önemli bir komplikasyondur. 67 yaşında kadın hasta, Occlutech Figula kapama cihazı ile sekundum tip atriyal septal defekt kapatma işlemine alındı. İşlemden bir gün önce asetilsalisilik asit ve klopidogrel başlandı. İşlemden önce hastaya heparin verildi. İşlem sırasında transözofageal ekokardiyografi (TEE) ile sol atriyal disk üzerinde trombüs tespit edildi. Sistem dikkatli bir şekilde dolaşımdan çıkarılarak trombüsten temizlendi. Hastaya ek olarak heparin bolus yapıldı ve işlem başarılı bir şekilde sonlandırıldı. Yapılan kontrol TEE’de trombüs saptanmadı ve cihaz uygun pozisyondaydı. Hasta herhangi bir komplikasyon gelişmeden taburcu edildi.

Anahtar Kelimeler: Kalp septum kusurları, atriyal; tromboz; septal okluder cihaz; ekokardiyografi, transözofageal

For the video/videos of the article:



Türkiye Klinikleri J Cardiovasc Sci 2016;28(1):25-8

Transcatheter device closure of ASD has become the first choice for secundum defect closure.¹ Serious complications are observed in $\leq 1\%$ of patients. Thrombo-embolic events appear to be very rare.² The Occlutech Figula occluder is a safe and efficient device to close secundum ASDs.³ We reported, herein, a successfully treated case of acute thrombus formation on the left atrial disk of Occlutech Figula ASD occluder in a patient under antiplatelet and anticoagulant therapy during the procedure.

doi: 10.5336/cardiosci.2015-48330

Copyright © 2016 by Türkiye Klinikleri

CASE REPORT

A 67-year-old woman with dyspnea lasting in the past one year was admitted to the hospital. The patient showed heart failure symptoms and her functional capacity was New York Heart Association (NYHA) Class II-III. She has had systemic hypertension for 10 years and diabetes mellitus for 7 years. There was no deep vein thrombosis or any embolic episodes in the history. She has received medical therapy at that time. The echocardiography (ECG) displayed sinus rhythm and right bundle branch block. Echocardiography revealed a dilated right atrium and ventricle; and a secundum atrial septal defect (ASD) leading to left to right atrial shunt (Q_p/Q_s : 1.8). Estimated pulmonary artery systolic pressure was 42 mmHg with mild-to-moderate tricuspid regurgitation. TEE showed an 18 mm secundum atrial septal defect with adequate rims. The transcatheter closure procedure was performed under general anaesthesia with TEE guidance. 300 mg of acetylsalicylic acid and 75 mg of clopidogrel had been started one day before procedure and 100 IU/kg unfractionated heparin was given intravenously at the beginning of the procedure. A 21 mm Figulla Flex II (Occlutech® GmbH, Jena, Germany) ASD occluder device was used for occlusion. Before releasing the device, TEE was revealed a thrombus at the centre of the left atrial disk of the device (Figure 1). The delivery system was removed carefully from the circulation with negative pressure through an injector and the system was cleaned from thrombus. Additional intravenous 5.000 IU heparin was given and the intervention continued. The procedure was successfully performed with 21 mm Occlutech occluder device without any residual shunt (Figure 2). No thromboembolic events were seen. Control TEE was performed the day of the procedure and there was not any thrombus formation on the device. The patient was examined for hypercoagulable states such as protein C and protein S deficiency, anticardiolipin antibodies, factor V Leiden mutation, but laboratory tests were not positive. She was discharged with the prescription of medical therapy including clopidogrel and low dose acetylsalicylic acid.

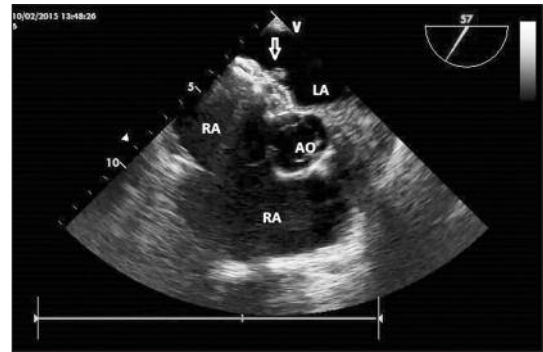


FIGURE 1: Transesophageal echocardiography shows a thrombus formation (arrow) at the centre of the left atrial disc.

AO: Aorta; LA: Left atrium; RA: Right atrium; RV: Right ventricle.

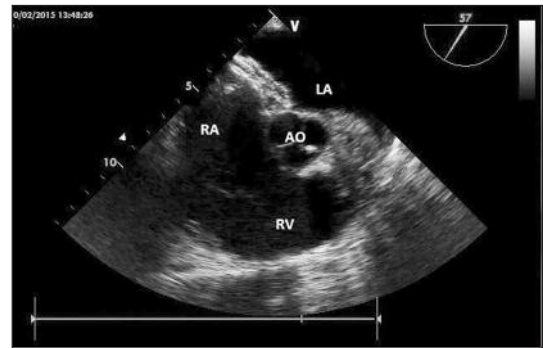


FIGURE 2: Control Transesophageal echocardiography shows no thrombus with normal position of the device.

AO: Aorta; LA: Left atrium; RA: Right atrium; RV: Right ventricle.

DISCUSSION

Transcatheter closure of ASD is a safe and efficient procedure and has become the first choice for secundum atrial septal defects with low mortality and morbidity.¹ Comparing with surgery, the transcatheter closure has a shorter hospitalization period.⁴ The Occlutech Figulla occluder is a safe and effective device to close secundum ASDs.³

Thrombus formation during the procedure under the acetylsalicylic acid, clopidogrel and heparin therapy is a very rare state.² There is a high risk of thrombus embolisation early after transcatheter closure of friability and mobility thrombus. An immediate and aggressive treatment management is necessary.⁵ There are different management strategies in the literature for thrombus formation during transcatheter closure. Wilcoxon et al. were treated the thrombus formation with abciximab and he-

parin combination. In their case the thrombus has taken place early after inserting the occluder device in a 12 year-old boy.⁵ Eren et al. have detected a thrombus formation at the tip of the delivery sheath before placing the occluder device.⁶ They have removed the device and treated with additional heparin bolus. Acar et al. have treated the thrombus formation after placing the occluder device with heparin infusion.⁷ Yazicioglu et al. have detected a thrombus on the left atrial disk of the occluder device before placing the device.⁸ They have removed the device and were treated with tirofiban and heparin infusion. Aytemir et al. have reported device thrombosis only in two patients during the procedure in a large study in which they had included 193 ASD and 221 Patent foramen ovale (PFO) patients.⁹ They have reported activated clotting time (ACT) as <250 seconds during the procedure. They have treated both cases with unfractionated heparin infusion and the dose has been adjusted with a target activated partial thromboplastin time of 50-70 seconds.

There are some limitations in our case. Firstly we did not measure ACT during procedure. It is important to measure ACT for monitoring anticoagulant effect of heparin. Heparin resistance can be seen in some patients even though in the patients with normal hypercoagulability tests. Therefore, it is necessary to follow the ACT. Secondly clopidogrel should be loaded as 300-600 mg of dose before procedure or it should be started a week before procedure with 75 mg. In this case we started clopidogrel 75 mg in dose one day before procedure.

Heparin resistance should be considered in patients when acute thrombus formation occurs during occlusion procedure. Heparin resistance during cardiac surgery is defined as the failure of high doses of heparin to achieve a target ACT (>400 s) or the need for exogenous antithrombin administration.^{10,12} The incidence of heparin resistance during cardiac surgery ranges from 4% to 26%.¹¹⁻¹³ Antithrombin deficiency has been thought to be the primary mechanism of heparin resistance, but the reasons for heparin resistance are complex and multifactorial. Managements for heparin resistance include additional heparin or antithrombin supplementation.¹² In some cases, heparin has been given at high doses (15 mg/kg).¹⁴

In our case, the patient was under acetilsalicylic acid, clopidogrel and heparin therapy. Possibly there might have been heparin resistance in the patient, but we could not diagnosed it. After removing the system we cleaned the delivery system from thrombus. Additional heparin bolus was given to the patient and the procedure was completed without complication.

In this case we aimed to draw attention to some important points. Firstly, it is important to perform the closure procedure under TEE guidance. Before placing the occluder device, more attention should be paid for detecting thrombus formation on occluder device or delivery system by TEE. Secondly, monitoring ACT during the procedure is very important. By measuring ACT, heparin resistance can be diagnosed. Additionally, a standard management is needed for treating thrombus formation during the procedure.

REFERENCES

1. Baumgartner H, Bonhoeffer P, De Groot NM, de Haan F, Deanfield JE, Galie N, et al; ESC Committee for Practice Guidelines (CPG). ESC Guidelines for the management of grown-up congenital heart disease (new version 2010). *Eur Heart J* 2010;31(23):2915-57
2. Krumdorf U, Ostermayer S, Billinger K, Trepels T, Zadan E, Horvath K, et al. Incidence and clinical course of thrombus formation on atrial septal defect and patent foramen ovale closure devices in 1,000 consecutive patients. *J Am Coll Cardiol* 2004;43(2):302-9.
3. İlkay E, Kacmaz F, Ozeke O, Turan RS, Firat S, Pampal K, et al. The efficiency and safety of percutaneous closure of secundum atrial septal defects with the Occlutech Figulla device: initial clinical experience. *Turk Kardiyol Dern Ars* 2010;38(3):189-93.
4. Fiarresga A, De Sousa L, Martins JD, Ramos R, Paramés F, Freitas I, et al. Percutaneous closure of atrial septal defects: a decade of experience at a reference center. *Rev Port Cardiol* 2010;29(5):767-80.
5. Willcoxson FE, Thomson JD, Gibbs JL. Successful treatment of left atrial disk thrombus on an Amplatzer atrial septal defect occluder with abciximab and heparin. *Heart* 2004;90(5):e30.

6. Eren NK, Akyıldız Zİ, Acet H, Ertas F, Nazlı C, Ergene O. Thrombus formation on the delivery sheath during transcatheter atrial septal defect closure. *Tex Heart Inst* 2009;36(6):624-5.
7. Acar P, Aggoun Y, Abdel-Massih T. Images in cardiology: thrombus after transcatheter closure of ASD with an Amplatzer septal occluder assessed by three dimensional echocardiographic reconstruction. *Heart* 2002;88(1): 52.
8. Yazıcıoğlu V, Sahin M, Karaca O, Türkmen M. Acute thrombus formation on an Amplatzer device during transcatheter closure of an atrial septal defect in a patient with homozygous factor V Leiden mutation. *Türk Kardiyol Dern Ars* 2011;39(7):587-90.
9. Aytemir K, Oto A, Özkutlu S, Canpolat U, Kaya EB, Yorgun H, et al. Transcatheter interatrial septal defect closure in a large cohort: midterm follow-up results. *Congenit Heart Dis* 2013;8(5):418-27.
10. Anderson JA, Saenko EL. Heparin resistance. *Br J Anaesth* 2002;88(4):467-9.
11. Williams MR, D'Ambra AB, Beck JR, Spanier TB, Morales DL, Helman DN, et al. A randomized trial of antithrombin concentrate for treatment of heparin resistance. *Ann Thorac Surg* 2000;70(3):873-7.
12. Finley A, Greenberg C. Review article: heparin sensitivity and resistance: management during cardiopulmonary bypass. *Anesth Analg* 2013;116(6):1210-22.
13. Staples MH, Dunton RF, Karlson KJ, Leonardi HK, Berger RL. Heparin resistance after preoperative heparin therapy or intraaortic balloon pumping. *Ann Thorac Surg* 1994;57(5):1211-6.
14. Toprak Hİ, But A, Borazan H, Ersoy MÖ. [Heparin resistance (Case report)]. *J Turgut Ozal Med Cent* 2003;10(2):91-93.