

Pulmonary Artery Dissection Diagnosed by Multidetector Computed Tomographic Angiography: Case Report

Çok Kesitli Bilgisayarlı Tomografik Anjiyografi ile Tanı Alan Pulmoner Arter Diseksiyonu

Aysel TÜRKVATAN, MD,^a
Dilek ALTINSOY, MD,^a
Ahmet AKGÜL, MD,^b
Tülay ÖLÇER, MD,^a
Turhan CUMHUR, MD^a

Departments of

^aRadiology,

^bCardiovascular Surgery,

Bakırköy Dr Sadi Konuk Research and
Training Hospital, İstanbul

Geliş Tarihi/Received: 19.03.2009

Kabul Tarihi/Accepted: 09.05.2009

*This article was presented as a poster
in 29th National Radiology Congress,
Antalya, November 1-5, 2008.*

Yazışma Adresi/Correspondence:

Aysel TÜRKVATAN, MD

Türkiye Yüksek İhtisas Hospital,

Department of Radiology,

Ankara,

TÜRKİYE/TURKEY

aturkvatan@yahoo.com

ABSTRACT Pulmonary artery dissection is a rare condition which usually occurs in patients with underlying pulmonary arterial hypertension. The condition generally manifests as cardiogenic shock or sudden death because the dissection progresses rapidly and thereby it is usually diagnosed at post-mortem studies. Herein, we report a 25-year-old man who had pulmonary artery dissection diagnosed by multidetector computed tomographic (MDCT) pulmonary angiography. The patient with previous history of pulmonary artery thromboemboli was admitted to the emergency department with shortness of breath and retrosternal chest pain. MDCT pulmonary angiography revealed the presence of multiple dissection flap in the lobar and segmental branches of the both right and left pulmonary arteries. A conservative medical therapy was chosen due to the peripheal location of the dissections and the lack of the aneurysm or underlying pulmonary hypertension. In this report, we review the aetiology, pathophysiology and clinical presentation of pulmonary artery dissection and we discuss the role of imaging modalities in the diagnosis of this rare entity.

Key Words: Pulmonary artery; dissection; pulmonary embolism;
computed tomography, X-ray

ÖZET Pulmoner arter diseksiyonu genellikle alta yatan pulmoner hipertansiyonu bulunan hastalarda ortaya çıkan nadir bir durumdur. Diseksiyonun hızlı bir şekilde ilerlemesi nedeni ile bu durum genellikle kardiyojenik şok veya ani ölümlerle kendini gösterir ve bu yüzden genellikle postmortem incelemelerde tanı alır. Biz burada, çok kesitli bilgisayarlı tomografik (ÇKBT) pulmoner anjiyografi ile tanı alan, pulmoner arter diseksiyonu bulunan 25 yaşındaki bir erkek olgunun bulgularını sunuyoruz. Daha önceden pulmoner arter tromboembolisi geçirme öyküsü bulunan hasta nefes darlığı ve retrosternal göğüs ağrısı yakınmaları ile acil servise kabul edildi. ÇKBT pulmoner anjiyografi sağ ve sol pulmoner arterin her ikisinde lobar ve segmental dallarında çok sayıda diseksiyon flebinin varlığını ortaya koydu. Diseksiyonların periferik lokalizasyonu ve anevrizma ya da alta yatan pulmoner hipertansiyonun olmaması nedeni ile konservatif medikal tedavi seçildi. Biz bu raporda, pulmoner arter diseksiyonunun etiolojisi, patofizyolojisi ve klinik prezentasyonunu gözden geçiriyor ve bu nadir durumun tanısında görüntüleme modalitelerinin rolünü tartışıyoruz.

Anahtar Kelimeler: Pulmoner arter; diseksiyon; pulmoner embolizm;
çok kesitli bilgisayarlı tomografi

Türkiye Klinikleri J Cardiovasc Sci 2009;21(2):292-6

Pulmonary artery dissection is a rare clinical entity and usually it has been associated with either chronic pulmonary hypertension, secondary to congenital heart diseases or acquired valvular diseases or primary pulmonary hypertension.¹ It can occasionally occur with normal

pulmonary artery pressure in association with conditions such as connective tissue disorders, degenerative changes or chronic inflammation of the pulmonary artery secondary to septic emboli, amyloidosis, right heart endocarditis, atherosclerosis, pulmonary thromboemboli and iatrogenic causes.² Clinical presentation of a pulmonary artery dissection typically involves exertional dyspnea, chest pain and central cyanosis.³ The diagnosis of this condition is usually made during autopsy, because the dissection usually progresses rapidly and rupture occurs into the pericardium and its first manifestation can be cardiogenic shock or sudden death.⁴ However, recent isolated reports have described pulmonary artery dissection in surviving patients who were diagnosed by echocardiography (ECO), spiral computed tomography (CT) and magnetic resonance imaging (MRI).^{1,2,5-7} At the present time, MDCT angiography has become a principal imaging modality for the evaluation of pulmonary artery diseases due to its having advantages such as short acquisition time and high spatial resolution. In this report, we present MDCT pulmonary angiography findings of multiple dissection of intrapulmonary arteries in a patient who had previous history of pulmonary artery thromboemboli.

CASE REPORT

A 25-year-old man was admitted to the emergency department with shortness of breath and retrosternal chest pain. About six months ago, he had deep vein thrombosis and pulmonary thromboemboli treated with antithrombotic and followed by oral anticoagulant therapy (Figure 1). Physical examination was unremarkable. Blood pressure was 110/80 mmHg, pulse rate was 82 beats/min and respiration rate was 24 breaths/min. An electrocardiogram showed normal sinus rhythm and was otherwise normal. On ECO, systolic, diastolic and mean pressures in the pulmonary artery were normal. Arterial blood gas analysis, at room air, showed a pH of 7.39, pO₂ of 73.5 mmHg, pCO₂ of 33.1 mmHg, cHCO₃ 19.8 mmol/L and O₂ saturation of 95%. A chest roentgenogram showed no abnormality. MDCT angiography was performed with a

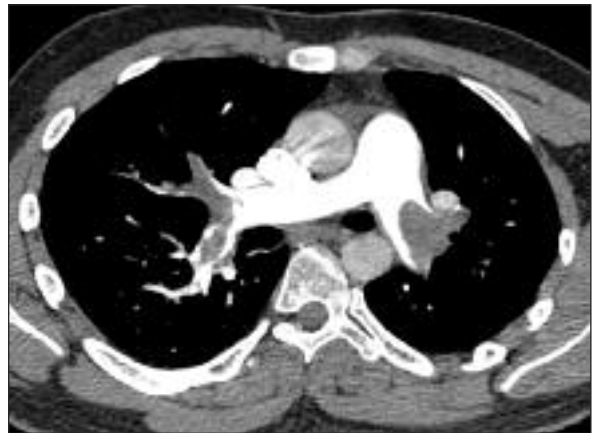

FIGURE 1: Axial multidetector computed tomographic pulmonary angiography image shows major pulmonary thromboembolism involving the left main artery and the right lobar and segmental arteries.

16-slice MDCT scanner (Lightspeed Ultra, GE Medical Systems, Milwaukee, Wisc.; USA). Informed consent was obtained from the patient before he underwent MDCT examination. The imaging data was acquired during an intravenous injection of 100 mL of iodinated contrast agent (Iodixanol, Visipaque® 320 mgI/mL, GE Healthcare, Milwaukee, Wisc.; USA) at a rate of 4 mL/sec. The scanning delay was determined by using a bolus tracking method, in which a region of interest was placed on the main pulmonary artery, and scanning was triggered at the contrast enhancement threshold of 100 HU. Imaging parameters were as follows: tube voltage, 120 kV; tube current, 300 mAs, collimation, 16 x 0.625 mm; and gantry rotation time, 0.5 sec. Images were reconstructed from the raw data set at 1.25 mm intervals and 1.25 mm slice thickness. MDCT pulmonary angiography revealed intimal flaps in the right lower lobe pulmonary artery extending through the length of the descending branch and into a segmental branch, in the right middle lobe lateral segmental branch, in the left upper lobe pulmonary artery and in the left lower lobe pulmonary artery extending into a segmental branch (Figure 2). No sign of pulmonary thromboemboli or enlargement was detected in the pulmonary arteries. Due to the peripheral location of the dissections and the lack of the aneurysm and un-

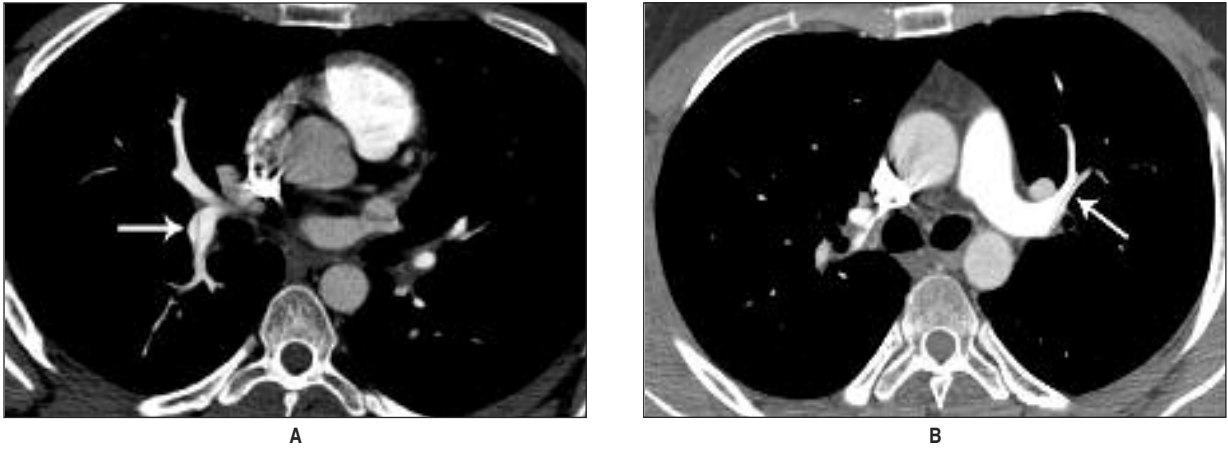


FIGURE 2: Axial multidetector computed tomographic pulmonary angiography images (A, B) show intimal flaps (arrows) in the right lower lobe and the left upper lobe pulmonary artery branches.

derlying pulmonary hypertension, we choose a conservative management consisting of 25% oxygen and an intravenous vasodilator (nitroglycerine). The patient improved rapidly and was discharged home 2 days later. A medical treatment of metoprolol was administered to the patient and he was followed-up regularly.

DISCUSSION

Pulmonary artery dissection is a rare but life-threatening condition, as sudden death typically results when the main pulmonary artery dissects into the pericardium causing acute cardiac tamponade. Rupture of the pulmonary artery can also occur into the lung parenchyma, bronchial tree, mediastinum or pleural cavity. Dissection into the bronchial tree may cause significant hemoptysis following a severe coughing spell. Rarely, the dissection may occlude the pulmonary outflow tract. Death preceded by a sudden hemodynamic decompensation has been frequently reported, mostly in patients who were previously stable and had known risk factors or a known pulmonary artery aneurysm.⁸ Pulmonary artery dissection usually occurs in the major branches, predominantly in the pulmonary trunk (72%), followed by the intrapulmonary arteries (10%), the pulmonary trunk and right main artery (6%), the left main artery (6%), the right main artery (4%) and the pulmonary trunk and both main arteries (2%).³

Though, the pathophysiologic cause of the pulmonary artery dissection is not clear, pulmonary hypertension and resultant degeneration of the media with fragmentation of elastic fibres strongly predispose to this condition. In the literature, a pulmonary artery dissection always occurs at the site of a pulmonary artery aneurysm or dilatation. It is reasonable to assume that dissection occurs at the point in which the vessel tissue becomes too fragile to support the tension of the pulmonary artery wall. With medial degeneration, the wall is weakened, the vessel may dilate, and the raised intravascular pressure and shear stresses may predispose to the development of an intimal tear. Tissue fragility of the pulmonary artery wall is also caused by infectious and connective tissue diseases.⁸ Dissection of pulmonary artery can develop as a result of damage to arterial wall consisting of mural inflammation, smooth muscle necrosis and internal elastic fragmentation produced by chronic thromboemboli.^{4,9}

In the majority of reported cases (86.5%) the diagnosis of pulmonary artery dissection has been made during autopsy.² Over the past two decades, pulmonary artery dissection has been diagnosed during life in eleven previous cases.^{1-3,5-12} This may partly reflect the technological development and increasing use of non-invasive imaging modalities during this period. The diagnosis of pulmonary artery dissection is made by ECO, spiral CT and

MRI. Spiral CT with optimal contrast enhancement can provide an accurate display of the dissection and aneurysm of the pulmonary artery.^{1,2} Furthermore, accurate demonstration of the intimal flap, false lumen, intraluminal thrombi, wall calcifications, and associated lung and mediastinal pathologies are possible.⁵ The advantages of MRI to spiral CT in the evaluation of pulmonary artery dissection is that the capability of multiplanar imaging, and therefore better demonstration of the vessel course.^{6,11} However, the acquisition protocols that are currently available for pulmonary angiography lack sufficient spatial resolution for reliable evaluation of peripheral pulmonary arteries.¹³ Furthermore, this modality has not seen widespread use in acutely ill patients, due to lack of general availability, relatively long examination times, and difficulties in patient monitoring. With MDCT technology, past limitations of spiral CT for the diagnosis of pulmonary artery diseases should be effectively overcome and MDCT has become the first-line modality for imaging in patients suspected of having pulmonary artery diseases.¹⁴ The advantages of MDCT include improved temporal and spatial resolution, enabling the acquisition of isotropic volume data, greater anatomic coverage, more consistent contrast agent enhancement, faster scan speed and high quality three dimensional reconstructions. MDCT pulmonary angiography allows an accurate evaluation of the full course of pulmonary arteries and more consistent demonstration of subsegmental vascular anatomy. MDCT pulmonary angiography is widely available, safe, cost effective, and an accurate examination for the

quick and comprehensive evaluation of the pulmonary circulation.¹⁴ The hallmark of pulmonary arterial dissection is the finding of an intimal flap and a false lumen. However, a pseudo-flap in the pulmonary artery due to motion artefacts from aortic and cardiac pulsation is a potential pitfall in MDCT for the diagnosis of pulmonary artery dissection.¹⁵ If motion artefact is suspected, confirmation using ECO or electrocardiogram gated MDCT should be considered.

Because of the paucity of cases reported in the literature, there are no accepted medical management regimens for the treatment of a pulmonary artery dissection. Surgical treatment of pulmonary artery dissection includes aneurysmorrhaphy, vascular prosthesis, arterial banding, and lobar- or pneumonectomy.⁵ The exact delineation of the location and extent of the dissection is important for determining the optimal surgical approach or the indication of an intervention. Due to the peripheral location of the dissections and the lack of the aneurysm and underlying pulmonary hypertension we choose a conservative management.

In conclusion, pulmonary artery dissection is a rare and life threatening condition that should be suspected in patients presenting with retrosternal chest pain or dyspnea who have a previous history of pulmonary artery thromboemboli. Pulmonary MDCT angiography provides a rapid and accurate diagnosis of this condition and can identify the precise location and extent of dissection flap and concomitant lung and mediastinal pathologies.

REFERENCES

1. Navas Lobato MA, Martín Reyes R, Lurueña Lobo P, Maté Benito I, Guzmán Hernández G, Martí de Gracia M, et al. Pulmonary artery dissection and conservative medical management. *Int J Cardiol* 2007;119(1):e25-6.
2. Khattar RS, Fox DJ, Alty JE, Arora A. Pulmonary artery dissection: an emerging cardiovascular complication in surviving patients with chronic pulmonary hypertension. *Heart* 2005;91(2):142-5.
3. Inayama Y, Nakatani Y, Kitamura H. Pulmonary artery dissection in patients without underlying pulmonary hypertension. *Histopathology* 2001;38(5):435-42.
4. Steingrub J, Detore A, Teres D. Spontaneous rupture of pulmonary artery. *Crit Care Med* 1987;15(3):270-1.
5. Wunderbaldinger P, Bernhard C, Uffmann M, Kürkciyan I, Senbaklavaci O, Herold CJ. Acute pulmonary trunk dissection in a patient with primary pulmonary hypertension. *J Comput Assist Tomogr* 2000;24(1):92-5.
6. Westaby S, Evans BJ, Ormerod O. Pulmonary-artery dissection in patients with Eisenmenger's syndrome. *N Engl J Med* 2007;356(20):2110-2.
7. Song EK, Kolecki P. A case of pulmonary artery dissection diagnosed in the Emergency Department. *J Emerg Med* 2002;23(2):155-9.

8. Senbakkavaci O, Kaneko Y, Bartunek A, Brunner C, Kurkciyan E, Wunderbaldinger P, et al. Rupture and dissection in pulmonary artery aneurysms: incidence, cause, and treatment--review and case report. *J Thorac Cardiovasc Surg* 2001;121(5):1006-8.
9. Steurer J, Jenni R, Medici TC, Vollrath T, Hess OM, Siegenthaler W. Dissecting aneurysm of the pulmonary artery with pulmonary hypertension. *Am Rev Respir Dis* 1990;142(5): 1219-21.
10. Rosenson RS, Sutton MS. Dissecting aneurysm of the pulmonary trunk in mitral stenosis. *Am J Cardiol* 1986;58(11): 1140-1.
11. Stern EJ, Graham C, Gamsu G, Golden JA, Higgins CB. Pulmonary artery dissection: MR findings. *J Comput Assist Tomogr* 1992;16(3): 481-3.
12. Lopez-Candales A, Kleiger RE, Aleman-Gomez J, Kouchoukos NT, Botney MD. Pulmonary artery aneurysm: review and case report. *Clin Cardiol* 1995;18(12):738-40.
13. Oudkerk M, van Beek EJ, Wielopolski P, van Ooijen PM, Brouwers-Kuyper EM, Bongaerts AH, et al. Comparison of contrast-enhanced magnetic resonance angiography and conventional pulmonary angiography for the diagnosis of pulmonary embolism: a prospective study. *Lancet* 2002;359(9318): 1643-7.
14. Schoepf UJ, Costello P. CT angiography for diagnosis of pulmonary embolism: state of the art. *Radiology* 2004;230(2):329-37.
15. Pua U, Tan CH. CT diagnosis of pulmonary artery dissection-potential pitfall of multidetector CT. *Br J Radiol* 2009;82(973):82-3.