







Recurrent Cemento-Ossifying Fibroma of the Mandible

Mandibulada Tekrarlayan Semento-Ossifiye Fibroma

-  Selin YEŞİLTEPE,^a
 Yasin YAŞA,^b
 İbrahim Şevki BAYRAKDAR,^c
 Ahmet Berhan YILMAZ,^a
 Adnan KILINÇ,^d
 Cemal GÜNDOĞDU^e

Departments of
^aOral and Maxillofacial Radiology,
^bDentomaxillofacial Surgery
 Atatürk University Faculty of Dentistry,
 Erzurum
^cDepartment of Oral and Maxillofacial
 Radiology,
 Ordu University Faculty of Dentistry,
 Ordu
^dDepartment of Oral and Maxillofacial
 Radiology,
 Eskişehir Osmangazi University
 Faculty of Dentistry,
 Eskişehir
^ePrivate Dentist,
 Erzurum

Received: 04.08.2017
 Received in revised form: 06.11.2017
 Accepted: 07.11.2017
 Available online: 18.10.2018

Correspondence:
 Selin YEŞİLTEPE
 Atatürk University Faculty of Dentistry,
 Department of Oral and Maxillofacial
 Radiology, Erzurum,
 TURKEY/TÜRKİYE
 dt_selin@yahoo.com

This study was presented as a poster at
 XVth European Congress of Dentomaxillofacial
 Radiology (ECDMFR) in Cardiff, Wales,
 15-18 June, 2016.

ABSTRACT Cemento-ossifying fibroma (COF) is an uncommon, benign fibro-osseous lesion that is often localized in mandibular premolar and molar areas. A COF appears as a single, slow growing lesion, which is usually asymptomatic until facial asymmetry and swelling occur, depending on the tumour growth. The most common clinical signs of COF are swelling and tooth displacement. COF lesions are normally observed from the 2nd through 4th decades of life, most commonly in women. The treatment consists of enucleation or radical surgery, depending on the location and size of the lesion. Despite the fact that recurrence is considered to be rare, regular postoperative follow ups are important for early detection. In this case report, a recurrent COF is presented, characterized by asymptomatic mandibular lesions and diagnosed based on the clinical, radiological and pathological findings.

Keywords: Fibroma, ossifying; cone-beam computed tomography

ÖZET Semento-ossifiye fibroma (SOF) nadir görülen, çoğunlukla mandibular premolar ve molar bölgelerde gözlenen benign fibro-osseöz bir lezyondur. SOF tek, yavaş büyüyen bir lezyon olarak ortaya çıkar, tümör büyümesine bağlı fasiyal asimetri ve şişlik ortaya çıkıncaya kadar genellikle asemptomatiktir. SOF'un en yaygın görülen klinik bulguları şişlik ve diş deplasmanlarıdır. SOF lezyonları genellikle kadınlarda, hayatın 2. ve 4. dekatlarında görülür. SOF lezyonlarının tedavisi lezyonların lokalizasyonuna ve boyutuna bağlı olarak enükleasyon veya radikal cerrahi yöntemidir. Rekürrens nadir görülmesine rağmen düzenli postoperatif takip erken tespit için önemlidir. Bu olgu raporunda, klinik, radyolojik ve patolojik bulgulara dayanarak tanı koyulan, asemptomatik mandibular lezyonlarla karakterize, rekürrent SOF vakası sunulmaktadır.

Anahtar Kelimeler: Fibrom, ossifiye; konik ışınlı bilgisayarlı tomografi

Fibro-osseous lesions are pathologies that are characterized by the replacement of normal bone structure with fibroblasts and fibrous connective tissue.¹ These lesions were classified as fibrous dysplasia, cemento-osseous dysplasia and cemento-ossifying fibroma (COF) by Neville in 1995.² Later, they were classified as fibrous dysplasia, osseous dysplasia and ossifying fibroma by the World Health Organization (WHO) in 2005.³ Even though these lesions have different characteristics, they do show similar clinical and radiological features.⁴ However, they present with different biological features. While osseous dysplasia and fibrous dysplasia are reactive lesions, ossifying fibroma is the most common of the neoplastic components of fibro-osseous lesions. One distinguishing feature that may be

present is a soft tissue capsule at the periphery, which is not seen in fibrous dysplasia. For this reason, a final diagnosis is important.⁵

COF lesions are normally observed from the 2nd through 4th decades of life, most commonly in women, and are more often in the mandibular premolar and molar areas.⁶ They can be seen in both jaws, but occur more frequently in the mandible compared to the maxilla. COF lesions are rarely seen in facial sinuses and nasal cavities. COF appears as a single, slow growing lesion that is usually asymptomatic, until swelling and facial asymmetry occur, depending on the tumour growth. The most common clinical signs of COF are swelling and tooth displacement.¹

Radiographically, COF is seen as a well-defined, unilocular, radiolucent mass containing opaque areas in relation to the amount of the comprising calcified components. Early stage lesions are completely radiolucent, while progressively mixed and mature lesions are radiopaque and surrounded by a radiolucent halo.^{5,7} COF is diagnosed by clinical, radiographic and histopathological findings.^{4,8,9}

The treatment options for COF includes enucleation or radical surgery, depending on the location and size of the lesion. Large lesions require a detailed determination of the extent of the lesion, which can be obtained with advanced imaging methods.¹⁰ COF should be removed completely and surgically to prevent recurrence. Even though recurrence is considered to be rare, regular postoperative follow ups are important for early detection of a possible relapse.¹¹

A recurrent COF, which was characterized by asymptomatic mandibular lesions and was diagnosed based on clinical, radiological and pathological findings is presented in this case report.

CASE REPORT

A 34-year-old female patient was referred to Oral and Maxillofacial Radiology clinic of the Atatürk University Dentistry Faculty with complaint of painless swelling in the right mandible. The clinical examination revealed buccolingual expansion throughout the region of the right mandibular first

molar tooth (Figure 1). A panoramic radiograph revealed a mixed radiopaque and radiolucent lesion with an ill-defined, scalloped and radiolucent border (Figure 2). The patient's medical history showed that she had no systemic diseases. The teeth associated with the lesion were vital, without any restorations or decay. A mixed lesion with hyperdense foci with undetectable margins was observed in dentition area 46 on cone-beam computed tomography (CBCT) images (NewTom FP, Quantitative Radiology, Verona, Italy). The lesion had resulted with an enlargement and thinning of the buccolingual bones (Figure 3). Despite the involvement of the superior mandibular canal wall, the patient had no complaints of paraesthesia. The patient was referred to oral surgery department to undergo an excisional biopsy, and the biopsy specimen was sent for a histopathological analysis with a preliminary diagnosis of a COF.

The pathology report showed dense, compact, bone-cement looking areas with irregular lamellation, and tissue samples containing cellular stroma composed of spindle fibroblastic cells (Figure 4).

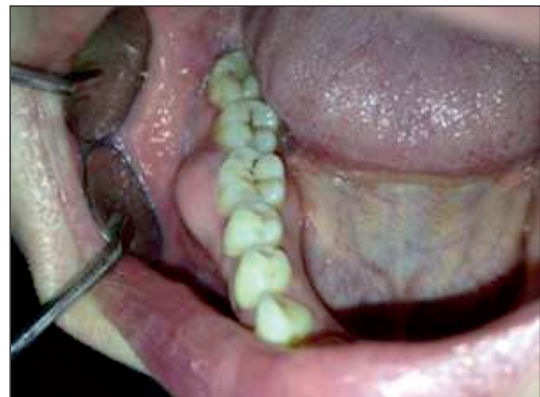

FIGURE 1: Intraoral view of the patient.

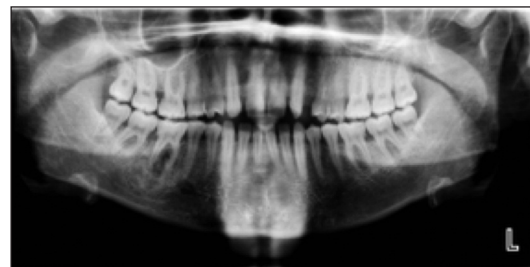

FIGURE 2: Panoramic radiography of the patient.

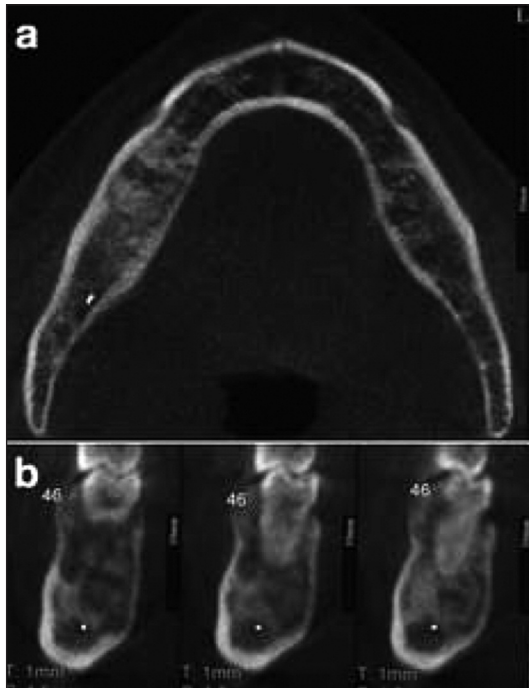


FIGURE 3: Computed tomography views **a)** axial view showing the mixed lesion in the right mandible, **b)** Cross-sectional views show the lesion causing thinning of buccal and lingual cortical bone.

Findings suggestive of a malignancy were not observed, and the histological diagnosis revealed that the tissue was compatible with a benign fibro-osseous lesion. The patient was diagnosed with COF, which was also compatible with clinical findings. At six months follow-up, the patient had no pain or swelling, but panoramic radiography demonstrated a well-defined, mixed, radiopaque-radiolucent lesion with a radiolucent border (Figure 5). Another excisional biopsy was performed, which was histologically diagnosed as recurrent COF of oral cavity. After one year of follow-up from the second surgery, there was no evidence of recurrence.

DISCUSSION

COF is a benign fibro-osseous lesion of the mandible that is more frequently found in females during the 2nd through 4th decades of life.^{1,6} The most prominent features are the buccal and lingual expansion and growth up to the lower limit of the mandible. These lesions are usually asymptomatic, but may cause asymmetrical swelling with a no-

ticeable deformity. The majority of these lesions occur in the premolar-molar area, and the adjacent teeth are replaced.¹² When the lesion reaches a large size; it may result with tooth resorption, locational changes and erosion of the mandible.

Radiologically, cemento-ossifying fibroma presents in various patterns, depending on the degree of mineralization. In early stages, the lesion is radiolucent, with no evidence of internal radiopacity, but as it matures, the internal calcification increases, and the radiolucency becomes flecked with opacities and ultimately appears as a uniform radiopaque mass.^{4,7}

The differential diagnosis of COF should include fibrous dysplasia and other fibro-osseous lesions. COF is often misdiagnosed as focal cemento-osseous dysplasia (FCOD), which displays similar radiological findings. However, FCOD lesions are smaller than COF lesions, they are observed around the roots of mandibular teeth and do not cause bone expansion. Contrarily, COF is an aggressive lesion that causes cortical expansion and often leads to the separation of the teeth. It should be kept in mind that both lesions may exhibit similar histopathological features.^{1,2,13}

In completely radiolucent lesions, the differential diagnosis should be made considering lesions that reveal radiographically similar appearances, such as odontogenic cyst, periapical granuloma, traumatic bone cyst, unilocular ameloblastoma and central giant cell granuloma. In mixed lesions, the differential diagnosis should include an osteoblastoma, calcifying cystic odontogenic tumour and calcifying epithelial odontogenic tumour. For ra-

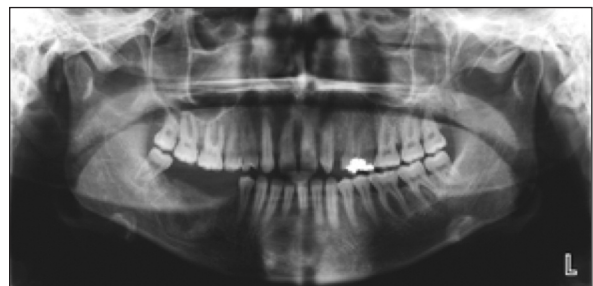

FIGURE 5: At six months follow-up panoramic radiography demonstrates well defined radiopaque-radiolucent lesion.

diopaque lesions, the preliminary radiographic diagnosis should include complex coupled odontoma and idiopathic osteosclerosis. In addition, COF with a very large size may be misdiagnosed as an osteogenic sarcoma.^{13,14}

There are two histological types of cemento-ossifying fibromas that are indistinguishable both clinically and radiologically. The histopathological features of COF consist of cement-like material and metaplastic bone.⁵ Moreover, histological parameters that are specific for COF have been defined clearly and do not show any major changes. This specific histomorphological appearance facilitates the differential diagnosis from other fibro-osseous lesions.¹²

For a definitive diagnosis of COF, the clinical, radiographic and histopathological findings should be considered altogether. Today, in the absence of specific clinical and radiographic findings, pathologists avoid a definite diagnosis, and they usually inform of their general opinion, such as a benign fibro-osseous lesion.^{4,10} When considering the unsuitable treatments, this is advocated as the most acceptable approach.¹⁵

The treatment of COF consists of enucleation by curettage or radical surgery. Although there are many advantages to a conservative treatment, in order to avoid or minimize the recurrence, a partial or bloc resection of the jaw is preferred for the larger lesions.¹⁶ Despite the fact that the recurrence rate of benign tumours appears to be extremely

low, this rate has been reported as 10-28% after enucleation and 5% after resection.^{17,18} In this case report, surgical enucleation with curettage was preferred for the treat COF lesion.

The clinical, radiographic and pathological findings of a COF should be considered altogether in order to determine the correct diagnosis and treatment. In addition, all treated COF cases should be strictly followed up. Recurrent cases should be treated aggressively, followed by reconstruction of the defect, if necessary.

Source of Finance

During this study, no financial or spiritual support was received neither from any pharmaceutical company that has a direct connection with the research subject, nor from a company that provides or produces medical instruments and materials which may negatively affect the evaluation process of this study.

Conflict of Interest

No conflicts of interest between the authors and / or family members of the scientific and medical committee members or members of the potential conflicts of interest, counseling, expertise, working conditions, share holding and similar situations in any firm.

Authorship Contributions

Idea/Concept: Yasin Yaşa; **Design:** İbrahim Şevki Bayrakdar; **Control/Supervision:** Ahmet Berhan Yılmaz; **Data Collection and/or Processing:** Adnan Kılınc; **Analysis and/or Interpretation:** Yasin Yaşa; **Literature Review:** Selin Yeşiltepe; **Writing the Article:** Selin Yeşiltepe; **Critical Review:** Ahmet Berhan Yılmaz; **Materials:** Cemal Gündoğdu.

REFERENCES

- White SC, Pharoah MJ. Oral Radiology: Principles and Interpretation. 7th ed. St. Louis, Missouri: Elsevier; 2014. p.679.
- Chi AC, Damm DD, Neville BW, Allen CM, Bouquot J. Oral and Maxillofacial Pathology. 3rd ed. Philadelphia: WB Saunders; 2008. p.984.
- Slootweg PJ, El Mofty SK. Ossifying fibroma. In: Barnes L, Eveson JW, Reichart P, Sidransky D, eds. World Health Organization Classification of Tumours: Pathology & Genetics Head and Neck Tumours. Lyon: WHO Press; 2005. p.319-20.
- Gondivkar SM, Gadbaile AR, Chole R, Parikh RV, Balsaraf S. Ossifying fibroma of the jaws: report of two cases and literature review. Oral Oncol 2011;47(9):804-9.
- Chang CC, Hung HY, Chang JY, Yu CH, Wang YP, Liu BY, et al. Central ossifying fibroma: a clinicopathologic study of 28 cases. J Formos Med Assoc 2008;107(4):288-94.
- Sarwar HG, Jindal MK, Ahmad SS. Cemento-ossifying fibroma--a rare case. J Indian Soc Pedod Prev Dent 2008;26(3):128-31.
- Triantafyllidou K, Venetis G, Karakinaris G, Iordanidis F. Ossifying fibroma of the jaws: a clinical study of 14 cases and review of the literature. Oral Surg Oral Med Oral Pathol Oral Radiol 2012;114 (2):193-9.
- Doğan N, Durmaz CE, Okcu KM, Şencimen M, Özlem Ü. Fibro-osseous lesions of the jaws: report of three cases. Turkiye Klinikleri J Dent Sci 2007;13(3):146-52.
- Akcam T, Altug HA, Karakoc O, Sencimen M, Ozkan A, Bayar GR, et al. Synchronous ossifying fibromas of the jaws: a review. Oral Surg Oral Med Oral Pathol Oral Radiol 2012;114(5 Suppl):S120-5.
- Swami AN, Kale LM, Mishra SS, Choudhary SH. Central ossifying fibroma of mandible: a case report and review of literature. J Indian Acad Oral Med Radiol 2015;27(1):131-5.
- Knutsen BM, Larheim TA, Johannessen S, Hillestad J, Solheim T, Koppang HS. Recurrent conventional cemento-ossifying fibroma of the mandible. Dentomaxillofac Radiol 2002;31(1):65-8.
- Sopta J, Dražić R, Tulić G, Mijucić V, Tepavčević Z. Cemento-ossifying fibroma of jaws-correlation of clinical and pathological findings. Clin Oral Investig 2011;15(2):201-7.
- Monahan R, Zhao L. Maxillofacial imaging. In: Taub PJ, Patel PK, Buchman SR, Cohen M, eds. Ferraro's Fundamentals of Maxillofacial Surgery. 2nd ed. New York: Springer; 2015. p.91-101.
- Petrikowski GC. Ossifying fibroma. In: Koenig LJ, Tamimi D, Petrikowski GC, Perschbacher SE, eds. Diagnostic Imaging: Oral and Maxillofacial. 2nd ed. Philadelphia, PA: Elsevier; 2017. p.436-9.
- MacDonald-Jankowski DS. Fibro-osseous lesions of the face and jaws. Clin Radiol 2004; 59(1):11-25.
- Trijolet JP, Parmentier J, Sury F, Goga D, Mejean N, Laure B. Cemento-ossifying fibroma of the mandible. Eur Ann Otorhinolaryngol Head Neck Dis 2011;128(1):30-3.
- Ertuğ E, Meral G, Saysel M. Cemento-ossifying fibroma: a case report. Quintessence Int 2004;35(10):808-10.
- Eversole LR, Leider AS, Nelson K. Ossifying fibroma: a clinicopathologic study of sixty-four cases. Oral Surg Oral Med Oral Pathol 1985;60(5):505-11.