




Alternative Prosthodontic Rehabilitation of Traumatic Patients with Tooth, Bone and Soft Tissue Loss: Two Clinical Reports

Diş, Kemik ve Yumuşak Doku Kaybı Olan Travma Hastalarında Alternatif Prostodontik Rehabilitasyon

 Gülsüm SAYIN ÖZEL,^a
 Özgür İNAN,^b
 Doğan DOLANMAZ^c

^aDepartment of Prosthodontics,
Istanbul Medipol University
Faculty of Dentistry,
Istanbul

Departments of,
^bProsthodontics,

^cOral Maxillofacial Surgery,
Selcuk University Faculty of Dentistry,
Konya

Received: 12.02.2017

Received in revised form: 11.09.2017

Accepted: 18.09.2017

Available online: 06.07.2018

Correspondence:

Gülsüm SAYIN ÖZEL

Istanbul Medipol University

Faculty of Dentistry,

Department of Prosthodontics, Istanbul,

TURKEY/TURKİYE

gozel@medipol.edu.tr

ABSTRACT Acquired defects typically result from traumatic injuries such as falls, motor vehicle accidents, gunshot injuries or radiation injuries. Those maxillofacial defects resulting from motor vehicle accidents in particular often involve various soft and hard-tissue injuries such as fractures or avulsions of the maxillary or mandibular teeth or fractures of the temporomandibular joints. For a patient suffering such injuries, the retention and stabilization of a prosthesis that contributes to the patient's physical and psychological well-being are often difficult to achieve due to the nature of the moveable tissue beds involved and the resulting lack of support from the remaining teeth and bones. This clinical report describes the treatments of two partially edentulous patients with traumatic injuries that resulted from motor vehicle accidents. The prosthetic rehabilitations were accomplished through the manufacture of (1) a mandibular prosthesis with an extracoronary bar attachment, and (2) a maxillary implant-supported removable prosthesis.

Keywords: Injuries; dental prosthesis design; dental prosthesis, implant-supported; dental prosthesis retention

ÖZET Sonradan ortaya çıkan maksillofasyal defektler; düşme, motorlu taşıt kazaları, ateşli silah yaralanmaları ya da radyasyon yaralanmaları gibi genellikle travmalardan kaynaklı olurlar. Motorlu taşıt kazaları çeşitli fraktürleri ve avülzyonları içeren yumuşak ve sert doku kayıplarını içerirler. Bu tür hastalar için fiziksel ve psikolojik iyi hissetmelerini sağlayacak protezlerin retansiyon ve stabilitesini elde etmek, hareketli yumuşak doku alanlarından ve destek diş ile kemik dokusunun azalmasından dolayı çok zordur. Bu klinik raporda, iki travmatik hastanın alternatif tedaviler ile rehabilitasyonu anlatılmaktadır. Vaka 1 için eksternal koronal bar ataçmanlı mandibuler protez, Vaka 2 için maksiller implant destekli hareketli bölümlü protez ile rehabilitasyon yapılmıştır ve bu protezlerin avantajlarından bahsedilmiştir.

Anahtar Kelimeler: Yaralanmalar; diş protez tasarımı; diş protezi, implant destekli; diş protez retansiyon

Extensive maxillofacial defects can be caused by trauma, congenital and acquired anomalies, or diseases.¹ With specific regard to defects caused by trauma, such injuries may result from mechanical, electrical or chemical agents or from radiation and heat. Some examples of mechanically-caused traumas are motor vehicle accidents, gunshot injuries and falls.²

Motor vehicle accidents not only risk trauma to anterior teeth but also to the soft and hard tissue support of these teeth.³ Such accidents can lead to neurological problems; fractures to the maxillary and/or mandibular teeth; and avulsions or fractures of the temporomandibular joint.⁴ These

traumatic defects can negatively affect retention and stabilization of the prosthesis because of movable soft tissue, the absence of adequate tooth and bone support, or both.⁵ A nonstable and non-retentive prosthesis can negatively influence a patient's psychological situation and daily life. Implant-supported prostheses or alternative prosthetic designs may present an opportunity to improve prosthodontic support.^{6,7}

In the case of large defects, removable dentures are preferable for trauma patient rehabilitation, as well as for restoration of inadequate tissues. In addition, the rehabilitation of trauma patients through implant-supported prostheses may present more effective treatment options. Implant-supported removable prostheses offer many advantages such as improved retention, stability, patient satisfaction, and conservation of present soft and hard tissues.^{5,8,9}

This paper describes a step-by-step approach to the protocol applied to two trauma patients who each suffered the loss of various hard and soft tissues.

CASE REPORTS

63 year-old male patient and 51 year-old female patient have applied to Selcuk University, Faculty of Dentistry for rehabilitation of traumatic defects. Patients were treated in Oral and Maxillofacial Sur-

gery and Prosthodontic Department in Selcuk University. All the treatments protocols had explained to the patients with patient information form for both patients.

PATIENT 1

Patient 1 was a 63-year-old male whose history included a motor vehicle accident – specifically a crash while driving a dipper dredger – which resulted in numerous fractures and injuries. The patient was referred to the Selcuk University Faculty of Dentistry for dental rehabilitation. Traumatological urgent treatment was performed at the Selcuk University Faculty of Dentistry, Department of Oral and Maxillofacial Surgery. Bone fracture reduction and fixation were achieved through the use of reconstruction miniplates and screws. In accordance with prior medical reports, no intracranial pathologic condition was observed (Figure 1).

Patients had suffered phonetic and functional problems as well as aesthetic problems. Extraoral examinations revealed that patient suffered facial scar tissues on the lips and nose. Intraoral examination indicated that several teeth had been damaged throughout the associated alveolar ridges as a result of their injuries.

The remaining dentition included eight teeth in the maxillary arch and four teeth in the

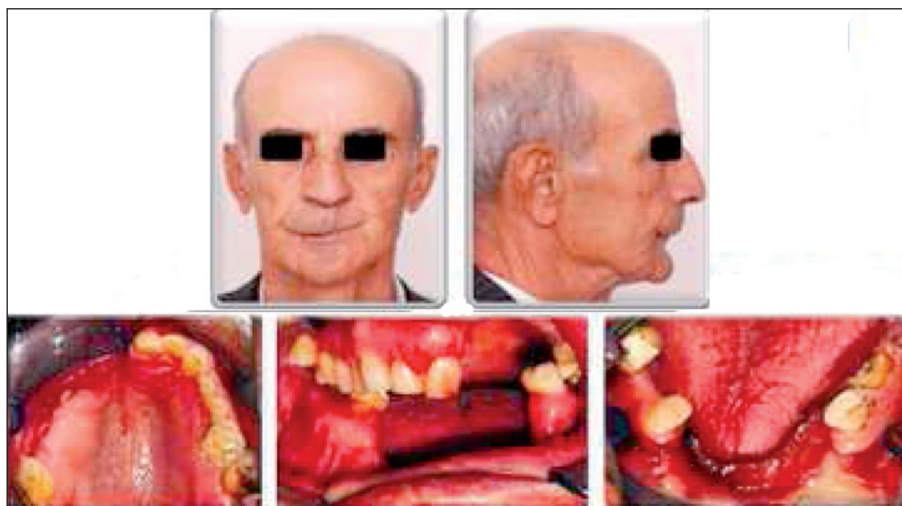


FIGURE 1: Extraoral and intraoral view of the Patient 1 before the treatment.

mandibular arch. After completion of the medical and dental histories and the clinical and radiographical examinations, a periodontal treatment was applied for the patient prior to prosthodontic treatment.

In Patient 1's case, the left maxillary premolars were restored after a crown fracture, and the four mandibular teeth received endodontical treatment. Several different restorative options were discussed. Initially, an implant treatment was proposed, but Patient 1 declined surgical operations because he had undergone unseveral prior surgeries which resulted in psychological and financial difficulties (Figure 2).

After radiographical and clinical examination, treatment plan was made for a maxillary removable partial denture and for a mandibular bar-attached removable full-arch denture according to the diagnostic models. Bone loss in the anterior mandible resulted in increased interocclusal dimension and

decreased inferior lip support. With a removable full arch denture, these conditions are solvable. After endontic treatment for all four teeth was completed, post-core restorations were made for the three mandibular teeth. Because the environmental bone level of the mandibular teeth was low, those teeth were splinted by a bar attached to the crowns of the abutments to improve the patient's prognosis. The bar would allow for the occlusal load along the long axis of the abutment teeth. It would also split the teeth and improve stability so that the marginal gingiva could not be traumatised and would be accessible for cleaning.

Displacement of the facial bones and teeth resulted in the following: supraerupted teeth, deviant occlusal contacts, and a failure to achieve maximal intercuspation. Accordingly, shoulder finish lines were constituted for the abutment teeth as preparation in order to provide support for the prosthesis and to restore the occlusion. The right maxillary first and second molars and the left second molar were intact and were not needed as abutments. The impressions were taken using hydrophilic vinyl polysiloxane (Virtual, Ivoclar Vivadent, Liechtenstein), a fixed prosthesis was fabricated (CrNi %1 Si/ Be -Fe free (Kera N, Eisenbacher dentalwaren, Germany-Vita VM 15, Zahnfabrik, Switzerland). The bar was fabricated (CrNi %1 Si/Be-Fe free (Kera N, Eisenbacher dentalwaren, Germany) by using prefabricated bars (titanium bars, MIS ltd, Israel) (Figure 3). After the adjustment of the metal-ceramic FPDs and bar, the impressions (Lascod SpA, Fierenze, Italy) for the removable prostheses were taken with custom impression trays (Meliodent rapid repair, Heraeus Kulzer, Australia). After trial evaluation of the metal frameworks of the removable prostheses with the attachments (64% Co, 28,5% Cr, 8% Fe, 3% Mo Wironit, Bego, Germany), the artificial teeth (Vitapan; Vita Zahn-fabrik, Switzerland) were controlled, and the occlusion was constituted to ensure harmony with the metal-ceramic FPDs. The wax trial dentures were then evaluated intraorally. Extraorally lip support and profile changes were evaluated. Acrylic dentures were completed using heat-cured acrylic resin (Meliodent, Heraeus Kulzer, Australia) (Figure 4).

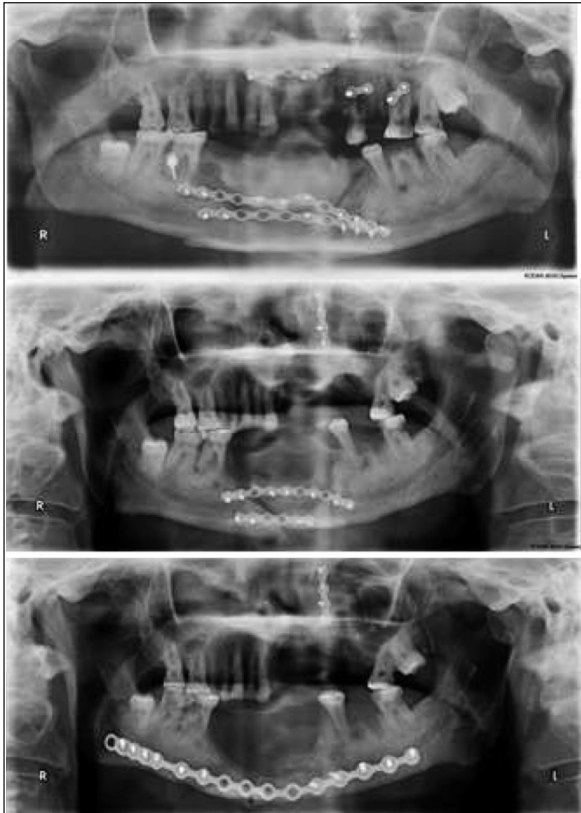

FIGURE 2: Panoramic radiographs showing mini plates and screws used for fixing fractured maxilla and mandibula for Patient 1.

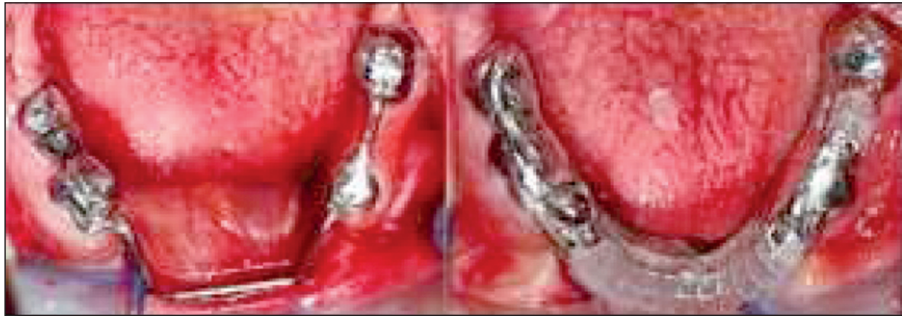

FIGURE 3: Trial evaluation of the bar and framework for Patient 1.

PATIENT 2

Patient 2 was a 51-year-old female patient who suffered an automobile accident approximately thirty years before and was referred to the Selcuk University Faculty of Dentistry for dental rehabilitation. As a result of her accident, Patient 2

suffered a maxillary bone fracture and the loss of bone, soft tissue and teeth, as well as a defect in the premaxillary region. After the accident, a maxillary removable partial prosthesis and mandibular fixed partial prosthesis were applied (Figure 5).

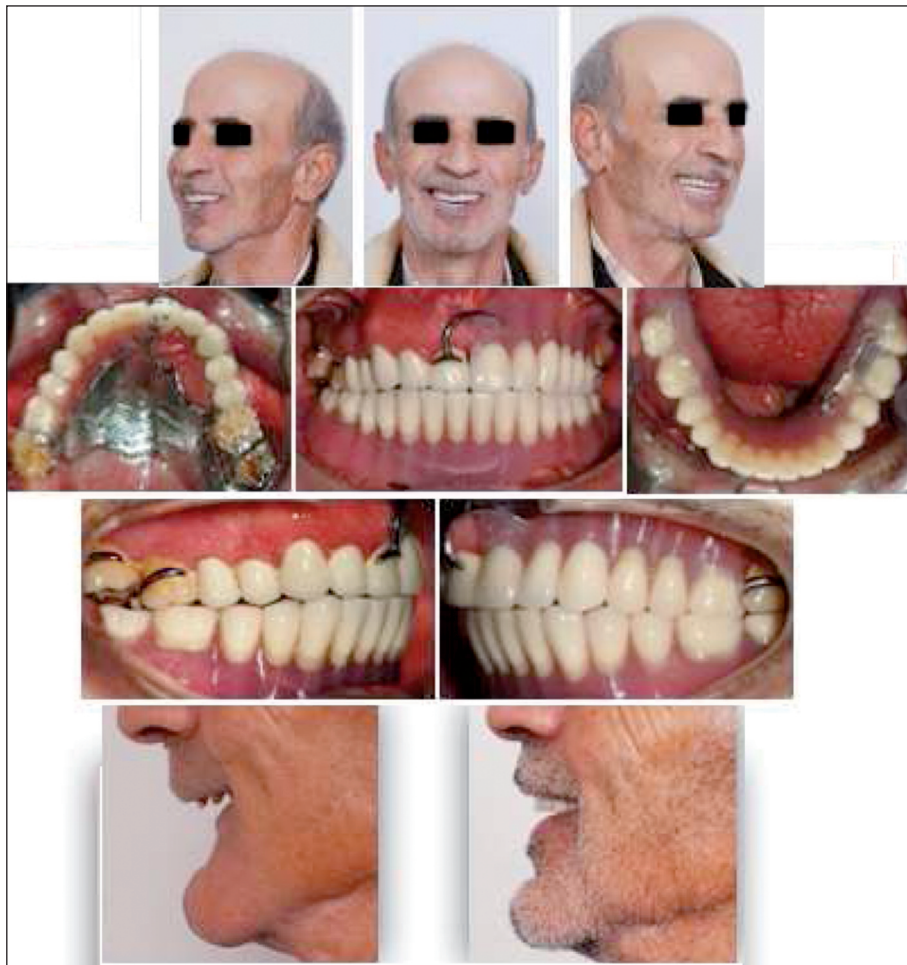


FIGURE 4: Final restorations of Patient 1. Acrylic resin was used to compensate for the loss of hard and soft tissue and lip support for Patient 1.

Patients had suffered phonetic and functional problems as well as aesthetic problems. Extraoral examinations revealed that patient suffered facial scar tissues on the lips and nose. Intraoral examination indicated that several teeth had been damaged throughout the associated alveolar ridges as a result of their injuries.

The remaining dentition included two teeth in the maxillary arch for Patient 2. After completion of the medical and dental histories and the clinical and radiographical examinations, a periodontal treatment was applied for the patient prior to prosthodontic treatment.

For Patient 2, the old prosthesis was removed, revealing that the right maxiller 2 molar had a apical lesion. Endodontical treatment had been attempted, but the attempt was unsuccessful and was extracted. The mandibular right canine was treated endodontically, and older amalgam fillings were restored due to secondary caries. Several different

restorative options were then discussed. Ultimately, an implant treatment was planned for a full-arch completely-fixed prosthesis. Due to bone loss, a distraction osteogenesis was recommended, but because of several prior surgical operations which resulted in psychological and financial difficulties, Patient 2 declined to undergo any surgical operations. Instead, a full-arch completely-fixed mandibular prosthesis and a set of implant-supported removable partial maxillary dentures were planned. If Patient 2 subsequently desires a full-arch implant-supported completely-fixed maxillary prosthesis, it will be possible to use the maxillary implants for that purpose as well as any additional implants placed surgically. This technique also provides protection for the posterior maxillary bone and improves stability for the prosthesis.

Two implants in the right maxillary region were placed using a two-stage surgical protocol.

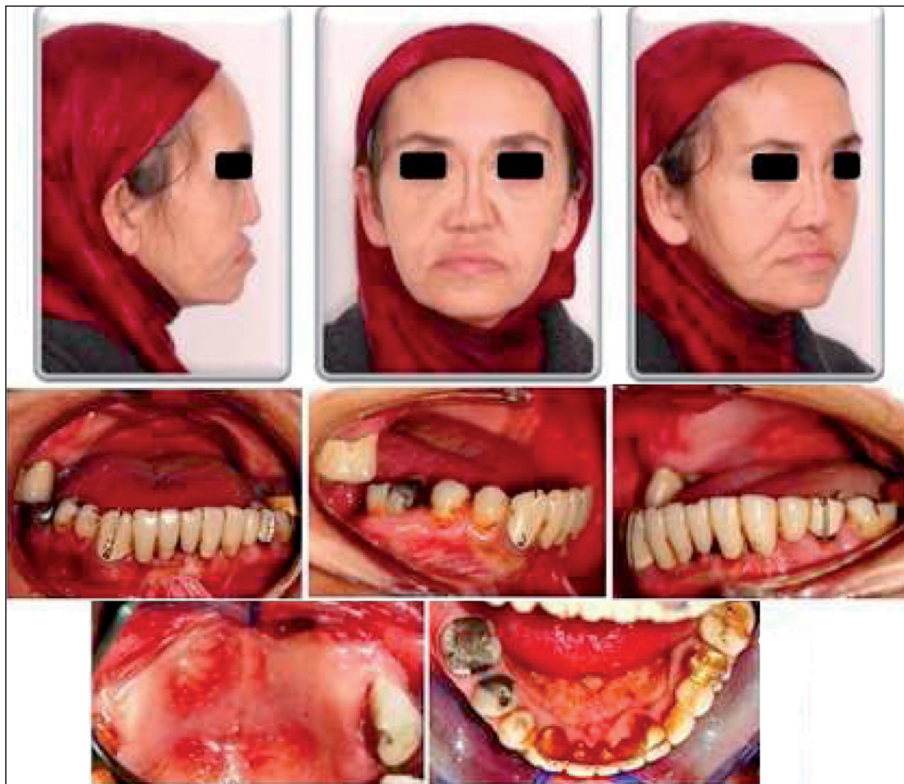

FIGURE 5: Extraoral and intraoral view of the Patient 2 before the treatment.

The implants were 5 mm and 4.2 mm in diameter and 10 mm in length (Seven, MIS, Israel). After six months of osseointegration for the implants and healing period for the soft tissues, the patient was referred for prosthetic rehabilitation (Figure 6).

The impressions were taken by using hydrophilic vinyl polysiloxane (Virtual, Ivoclar Vivadent, Liechtenstein), a fixed prosthesis was fabricated (CrNi 1% Si/ Be -Fe free (Kera N, Eisenbacher dentalwaren, Germany-Vita VM 15, Zahnfabrik, Switzerland). After the adjustment of the metal-ceramic fixed partial dentures, two ball attachments were connected to the implants, with one at a gingival height of 3 mm and the other at a height of 5 mm. Ball attachment type was preferred because of the limited interdental space, bar attachments required more interdental space than unsplinted attachments. The impressions (Flexitime, Heraeus Kulzer, Australia) for the removable prostheses were taken by custom impression trays (Meliodent rapid repair, Heraeus Kulzer, Australia). After a trial evaluation of the metal framework for the removable prostheses (64% Co, 28.5% Cr, 8% Fe, 3% Mo Wironit, Bego, Germany) (Figure 7), the artificial teeth (Vitalumin Vacuum; Vita Zahn-fabrik, Switzerland) were

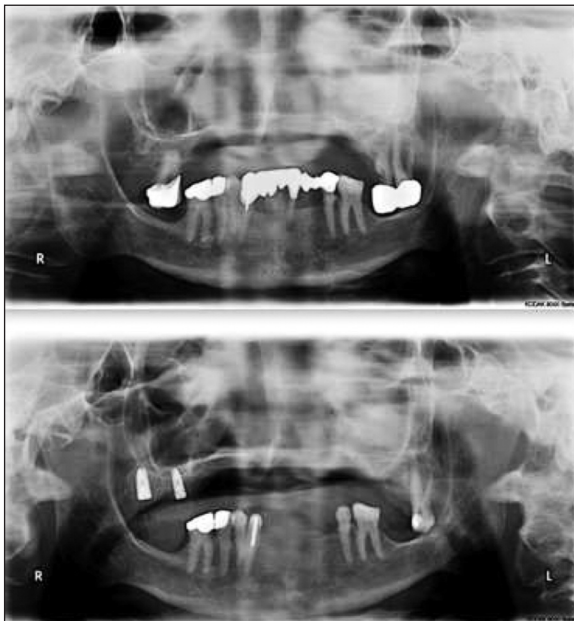


FIGURE 6: Panoramic radiographs before and after the treatment for Patient 2.

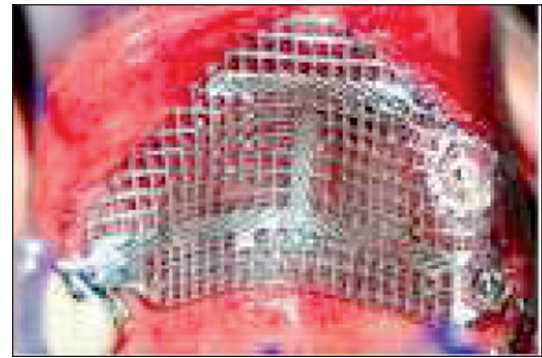


FIGURE 7: Trial of implant supported removable partial denture framework for Patient 2.

arranged, and the occlusion was established to provide harmony with the metal-ceramic FPDs. The wax trial dentures were then evaluated intraorally. Lip support and occlusion were evaluated in this stage. Acrylic dentures were finished using a heat-cured acrylic resin (Meliodent, Heraeus Kulzer, Australia) (Figure 8).

DISCUSSION

Maxillofacial defects resulting from traumatic injuries may give rise to impairments in phonation, mastication, swallowing, and aesthetic appearance.¹⁰ Consequently, these impairments may have a significant psychological impact on the patients. For trauma patients, prosthetic rehabilitations are often ineffective treatments due of the presence of scar tissue, nonmucous soft tissue and insufficient vestibule. Although acceptable aesthetic results may be obtained, prosthetic stability is more difficult to achieve.^{10,11} Additionally, the limited interarch distance may inhibit operative procedures. For those reasons, the placement of either a conventional removable or fixed prosthesis is not offered in trauma patients, and alternative treatments for increasing stability and retention are preferred.^{12,13}

The primary goal in the prosthetic rehabilitation of trauma patients with severe bone and soft tissue defects is to obtain a prosthesis that achieves both full patient satisfaction and easy access for cleaning.¹⁴ Through alternative treatments, removable prostheses and implant-retained overden-

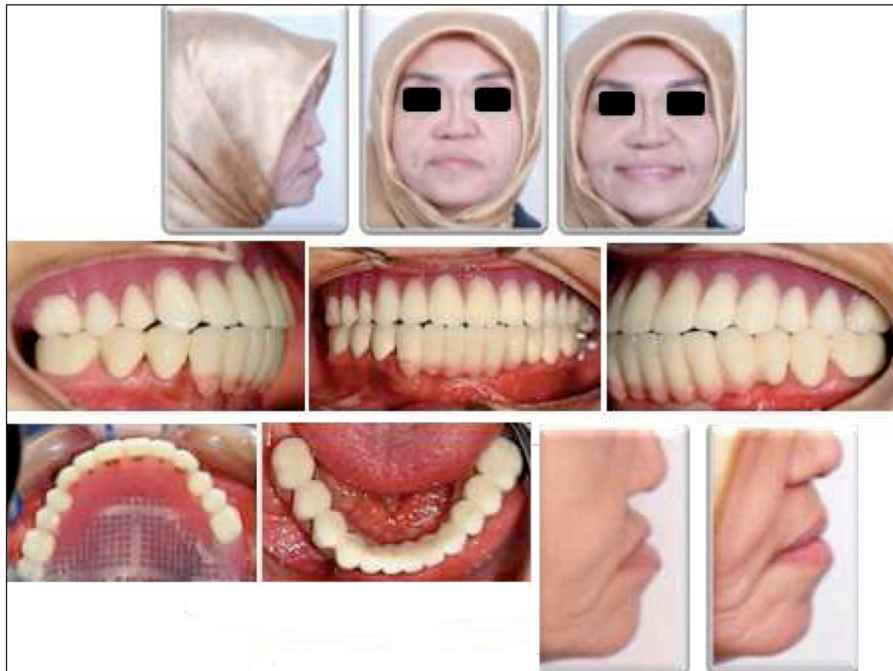

FIGURE 8: Final restorations of Patient 2. Acrylic resin was used to compensate for the loss of hard and soft tissue and lip support.

tures are an effective means of oral rehabilitation for trauma patients. One of the primary reasons given by our patients for choosing a removable prosthesis over a fixed prosthesis is the relative ease of maintenance and cleaning.^{15,16} Studies have shown that patients with removable prostheses were pleased with how easy it was to clean them.^{17,18} On the other hand, Walton & MacEntee stated that patient satisfaction for fixed implant-supported prostheses was reduced because of the comparative difficulty of cleaning.¹⁵ Although it was difficult for the patient to maintain good oral hygiene due to scar tissue around the mouth, neither mucositis nor gingival hyperplasia have been observed during recalls.

Dental implants also increase prosthetic retention, stability, and function in trauma patients. Due to tissue effects, it is often impossible to achieve the optimal implant position, but a removable implant-retained prosthesis can compensate for suboptimal implant positions and locations.¹⁹ Patient 2 suffered bone loss in the premaxillary region, and augmentation of the premaxillary bone was initially to be achieved through distraction os-

teogenesis. However, Patient 2 refused further surgical procedures, and so we elected to use implant-retained removable partial denture to ensure the patient's satisfaction.

Feine et al. reported that patient behaviours should be taken into consideration when designing a prosthesis for an individual patient.¹⁷ This was the main cause of the treatment modality difference between Patients 1 and 2. Retention capacity was also a major factor in the selection of the attachment type. Naert et al. noted that in comparison with the bar, ball and magnet attachments; the bar attachments exhibited the highest retention capacity.²⁰ Both patients rejected further surgical operations, and so a bar-attached removable prosthesis was used for the reconstruction in Patient 1 and implant-retained removable partial denture was used for the reconstruction in Patient 2. During the recalls, no retention problem were observed for either patient. In addition to the other benefits described above, the use of removable prostheses provides lip and cheek support and acceptable aesthetic appearance.^{9,21}

CONCLUSION

When dealing with major maxillary and mandibular defects, a detailed treatment plan and evaluation of each individual case may reduce the difficulty of prosthetic rehabilitation. All alternative treatment options should be evaluated according to the patient's needs. This paper describes the oral rehabilitations of two patients with post-trauma defects. Through the use of alternative removable prostheses, the treatment resulted in aesthetic and functional advantages for rehabilitation of these two trauma patients. Each patients's profile was improved to a certain degree by achieving lip and cheek support. The definitive prosthetic rehabilitation improved aesthetics and function of the two patients and presented favorable prognoses.

Source of Finance

During this study, no financial or spiritual support was received neither from any pharmaceutical company that has a

direct connection with the research subject, nor from a company that provides or produces medical instruments and materials which may negatively affect the evaluation process of this study.

Conflict of Interest

No conflicts of interest between the authors and / or family members of the scientific and medical committee members or members of the potential conflicts of interest, counseling, expertise, working conditions, share holding and similar situations in any firm.

Authorship Contributions

Idea/Concept: Özgür İnan, Doğan Dolanmaz; **Design:** Gülsüm Sayın Özel, Özgür İnan, Doğan Dolanmaz; **Control/Supervision:** Özgür İnan, Doğan Dolanmaz; **Data Collection and/or Processing:** Gülsüm Sayın Özel, Özgür İnan; **Analysis and/or Interpretation:** Gülsüm Sayın Özel, Özgür İnan; **Literature Review:** Gülsüm Sayın Özel; **Writing the Article:** Gülsüm Sayın Özel; **Critical Review:** Özgür İnan, Doğan Dolanmaz; **References and Fundings:** Gülsüm Sayın Özel; **Materials:** Gülsüm Sayın Özel, Özgür İnan.

REFERENCES

- Rogers SN, Lowe D, McNally D, Brown JS, Vaughan ED. Health-related quality of life after maxillectomy: a comparison between prosthetic obturation and free flap. *J Oral Maxillofac Surg* 2003;61(2):174-81.
- Balshi TJ. Oral prosthodontic rehabilitation for traumatic sports injuries. *Dent Clin North Am* 1991;35(4):771-96.
- Cakan U, Anil N, Aslan Y. Prosthetic rehabilitation of a mandibular gunshot defect with an implant-supported fixed partial denture: a clinical report. *J Prosthet Dent* 2006;95(4):274-9.
- Wiens JP. Acquired maxillofacial defects from motor vehicle accidents: statistics and prosthodontic considerations. *J Prosthet Dent* 1990;63(2):172-81.
- LoranEsfahani V, Monzavi A. Implant-supported prosthodontic rehabilitation after maxillary dentoalveolar trauma. *Int J Dental Clinics* 2012;4(4):37-8.
- Tuna EB, Ozgen M, Cankaya AB, Sen C, Gencay K. Oral rehabilitation in a patient with major maxillofacial trauma: a case management. *Case Rep Dent* 2012;2012:267143.
- Uğurlu K, Sacak B, Hüthüt I, Karsıdag S, Sakiz D, Baş L. Reconstructing wide palatomaxillary defects using free flaps combining bare serratus anterior muscle fascia and scapular bone. *J Oral Maxillofac Surg* 2007;65(4):621-9.
- Evren BA, Basa S, Ozkan Y, Tanyeri H, Ozkan YK. Prosthodontic rehabilitation after traumatic tooth and bone loss: a clinical report. *J Prosthet Dent* 2006;95(1):22-5.
- Uludag B, Sahin V, Celik G. Fabrication of a maxillary implant-supported overdenture retained by two cemented bars: a clinical report. *J Prosthet Dent* 2007;97(5):249-51.
- Mou SH, Chai T, Shiau YY, Wang JS. Fabrication of conventional complete dentures for a left segmental mandibulectomy patient: a clinical report. *J Prosthet Dent* 2001;86(6):582-5.
- Devlin H, Barker GR. Prosthetic rehabilitation of the edentulous patient requiring a partial maxillectomy. *J Prosthet Dent* 1992;67(2):223-7.
- Brognez V, Lejoste P, Pecheur A, Reyckler H. Dental prosthetic reconstruction of osseointegrated implants placed in irradiated bone. *Int J Oral Maxillofac Implants* 1998;13(4):506-12.
- Kornblith AB, Zlotolow IM, Gooen J, Huryn JM, Lerner T, Strong EW, et al. Quality of life of maxillectomy patients using an obturator prosthesis. *Head Neck* 1996;18(4):323-34.
- Morton D, Fridrich K, Aquilino SA, Fridrich TA. Interdisciplinary treatment of severe maxillofacial trauma: a clinical report. *J Prosthet Dent* 2000;84(2):133-5.
- Walton JN, MacEntee MI. A retrospective study on the maintenance and repair of implant-supported prostheses. *Int J Prosthodont* 1993;6(5):451-5.
- Chan MF, Johnston C, Howell RA, Cawood JI. Prosthetic management of the atrophic mandible using endosseous implants and overdentures: a six year review. *Br Dent J* 1995;179(9):329-37.
- Feine JS, de Grandmont P, Boudrias P, Brien N, LaMarche C, Taché R, et al. Within-subject comparisons of implant-supported mandibular prostheses: choice of prosthesis. *J Dent Res* 1994;73(5):1105-11.

18. Kapur KK. Veterans Administration Cooperative Dental Implant Study--comparisons between fixed partial dentures supported by blade-vent implants and removable partial dentures. Part IV: comparisons of patient satisfaction between two treatment modalities. *J Prosthet Dent* 1991;66(4):517-30.
19. McAndrew R. Prosthodontic rehabilitation with a swing-lock removable partial denture and a single osseointegrated implant: a clinical report. *J Prosthet Dent* 2002;88(2):128-31.
20. Naert I, Gizani S, Vuylsteke M, Van Steenberghe D. A 5-year prospective randomized clinical trial on the influence of splinted and unsplinted oral implants retaining a mandibular overdenture: prosthetic aspects and patient satisfaction. *J Oral Rehabil* 1999;26(3):195-202.
21. Holst S, Blatz MB, Bergler M, Wichmann M, Eitner S. Implant-supported prosthetic treatment in cases with hard-and soft-tissue defects. *Quintessence Int* 2005;36(9):671-8.