

## A Case of Palmoplantar Lichen Planus Treated with Low Dose Acitretin, Followed by Lichen Planus Pigmentosus

### Düşük Doz Asitretin İle Tedavi Edilmiş ve Takiben Lichen Planus Pigmentosus Gelişmiş Bir Palmoplantar Lichen Planus Olgusu

Semih TATLİCAN, MD,<sup>a</sup>  
Bengü ÇEVİRGEN CEMİL, MD,<sup>a</sup>  
Fatma ESKİOĞLU, MD,<sup>a</sup>  
Zeliha BODUR, MD,<sup>a</sup>  
Ayşegül ADABAĞ, MD,<sup>b</sup>

Clinics of <sup>a</sup>Dermatology, <sup>b</sup>Pathology,  
Ankara Dışkapı Yıldırım Beyazıt  
Training and Research Hospital,  
ANKARA

Geliş Tarihi/Received: 16.11.2006  
Kabul Tarihi/Accepted: 10.04.2007

Yazışma Adresi/Correspondence:  
Semih TATLİCAN, MD  
Ankara Dışkapı Yıldırım Beyazıt  
Training and Research Hospital,  
Clinic of Dermatology, ANKARA  
semtatlican@yahoo.com

**ABSTRACT** Lichen planus is a disease that is classically known to involve the flexural areas of the wrists, arms, and legs. Palmoplantar lichen planus is a rare variant of lichen planus and its diagnosis could prove complicated, especially when it comes out as an isolated finding. Lichen planus pigmentosus is an uncommon variant of lichen planus, generally involving the sun-exposed areas and axillary folds. In this paper, a case of palmoplantar lichen planus is presented. It first appeared as pruritic vesicles and later developed into keratoderma, and was treated with low dose acitretin. Finally, the patient developed lichen planus pigmentosus in his axillary folds. Upon literature review, it is seen that this is the first report of such a case in that these two clinical variants of the lichen planus were seen sequentially in the same patient.

**Key Words:** Lichen planus; acitretin; keratoderma, palmoplantar

**ÖZET** Lichen planus klasik olarak el bileği, kol ve bacakların fleksör yüzlerini tutan bir hastalık olarak bilinmektedir. Palmoplantar liken planus, liken planusun nadir bir formudur ve tek başına ortaya çıktığında tanısında güçlük çekilebilmektedir. Lichen planus pigmentosus, liken planusun genellikle güneş gören bölgeleri ve aksiler kıvrımları tutan ve seyrek görülen bir klinik varyantıdır. Bu makalede bir palmoplantar liken planus olgusu sunulmaktadır. Hastalık önce kaşıntılı veziküller ile ortaya çıkmış, sonrasında keratodermaya evrilmiş ve düşük doz asitretin ile tedavi edilmiştir. Son olarak tedavi ertesinde aksiler kıvrımlarında liken planus pigmentosus ortaya çıkmıştır. Bu makale ile, liken planusun bu iki formunun aynı hastada ardışık olarak ortaya çıktığı ilk kez rapor edilmektedir.

**Anahtar Kelimeler:** Lichen planus; asitretin; keratoderma, palmoplantar

**Türkiye Klinikleri J Dermatol 2008, 18:63-66**

Palmoplantar lesions are uncommon in lichen planus and generally do not share the typical clinical features.<sup>1,2</sup> Scaly and/or hyperkeratotic well-defined erythematous plaques located on the palmar and plantar arches are usually observed.<sup>2,3</sup> Palmoplantar lesions are more resistant to therapy than other skin involvements.<sup>2,4</sup>

We present, a patient with palmoplantar lichen planus successfully treated with low-dose acitretin in this report. In follow-up period, the lesions detected in his axillary folds were diagnosed as lichen planus pigmentosus, which is also an uncommon variant of lichen planus.

In this paper, unusual clinical presentations of lichen planus and efficacy of acitretin are emphasized.

## CASE REPORT

Here a 41-year-old man with a six-month history of pruritic, yellowish papules and plaques on his palms and soles is presented. He mentioned that his complaint started as pruritic vesicles; nevertheless, at the time of administration to our clinic there were only papules and plaques in his palms and soles. He did not give any positive history of allergy, atopy or contact reaction. No infection, arsenic exposure or drug usage was present before the development of the lesions. He had used topical steroids and systemic steroids intramuscularly with some benefit. Upon general systemic examination, no abnormality was detected.

Dermatologic examination revealed well-demarcated, minimally scaling, yellowish papules and plaques on his palms and diffuse keratosis on his soles (Figure 1). No other lesion in any part of the body was detected.

Routine laboratory test results were within normal limits, serologic tests for hepatitis B and C and syphilis were negative. KOH examinations from palmar and plantar lesions were negative as well.

A biopsy specimen from a plaque on his left palm showed compact orthokeratosis, wedge-shaped hypergranulosis, irregular acanthosis in the epidermis, vacuolar alteration of the basal layer, band like lymphocytic infiltration in the upper dermis (Figure 2).

After the diagnosis of palmoplantar lichen planus both clinically and histopathologically, acitretin treatment of 35 mg per day was started. At the end of sixth week, all of the lesions completely cleared, acitretin dose was gradually reduced, and eventually stopped at the end of fourth month. In the control at the eighth month, no lesion was present on his palms and soles. However, red-brown colored, macular lesions cropped up in his right and left axillary regions (Figure 3).

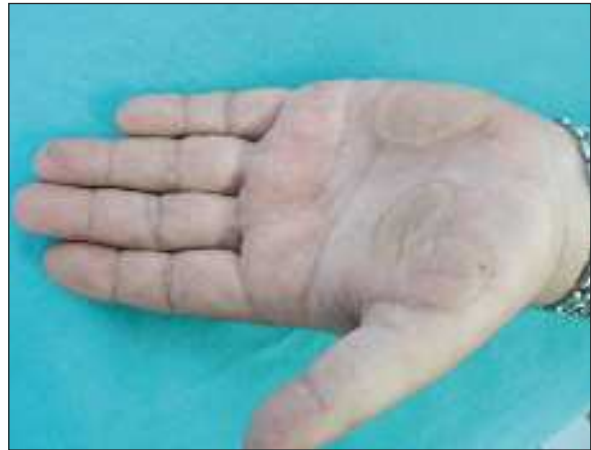A biopsy specimen from a macular lesion in the right axillary region showed hyperkeratosis, focal thickening of the granular layer and irregular elongation of the rete ridges. The infiltrate is band-

like and sharply demarcated at its lower border (Figure 4).

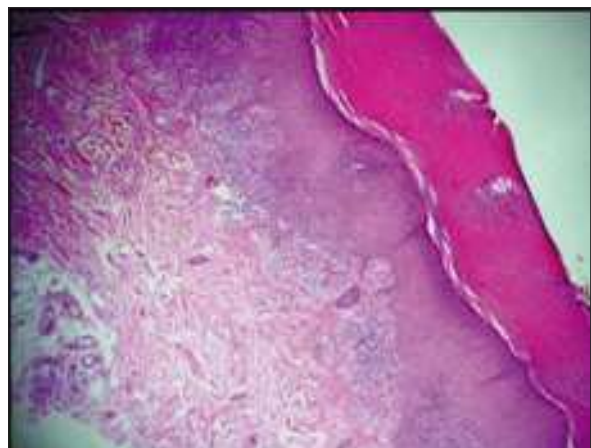
The diagnosis of lichen planus pigmentosus was made clinically and confirmed histologically, and topical steroid treatment was started.

## DISCUSSION

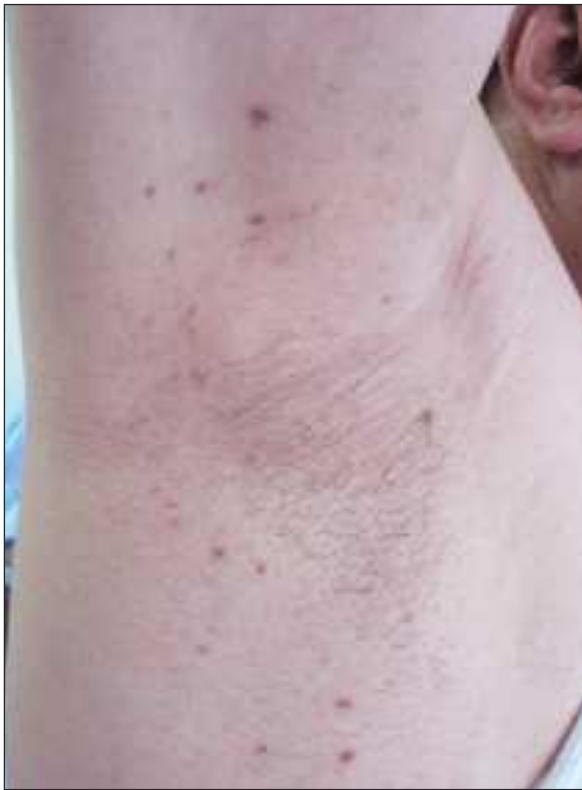Lichen planus is a unique, common inflammatory disorder that affects the skin, mucous membranes, nails, and hair.<sup>1</sup> Lichen planus appears in various clinical variants which are categorized according to the site of involvement, morphology and confi-



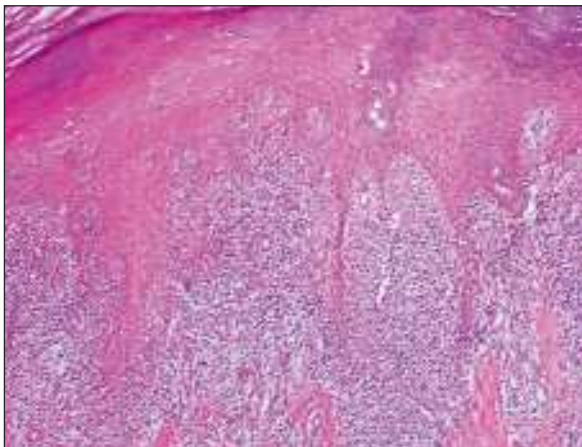
**FIGURE 1:** Appearance of well-demarcated, minimally scaling, yellowish plaques on his left palm.



**FIGURE 2:** Biopsy specimen that was taken from skin of left palm. Appearance of compact orthokeratosis, wedge-shaped hypergranulosis, irregular acanthosis in the epidermis, band like lymphocytic infiltration in the upper dermis (Hematoxylin-eosin stain; original magnification, x10.)



**FIGURE 3:** Appearance of red-brown colored macular lesions in his right axillary region.



**FIGURE 4:** Biopsy specimen that was taken from the skin of right axillary region. Appearance of hyperkeratosis, focal thickening of the granular layer, irregular elongation of the rete ridges and the bandlike infiltration. (Hematoxylin-eosin stain; original magnification, x100.)

guration of lesions.<sup>1</sup> Lichen planus of the palms and soles is relatively uncommon and this variant of the disease may create difficulty in diagnosis if present as an isolated finding.<sup>1,5</sup>

The clinical forms of palmoplantar lichen planus described in literature are characterized with erythematous scaly plaques, punctuate and diffuse keratodermas, ulcerative lesions, erosive lesions, vesicles and vesicle-like papules.<sup>2-4,6-9</sup>

The most observed pattern is compact, hyperkeratotic papules and plaques.<sup>1-3</sup> In this form, lesions are seen on the lateral margins of the fingers and hand surfaces, and are surrounded by an inflammatory, erythematous halo.<sup>1-3</sup> The differential diagnosis of this form includes psoriasis vulgaris, warts, calluses, prokeratosis, hyperkeratotic eczema, tinea, and secondary syphilis.<sup>1</sup>

Our patient had compact hyperkeratotic lesions on his palms and diffuse hyperkeratosis on his soles at the time of administration.

However, he described vesicles or vesicle-like lesions in his history. It is acknowledged that vesicle and blister formation may occur in lichen planus if the inflammatory reaction is severe.<sup>2</sup> The fact that multiple variants can be seen simultaneously in the same patient is also cited in the literature.<sup>6</sup> Therefore, an explanation would be that topical or intramuscular steroid use, considering its anti-inflammatory effects, might have cleared lesions and after a period the vesicles and / or vesicle-like papules were changed into keratoderma.<sup>2,3</sup>

The choice for the treatment was acitretin, for the patient had used topical and intramuscular steroids with not so much benefit. The standard therapies for lichen planus include topical, intralesional and systemic steroids, retinoids, psoralen plus ultraviolet A and, for severe or treatment resistant cases, cyclosporine.<sup>10</sup> Acitretin, topical and systemic steroids, psoralen plus ultraviolet A and psoralen plus ultraviolet A-Bath therapies, thalidomide, topical cyclosporine, and surgical treatment were reported for the treatment of palmoplantar lichen planus.<sup>5,11-13</sup> Acitretin is the only drug that has been shown to be supported by the evidence found through double-blind studies, including those on systemic steroids.<sup>10,14</sup> Retinoids have anti-inflammatory, anti-proliferative and immune modulatory effects.<sup>1,5</sup>

In our case, acitretin of a lower dose was used in the patient for a short period with great success. It is interesting to have found hyperpigmented, red-brown macules in flexural folds of our patient in his eighth month control. This finding is in line with the studies in the literature, stating that Lichen planus pigmentosus (LPP), an uncommon variant of lichen planus, is characterized by hyperpigmented, dark brown macules in sun-exposed areas and flexural folds.<sup>1</sup> The lesions seen were evaluated as lichen planus pigmentosus and topical steroids were used in the treatment.

## CONCLUSION

As a result of the study, the following points need to be taken into account. First, palmoplantar lichen planus must be considered within the differential diagnosis of the palmoplantar keratodermas. Second, the disease –Lichen planus can manifest itself as an isolated involvement only in the palmoplantar region. Third, acitretin must be kept in mind as a choice for treatment. Finally, follow-up of lichen planus can, in the long term, come out in some other morphology in another site, lichen planus pigmentosus as in our case.

## REFERENCES

1. Daoud MS, Pittelkow MR. Lichen planus. In: Freedberg IM, Eisen AZ, Wolff K, Austen KF, Goldsmith LA, Katz S eds. Fitzpatrick's Dermatology in General Medicine. 6th ed. Newyork: McGraw-Hill; 2003.p. 463-77.
2. Gündüz K, Inanir I, Türkdogan P, Sacar H. Palmoplantar lichen planus presenting with vesicle-like papules. *J Dermatol* 2003;30:337-40.
3. Sánchez-Pérez J, Rios Buceta L, Fraga J, García-Díez A. Lichen planus with lesions on the palms and/or soles: prevalence and clinicopathological study of 36 patients. *Br J Dermatol* 2000;142:310-4.
4. Bhattacharya M, Kaur I, Kumar B. Lichen planus: a clinical and epidemiological study. *J Dermatol* 2000;27:576-82.
5. De Jong EM, Van De Kerkhof PC. Coexistence of palmoplantar lichen planus and lupus erythematosus with response to treatment using acitretin. *Br J Dermatol* 1996;134:538-41.
6. Rotunda AM, Craft N, Haley JC. Hyperkeratotic plaques on the palms and soles. Palmoplantar lichen planus, hyperkeratotic variant. *Arch Dermatol*. 2004 Oct;140(10):1275-80.
7. Feuerman EJ, Ingber A, David M, Weissman-Katzenelson V. Lichen ruber planus beginning as a dyshidrosiform eruption. *Cutis* 1982;30:401-4.
8. French LE, Masgrau E, Chavaz P, Saurat JH. Eccrine syringofibroadenoma in a patient with erosive palmoplantar lichen planus. *Dermatology* 1997;195:399-401.
9. Micalizzi C, Tagliapietra G, Farris A. Ulcerative lichen planus of the sole with rheumatoid arthritis. *Int J Dermatol* 1998;37:862-3.
10. Kano Y, Shiohara T. Lichen planus and lichenoid dermatoses. In: Bologna JL, Jorizzo JL, Rapini RP, et al eds. *Dermatology*. 1st ed. Spain : Mosby ; 2004.p.175-98.
11. Paçj M, Silva R. Treatment of plantar erosive lichen planus with topical cyclosporin. *J Eur Acad Dermatol Venereol* 2001;15:79-80.
12. Grundmann-Kollmann M, Behrens S, Peter RU, Kerscher M. Treatment of severe recalcitrant dermatoses of the palms and soles with PUVA-bath versus PUVA-cream therapy. *Photodermatol Photoimmunol Photomed* 1999;15:87-9.
13. Moss AL, Harman RR. Surgical treatment of painful lichen planus of the hand and foot. *Br J Plast Surg* 1986;39:402-7.
14. Laurberg G, Geiger JM, Hjorth N, Holm P, Hou-Jensen K, Jacobsen KU, Nielsen AO, et al. Treatment of lichen planus with acitretin. A double-blind, placebo-controlled study in 65 patients. *J Am Acad Dermatol* 1991;24:434-7.