

Acute Total LMCA Occlusion and Successful TAP Stenting: Which Strategy Should We Follow in STEMI?

Akut Total LMCA Tıkanıklığı ve Başarılı TAP Stentleme: STEMI’da Hangi Stratejiyi İzlemeliyiz?

Ömer Faruk KESKİN^a, Mustafa DEMİR^b, Atila İYİSOY^a

^aGülhane Training and Research Hospital, Clinic of Cardiology, Ankara, TURKEY

^bDenizli Private Tekden Hospital, Clinic of Cardiology, Denizli, TURKEY

ABSTRACT The incidence of acute total left main coronary artery (LMCA) occlusion cannot be fully determined precisely, given that most of patients die unfortunately before hospital arrival. This patient group is rarely encountered but mortality is very high due to endangered a large area of myocardium and increases the risk of cardiogenic shock and lethal arrhythmia quickly. We report a case of a 40-year-old woman presented with acute anterolateral myocardial infarction and was managed successful with percutaneous intervention with TAP (T-stenting And small Protrusion) technique stenting. According to current guidelines in LMCA disease, coronary artery bypass graft (CABG) is preferred, but percutaneous coronary intervention (PCI) is life-saving treatment strategy in emergencies for hemodynamic instability patient. On the other hand, there is no specific recommendations given concerning treatment for STEMI due to LMCA and optimal revascularization strategy is still uncertain because of absence of a randomized trial. Alternative treatments are; primary angioplasty-stenting, emergency CABG, primary angioplasty followed by emergency CABG.

ÖZET Akut total sol ana koroner arter (LMCA) oklüzyon insidansı hastaların çoğunun hastaneye gelmeden önce ölmesi sebebiyle tam olarak belirlenememektedir. Bu hasta grubuna nadiren rastlanır, ancak geniş bir miyokard alanının tehlikeye girmesi kardiyojenik şok ve ölümcül aritmi riskini artırarak mortaliteyi yükseltir. Biz 40 yaşında, akut anterolateral miyokard infarktüsü ile acil servise başvuran ve TAP tekniği ile başarılı perkütan koroner girişim (PKG) yapılan olguyu sunuyoruz. Mevcut kılavuzlara göre ciddi LMCA hastalığında koroner arter bypass greft (KABG) öncelikli olarak tercih edilen tedavi yöntemidir, ancak hemodinamik açıdan instabil olan acil vakalarda PKG hayat kurtarıcı tedavidir. Öte yandan, LMCA total tıkanıklığından gelişen STEMI tedavisi için spesifik bir tavsiye verilmemiştir. Ayrıca bu konuda randomize bir çalışma olmadığı için optimal revaskülarizasyon stratejisi hala belirsizdir. Primer anjiyoplasti ve stentleme, acil KABG, primer anjiyoplasti ardından acil KABG alternatif tedavi yöntemleridir.

Keywords: Percutaneous coronary intervention; coronary occlusion; transluminal coronary balloon angioplasty

Anahtar Kelimeler: Perkütan koroner girişim; koroner tıkanıklık; transluminal koroner balon anjiyoplasti

The incidence of acute total left main coronary artery (LMCA) occlusion cannot be determined exactly because most of patients die before hospital arrival.¹ This patient group is rarely encountered but mortality is very high due to being complicated by cardiogenic shock and lethal arrhythmia quickly.² We

report a case of a 40-year-old woman who was presented with acute anterolateral myocardial infarction and managed successfully with percutaneous intervention with TAP (T-stenting And small Protrusion) technique stenting.

Correspondence: Ömer Faruk KESKİN
Gülhane Training and Research Hospital, Clinic of Cardiology, Ankara, TURKEY/TÜRKİYE
E-mail: farukomerkeskin@gmail.com



Peer review under responsibility of Türkiye Klinikleri Cardiovascular Sciences.

Received: 07 Jan 2020

Received in revised form: 04 Mar 2020

Accepted: 08 Mar 2020

Available online: 10 Mar 2020

2146-9032 / Copyright © 2020 by Türkiye Klinikleri. This is an open access article under the CC BY-NC-ND license (<http://creativecommons.org/licenses/by-nc-nd/4.0/>).

CASE REPORT

A 40-year-old woman presented to emergency department with chest pain, dyspnoea and cold sweating, state of consciousness was observed lethargic. ECG showed ST segment elevation in anterolateral (V2-V6-DI-aVL) leads (Figure 1A). Transthoracic echocardiogram showed very low ejection fraction 25% (Simpson) accompanied by left ventricular apical and anterolateral wall hypokinesia. Blood pressure was 60/30 mmHg, pulse 120 /min, O2 saturation 68% without any support. The patient was intubated; started fluids and inotropic agents immediately, first antithrombotic and anticoagulant treatments were given at emergency department. The patient was immediately taken to the catheter lab and coronary angiography was performed via right femoral artery. The left coronary ostium was selectively engaged with a 7 Fr JL4 guiding catheter and cine showed us that left main coronary artery (LMCA) was totally occluded proximally (Figure 1B; Video 1). Immediately 0.014 floppy guidewires were advanced both left anterior descending (LAD) and circumflex (CFX)

artery. From LAD to LMCA multiple percutaneous transluminal coronary angioplasty (PTCA) was performed with 2.0x20 mm semi-compliant (SC) balloon and TIMI (Thrombolysis In Myocardial Infarction) 2 flow was achieved (Figure 1C, 1D). Then PTCA was performed in CFX proximal with 2.0x20 mm SC balloon but no TIMI flow was provided. Kissing balloon was performed with 2.0x20 mm 1.5x20 mm SC balloons from LMCA to CFX and LAD (Figure 1E). After kissing balloon cine showed us that LAD flow was TIMI 2 but still CFX flow was TIMI 0 (Figure 1F). We had to implant a 3.5x18 mm Zotarolimus-Eluting Stent (DES) from LMCA to LAD due to the cardiogenic shock and ventricular fibrillation (Figure 2A). After stent implantation LAD flow was TIMI 3 (Figure 2B). Then we rewired CFX through stent struts with hi torque pilot 150 wire because of we could not rewire with 0.014 inch floppy guidewire. First, we performed PTCA with 2.5x20 mm SC balloon and we adjusted stents' proximal location with minimal protrusion to LMCA then we implanted a 2.75x22 mm mm Zotarolimus-Eluting Stent (DES) with TAP technique at CFX prox-

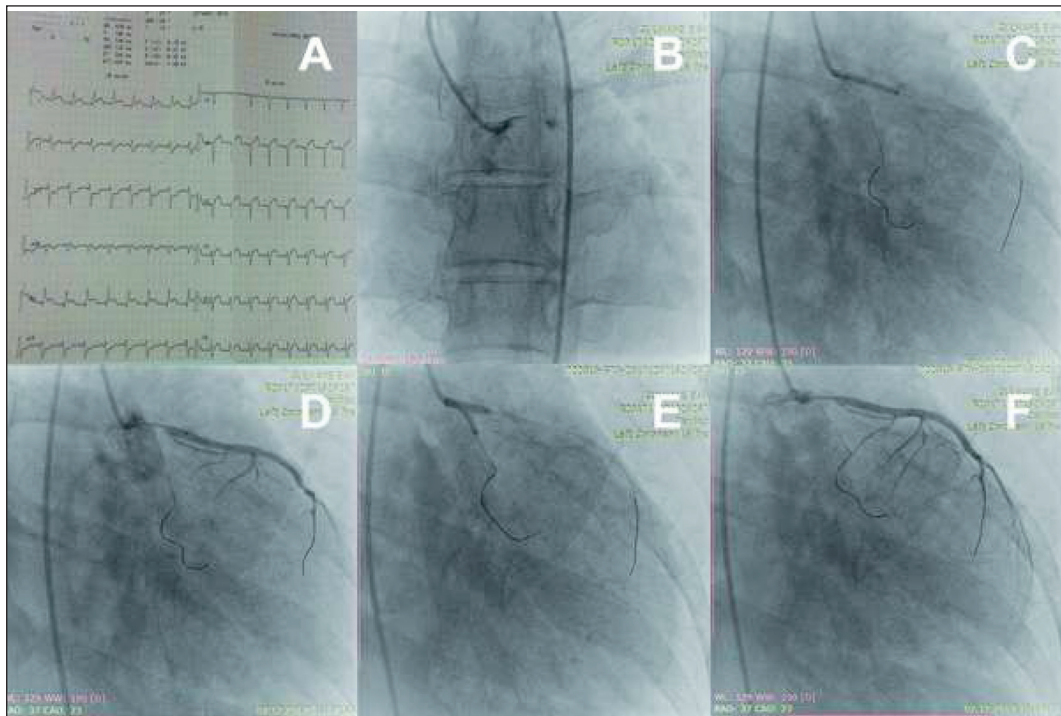


FIGURE 1: A) ECG showed ST segment elevation in anterolateral (V2-V6-DI-aVL) leads. B) Cine showed left main coronary artery (LMCA) was totally occluded proximally. C) PTCA was performed with 2.0x20 mm Invader balloon from LAD to LMCA. D) TIMI 2 flow was achieved in LAD. E) Kissing balloon was performed with 2.0x20 mm 1.5x20 mm balloons. F) After kissing balloon, LAD flow was TIMI 2 but CFX flow was TIMI 0.

imal (Figure 2C, 2D). After stenting, kissing balloon was performed with 3.0x15 and 2.5x12 NC balloons and the last cine was excellent (Figure 2E, 2F; Video 2). We could not perform proximal optimisation technique (POT) to main vessel's proximal because LMCA was very short. But we oversized to ostium with main vessel's balloon. We inserted the intra-aortic balloon pump to the patient and the patient was monitored in coronary care unit. One day later, the patient was extubated and hemodynamic state was stable. In her first month follow-up; control angiography was very good (Figure 3A, 3B; Video 3). Informed consent was taken from the patient.

DISCUSSION

STEMI clinical cases due to the acute LMCA occlusion are very rare but unfortunately it often ends fatally.³ There is limited data regarding this group in literature for percutaneous intervention (PCI) and most of patients have been case series.^{1,3,4} Mortality rate of this clinical presentation is very high despite advancement reperfusion treatments.¹⁻³ This clinical

entity is known as left main shock syndrome.⁵ According to current guidelines in LMCA disease coronary artery bypass graft is (CABG) is preferred, PCI is performed usually feasible anatomy and low SNYTAX score.^{6,7} However no specific recommendations are given concerning treatment for STEMI due to LMCA occlusion and optimal revascularization strategy is still uncertain due to absence of a randomized trial. Alternative treatments are; primary angioplasty-stenting, emergency CABG, primary angioplasty plus then emergency CABG. PCI has advantage rapid reperfusion with acceptable short and long term outcomes.² Primary angioplasty can be used as a bridge to CABG. Grundeken et al. reported a staged hybrid approach of initial revascularization that hemodynamic stabilization of patient in cath. lab with angioplasty and after providing TIMI 2-3 flow, performed same day CABG.⁸ But in the drug eluting stent era with lower stent restenosis and target vessel revascularization, primary stenting especially in those whom cardiogenic shock, TIMI 0 flow and high surgical risk is very important.²

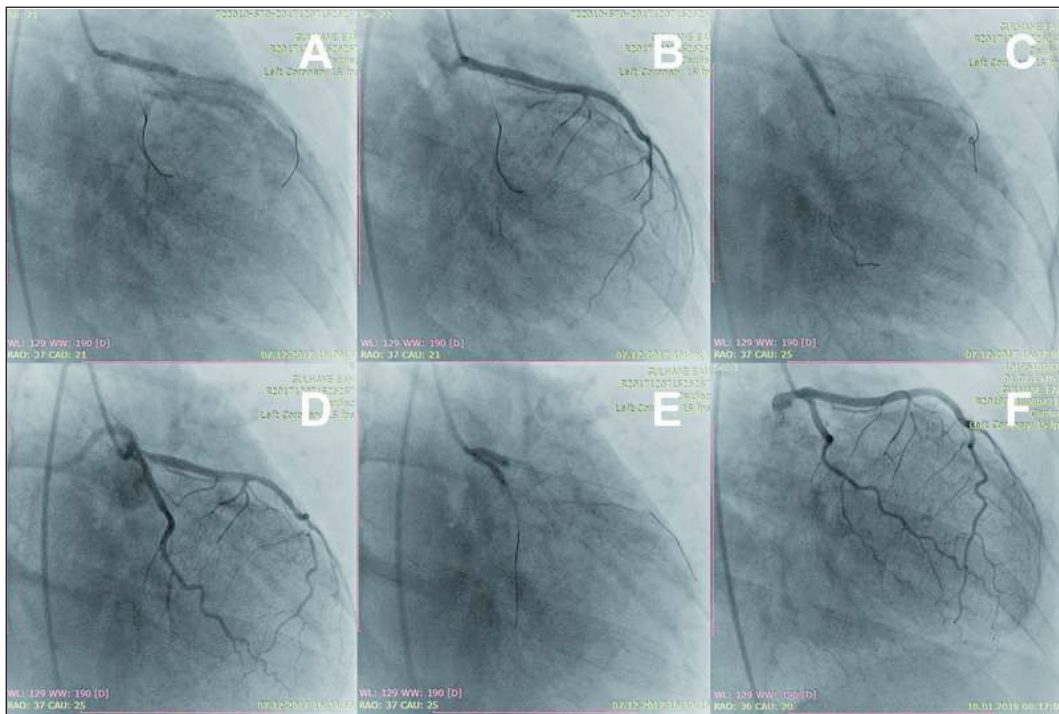


FIGURE 2: **A)** We implanted a 3.5x18 mm Resolute Integrity (Medtronic) drug eluting stent (DES) from LMCA to LAD. **B)** After stent implantation LAD flow was TIMI 3. **C)** We performed PTCA with 2.5x20 mm balloon at CFX proximal. **D)** We implanted a 2.75x22 mm Resolute Integrity DES with TAP technique at CFX proximal. **E)** Kissing balloon was performed with 3.0x15 and 2.5x12 NC balloons. **F)** Last cine was excellent.

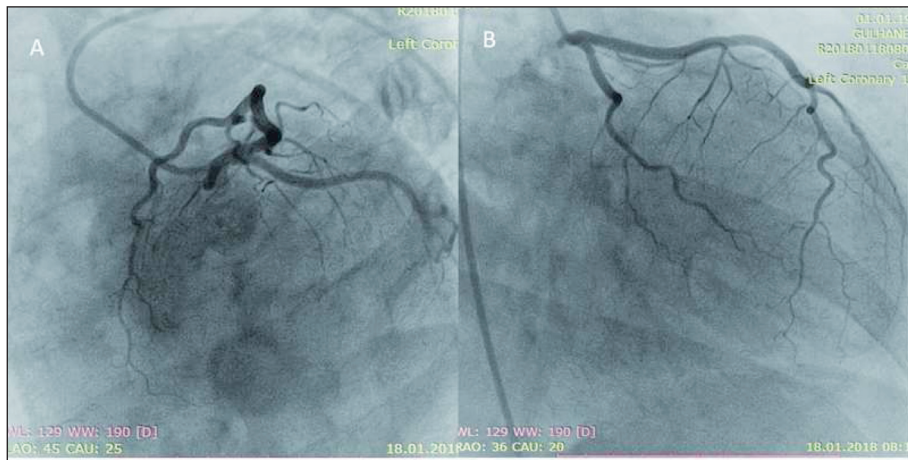


FIGURE 3: A) In first month follow-up control angiography was very good on spider view. **B)** Control angiography was very good on RAO caudal view.

Delays to reperfusion with CABG which may take an hour or longer to establish cardiopulmonary bypass can be catastrophic in this situation. Additionally surgeons commonly use the saphenous vein graft rather than LIMA to anastomose LAD in emergency patients. So in long term outcome, primary stenting with DES may be more superior than CABG. Our patient was in cardiogenic shock and had TIMI 0 flow so after primer angioplasty we implanted bifurcation stents quickly with TAP technique. We did not try thrombus aspiration in our case because routine thrombus aspiration is no longer recommended in the last guidelines, since it increases the risk of long-term stroke.^{6,7} In the “2018 ESC/EACTS Guidelines on myocardial revascularization”, double kissing crush technique is now recommended for true left main coronary bifurcation lesions.⁶ However, our patient was in the cardiogenic shock clinic and CFX flow could not be achieved despite successful balloon angioplasty, these reasons caused us to choose the strategy to relieve the patient by providing the LAD flow first. Pappalardo et al. reported most of bifurcation lesions treated with provisional techniques, only %8 of cases treated with bifurcation stenting and T-stenting was performed only 1 patient.² Additionally Saed et al. reported intraaortic balloon pump is necessary to provide hemodynamical stabilization and we inserted to our patient IABP at the beginning of procedure.⁹ Without randomize trial, to say that recommendation PCI or CABG first is difficult but we believe that in the DES era physicians should be perform PCI as a first line

treatment especially in hemodynamically unstable patients. The optimal revascularization technique (PCI or Surgery) for patients with acute total occlusion of the LMCA is still unknown. First of all, rapid revascularization is very important and PCI is more rapid and practical than emergency surgery. It is our opinion that rapid reperfusion advantage and considering long term DES outcomes of PCI rather than saphenous vein grafts, catastrophic effect of delay surgery; PCI should be performed as first line therapy especially in experienced centers.

Source of Finance

During this study, no financial or spiritual support was received neither from any pharmaceutical company that has a direct connection with the research subject, nor from a company that provides or produces medical instruments and materials which may negatively affect the evaluation process of this study.

Conflict of Interest

No conflicts of interest between the authors and / or family members of the scientific and medical committee members or members of the potential conflicts of interest, counseling, expertise, working conditions, share holding and similar situations in any firm.

Authorship Contributions

Idea/Concept: Ömer Faruk Keskin; **Design:** Ömer Faruk Keskin; **Control/Supervision:** Mustafa Demir, Atila İyisoy; **Data Collection and/or Processing:** Ömer Faruk Keskin; **Analysis and/or Interpretation:** Mustafa Demir, Atila İyisoy; **Literature Review:** Ömer Faruk Keskin; **Writing the Article:** Ömer Faruk Keskin; **Critical Review:** Mustafa Demir, Atila İyisoy.

REFERENCES

1. Çetin M, Kocaman SA, Bostan M, Erdogan T, Satiroglu Ö. Primary percutaneous coronary intervention for the treatment of a patient with cardiogenic shock due to acute total occlusion of unprotected left main coronary artery without supportive collateral flow. *Future Cardiol.* 2011;7(6):749-55. [[Crossref](#)] [[PubMed](#)]
2. Pappalardo A, Mamas MA, Imola F, Ramazotti V, Manzoli A, Prati F, et al. Percutaneous coronary intervention of unprotected left main coronary artery disease as culprit lesion in patients with acute myocardial infarction. *JACC Cardiovasc Interv.* 2011;4(6):618-26. [[Crossref](#)] [[PubMed](#)]
3. Lee MS, Dahodwala MQ. Percutaneous coronary intervention for acute myocardial infarction due to unprotected left main coronary artery occlusion: status update 2014. *Catheter Cardiovasc Interv.* 2015;85(3):416-20. [[Crossref](#)] [[PubMed](#)]
4. Aygül N, Aygül MU, Ozdemir K, Altunkeser BB. Emergency revascularization procedures in patients with acute ST-elevation myocardial infarction due to acute total occlusion of unprotected left main coronary artery: a report of five cases. *Türk Kardiyol Dern Ars.* 2010;38(2):131-4. [[PubMed](#)]
5. Yamane M, Inoue S, Yamane A, Kinebuchi O, Yokozuka H. Primary stenting for left-main shock syndrome. *EuroIntervention.* 2005;1(2):198-203. [[PubMed](#)]
6. Neumann FJ, Sousa-Uva M, Ahlsson A, Alfonso F, Banning AP, Benedetto U, et al; ESC Scientific Document Group. 2018 ESC/EACTS Guidelines on myocardial revascularization. *Eur Heart J.* 2019;40(2):87-165. [[Crossref](#)] [[PubMed](#)]
7. Levine GN, Bates ER, Blankenship JC, Bailey SR, Bittl JA, Cercek B, et al. 2015 ACC/AHA/SCAI focused update on primary percutaneous coronary intervention for patients with ST-elevation myocardial infarction: an update of the 2011 ACCF/AHA/SCAI Guideline for percutaneous coronary intervention and the 2013 ACCF/AHA Guideline for the management of ST-elevation myocardial infarction. *J Am Coll Cardiol.* 2016;67(10):1235-50. [[PubMed](#)]
8. Grundeken MJ, Vis MM, Beijk MAM, Kikkert WJ, Damman P, Kloek JJ, et al. Clinical outcomes after percutaneous or surgical revascularisation of unprotected left main coronary artery-related acute myocardial infarction: a single-centre experience. *Heart.* 2013;99(10):690-9. [[Crossref](#)] [[PubMed](#)]
9. Saeed G. Survival after acute and total occlusion of the left main coronary artery. *Asian Cardiovasc Thorac Ann.* 2010;18(6):599. [[Crossref](#)] [[PubMed](#)]