

## Cylindrical Battery Ingestion: Original Image

## Silendirik Pil Yutulması

Elif ŞENOCAK TAŞÇI,<sup>a</sup>  
Esra ACAR,<sup>a</sup>  
Fatih ERMiŞ<sup>b</sup>

Departments of  
<sup>a</sup>Internal Medicine,  
<sup>b</sup>Gastroenterology,  
Düzce University Faculty of Medicine,  
Düzce

Geliş Tarihi/Received: 03.12.2015  
Kabul Tarihi/Accepted: 18.05.2016

Yazışma Adresi/Correspondence:  
Elif ŞENOCAK TAŞÇI  
Düzce University Faculty of Medicine,  
Department of Internal Medicine, Düzce,  
TÜRKİYE/TURKEY  
esenocak@gmail.com

**Key Words:** Endoscopy; emergencies

**Anahtar Kelimeler:** Endoskopi; aciller

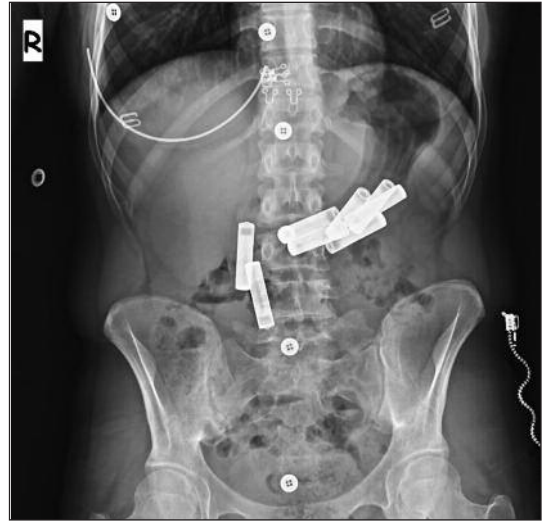
**Türkiye Klinikleri J  
Gastroenterohepatol  
2015;22(2):42-3**

doi: 10.5336/gastro.2015-48856

Copyright © 2015 by Türkiye Klinikleri

A 20-year-old woman was brought in to our emergency department after ingesting cylindrical battery as a suicide attempt. She had severe epigastric pain. Laboratory findings showed no abnormalities. Her medical history revealed asthma and operation secondary to key ingestion. The abdominal X-ray showed 8 cylindrical batteries; located in the stomach (6) and duodenum (2) (Figure 1). When consulted with psychiatry she was diagnosed bipolar. Patient was admitted to follow-up the discharge of batteries. Next day, abdominal X-ray showed the passage of 3 batteries to the colon (Figure 2). Since she had severe continuous epigastric pain, shortness of breath and tenderness in physical examination, endoscopy was planned. Three of the batteries entrapped in the stomach were removed (Figure 3). As she had asthma, in order to prevent allergic reaction colonoscopy was intended but could not be performed due to the inadequate bowel preparation. Remaining batteries were observed until passage by stool was confirmed.

Battery ingestion is one of the frequently seen suicide attempts in adults. Button batteries are mostly ingested while cylindrical battery ingestion is rare. Intact cylindrical batteries pose low threat of erosive and toxic damage but may become entrapped in the stomach due to their size



**FIGURE 1:** 6 cylindrical batteries located in the stomach and 2 cylindrical batteries located in the duodenum.

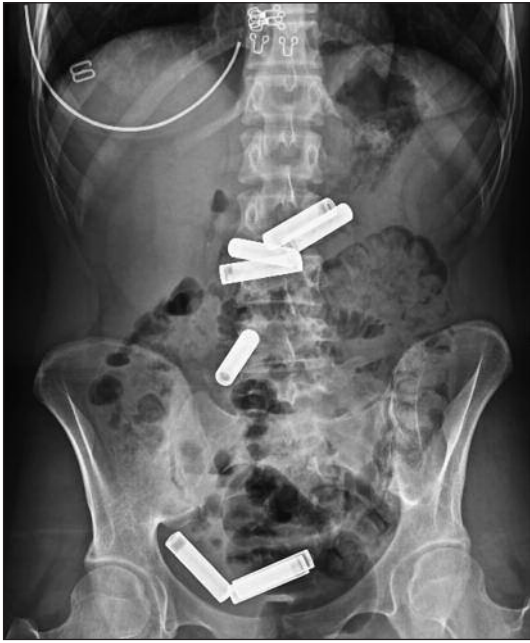

FIGURE 2: Passage of 3 batteries to colon.

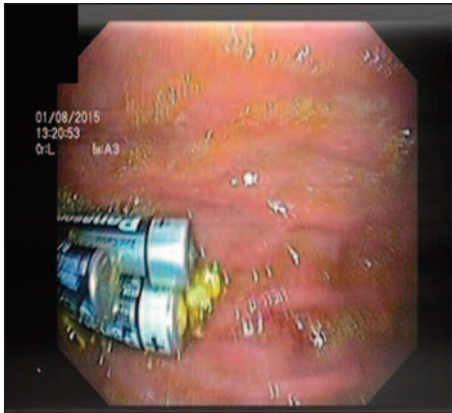


FIGURE 3: Endoscopic image of 3 batteries in the stomach.

(>2.5 cm). Patients need immediate localization of the batteries with plain radiography from mouth to the anus and the ones in the esophagus should urgently be removed by endoscopy as they may cause burns due to leakage.<sup>1,2</sup> The ones in the stomach may be removed at initial evaluation or be re-evaluated. Batteries that have exited the stomach may be observed with follow-up radiographs until passage by stool is confirmed. Endoscopic or surgical removal is mandatory if;<sup>3</sup>

- symptoms of perforation/peritonitis develop,
- the battery was damaged before/during ingestion or remains in the stomach
- 48-hour post-ingestion,
- no movement is observed within a 48-hour period,
- allergic reaction (shortness of breath).

In addition, the case illustrates the importance of psychiatric treatment in patients with history of recurrent foreign body ingestion. Our patient, with history of key ingestion, repeated her action for secondary gain, which is not recognized by the patient. She was admitted to the hospital with battery ingestion, as she did not receive the appropriate psychiatric treatment after her first suicide attempt. Therefore, after the first intervention, physicians should provide the necessary treatment to patients in order to prevent similar cases.

## REFERENCES

1. Kramer RE, Lerner DG, Lin T, Manfredi M, Shah M, Stephen T, et al; North American Society for Pediatric Gastroenterology, Hepatology, and Nutrition Endoscopy Committee. Management of ingested foreign bodies in children: a clinical report of the NASPGHAN Endoscopy Committee. *J Pediatr Gastroenterol Nutr* 2015;60(4):562-74.
2. Untersweg U, Mayr J, Schmidt B. Oesophageal burn caused by sucking a 1.5 volt battery. *Acta Paediatr* 1996;85(11):1382-3.
3. Hindley N, Gordon H, Newirth C, Mohan D. The management of cylindrical battery ingestion in psychiatric settings. *Psychiatric Bulletin* 1999;23:224-6.