

Compartment Syndrome Due to Extravasation of Iodixanol Contrast Medium: Case Report

İyodiksanol Kontrast Maddesinin Ekstravazasyonuna Bağlı Kompartman Sendromu

Savaş GÜNER, MD, Assis.Prof.,^a
M. Fethi CEYLAN, MD, Assis.Prof.,^a
Serhat AVCU, MD, Assis.Prof.,^b
S. İlkey GÜNER, PhD, Assis.Prof.,^c
Ali DOĞAN, MD, Assoc.Prof.^a

Departments of
^aTrauma and Orthopedic Surgery,
^bTrauma Radiology,
Yüzüncü Yıl University,
Faculty of Medicine,
^cYüzüncü Yıl University,
Faculty of Nursing, Van

Geliş Tarihi/Received: 26.01.2010
Kabul Tarihi/Accepted: 02.11.2010

Yazışma Adresi/Correspondence:
Savaş GÜNER, MD, Assis.Prof.
Yüzüncü Yıl University,
Faculty of Medicine,
Department of Trauma and
Orthopedic Surgery, Van,
TÜRKİYE/TURKEY
gunersavas@hotmail.com

ABSTRACT Compartment syndrome due to extravasation of contrast medium is quite rare. The content of the contrast medium, the osmolarity, the ionic/non-ionic structure and the amount of extravasated medium are important factors in the pathogenesis of extravasation injury. Many extravasations are of small volumes causing minimal swelling and erythema. Extravasations of large volumes are important in the development of compartment syndrome due to the non-ionic contrast medium. Early diagnosis is very important in the contrast medium extravasations and conservative treatment is effective in most of the patients. If compartment syndrome develops after extravasation, emergency fasciotomy should be performed immediately. To the best of our knowledge, compartment syndrome due to extravasation of a non-ionic contrast medium, iodixanol, has not previously been reported in the English literature. In this article, a case of extravasation and compartment syndrome due to the administration of iodixanol for thoracic tomography and its treatment was first reported.

Key Words: Extravasation of diagnostic and therapeutic materials; compartment syndromes; hand; iodixanol

ÖZET Kontrast madde ekstravazasyonu nedeniyle kompartman sendromu nadiren gelişen bir durumdur. Kontrast madde içeriği, ekstravaze olan maddenin ozmolaritesi, iyonik/non-iyonik yapısı ve miktarı, ekstravazasyon yaralanmasının patogenezinde rol oynayan önemli faktörlerdir. Birçok ekstravazasyon küçük hacimdedir ve minimal şişliğe ve eriteme neden olurlar. Büyük hacimdeki ekstravazasyon, non-iyonik kontrast madde nedeniyle kompartman sendromuna neden olması açısından önemlidir. Kontrast madde ekstravazasyonlarında erken tanı çok önemlidir ve konservatif tedavi hastaların çoğunda etkilidir. Ekstravazasyon sonrasında kompartman sendromu gelişmesi durumunda, hemen acil fasyotomi yapılmalıdır. Bildiğimiz kadarıyla, bir non-iyonik kontrast madde olan iyodiksanolün ekstravazasyonu nedeniyle gelişen kompartman sendromu, İngilizce literatürde daha önce bildirilmemiştir. Bu makalede, toraks tomografisi için iyodiksanol uygulamasına bağlı ekstravazasyon ve kompartman sendromu vakası ve tedavisi ilk kez bildirilmiştir.

Anahtar Kelimeler: Tanısal ve terapötik materyallerin ekstravazasyonu; kompartman sendromları; el; iyodiksanol

Türkiye Klinikleri J Med Sci 2012;32(1):248-51

Extravasation of contrast medium is a complication of contrast-mediated imaging techniques.¹ Compartment syndrome (CS) due to extravasation of the contrast medium is a very rare condition.^{2,3} The treatment of CS accounts for an urgent operative intervention for fasciotomy.⁴ Here, we report a patient who developed CS after intravenous contrast medium (iodixanol) administration for computed tomography (CT). Iodixanol is a lower osmolarity and non-ionic intravenous contrast medium.

There is no report of compartment syndrome due to iodixanol in the literature.

CASE REPORT

A 48-year-old female was admitted to our internal medicine outpatient clinic with refractory cough and weight loss. Suspecting a lung tumour in her clinical and X-ray evaluations, a thoracic CT was performed. Before the thoracic CT, approximately 90 cc of the non-ionic water-soluble iso-osmolar contrast medium, iodixanol (Visipaque, Opakim, Turkey), was injected using an automated injection system (Medrad Vistron CT injection system) on the dorsum of right hand. The patient did not complain of any symptom during the CT imaging. One hour after the injection, she presented to our outpatient clinic with swelling and severe pain on her right hand (at the injection site). Physical examination revealed intense swelling, hyperaemia and severe pain with passive dorsiflexion of her fingers on the right hand and distal parts of the forearm, hypoesthesia in the median nerve sensation area of her right hand and pulselessness and poor capillary refill. Right hand radiography revealed extravasation of contrast medium in a large area of soft tissue was observed (Figure 1). After clinical and radiological examination, she was diagnosed with CS. She underwent fasciotomy at postinjection 3

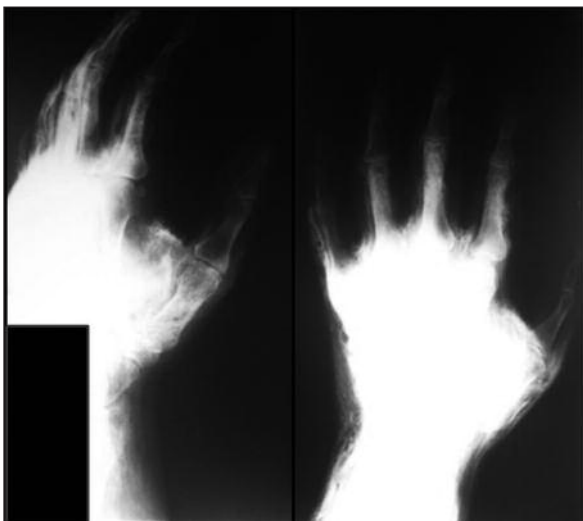


FIGURE 1: Antero-posterior and lateral radiographs of the right hand showing extravasation of contrast medium.

hours. On the dorsum of her right hand, interosseous compartments and adductor compartments were released through two longitudinal incisions. Then, thenar and hypothenar compartments on the volar region of the right hand and the carpal tunnel were released utilizing zig zag incisions descending from the volar part of the hand to the distal parts of the forearm. During the operation, soft tissue seemed viable macroscopically. Following the surgery, the pain and hypoesthesia improved. Upon a decrease in the oedema of her hand on postoperative day 3, the dorsal incisions were sutured primarily. However, volar incisions were sutured gradually utilizing the shoelace technique since they did not approach each other primarily end-to-end (Figure 2).⁵ The sutures were removed on postoperative day 15. On her follow up, no motor or sensation loss was detected.

DISCUSSION

CS is a clinical entity that develops due to a defect in the capillary blood perfusion that is necessary for tissue viability after an increase in pressure of closed fascial spaces (muscle compartment) that is characterized by functional loss in the extremity.^{6,7} Defect in blood perfusion results in ischemia of muscles and nerves. As a result of compression and/or ischemia, sensation and motor loss may accompany the clinical picture.⁸ There are many reasons that can lead to CS in the hand. These include bone fractures, crushing of muscles or soft tissue, firm bandage for a prolonged period, burns, insect bites, heavy exercise, infections and intravenous drug use.^{1,7,8} The classical physical examination findings of CS include severe pain, which is continuous and which significantly increases especially with passive tightness of muscle and paraesthesia. Some signs of circulation defects such as swelling, colour changes and pulselessness may also be present.¹ Sensation loss and paralysis are the late signs of CS that are indicators of irreversible tissue deficiencies.⁴

Although extravasation of ionized contrast medium is a common condition, CS is quite rare.⁴ In a study of Wang et al. on 69657 patients, ex-

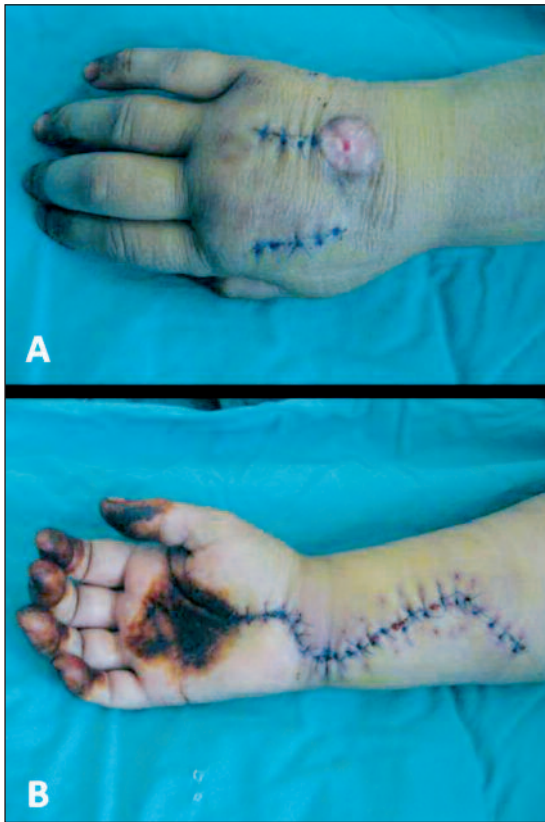


FIGURE 2: Dorsal (A) and volar (B) views of the patient's right hand at post-operative day 3.
(See for colored form <http://tipbilimleri.turkiyeklinikleri.com/>)

travasation was determined in 475 (0.7%) patients and compartment syndrome (CS) was reported only in one patient.² In the English literature, CS due to non-ionic intravenous contrast medium extravasation has been reported in only 5 cases. In these reports, iohexol or iopromide were used as contrast medium.^{1,2,4,7,9} However, there is no report of compartment syndrome due to iodixanol (Visipaque), which was used in our patient, in the literature. Nevertheless, in a study regarding the extravasation of non-ionic contrast medium, iohexol, iopromide and iodixanol were reported to cause moderate or severe tissue defects at rates of

60%, 30% and 10%, respectively. In the same study, CS was reported in only one patient due to the extravasation of iohexol.²

Not only the contents, but also the osmolarity, the ionic-non-ionic structure, and the amount of extravasated medium are important factors in the pathogenesis of extravasation deficiencies.^{1,7,9} Non-ionic contrast media with lower osmolarity cause less tissue defects.⁹ Generally, lower amounts of extravasated contrast medium causes minimal swelling, pain and localized erythema. These findings greatly regress within 24 hours.³ Large tissue necrosis, ulcerations and CS are rare and generally develop in extravasation of high amounts of contrast medium.¹⁻³

Early diagnosis is very important in contrast medium extravasations and conservative treatment is effective in most patients. Elevation of the involved extremity is generally useful in decreasing the oedema. Cold application with ice boxes is also very effective in limiting the inflammation.^{1,2} Local subcutaneous injection of hyaluronidase enzyme is used in extravasations of contrast medium with low or high osmolarity. This enzyme causes absorption of the extravasated material by lymphatic and vascular systems.^{1,3} Surgery is recommended in cases with skin blistering, decreased tissue perfusion, increased and persisted pain and paresthesia.³ Surgical decompression to relax the neurovascular structures is more effective when applied within the first 6 hours.^{1,3} In surgery, carpal tunnel should also be released in addition to fasciotomy.⁴

In conclusion, the risk of CS should be considered in extravasations with large volumes, although rare. It should not be forgotten that CS might also develop due to iodixanol, which has a low incidence of moderate or severe tissue damage.

REFERENCES

1. Selek H, Ozer H, Aygencel G, Turanlı S. Compartment syndrome in the hand due to extravasation of contrast material. *Arch Orthop Trauma Surg* 2007;127(6):425-7.
2. Wang CL, Cohan RH, Ellis JH, Adusumilli S, Dunnick NR. Frequency, management, and outcome of extravasation of nonionic iodinated contrast medium in 69,657 intravenous injections. *Radiology* 2007;243(1):80-7.
3. Bellin MF, Jakobsen JA, Tomassin I, Thomsen HS, Morcos SK, Thomsen HS, et al.; Contrast Media Safety Committee Of The European Society Of Urogenital Radiology. Contrast medium extravasation injury: guidelines for prevention and management. *Eur Radiol* 2002;12(11):2807-12.
4. Grand A, Yeager B, Wollstein R. Compartment syndrome presenting as ischemia following extravasation of contrast material. *Can J Plast Surg* 2008;16(3):173-4.
5. Zorrilla P, Marín A, Gómez LA, Salido JA. Shoelace technique for gradual closure of fasciotomy wounds. *J Trauma* 2005;59(6):1515-7.
6. Özkan Y, Öztürk A, Aykut S. [Compartment syndrome]. *Türkiye Klinikleri J Surg Med Sci* 2006;2(17):64-71.
7. Stein DA, Lee S, Raskin KB. Compartment syndrome of the hand caused by computed tomography contrast infiltration. *Orthopedics* 2003;26(3):333-4.
8. Emre U, Ozdolap F, Gul F, Keser F. [Ulnar and radial nerve injury due to acute compartment syndrome]. *Turk J Phys Med Rehab* 2007;53(4):160-3.
9. Benson LS, Sathy MJ, Port RB. Forearm compartment syndrome due to automated injection of computed tomography contrast material. *J Orthop Trauma* 1996;10(6):433-6.