






# Glanular Approximation Procedure in Megameatus Intact Prepuce: A Case Series

## Megameatus İntakt Prepisyumda Glanuler Yaklaştırma Prosedürü: Olgu Serisi

 Volkan Sarper ERİKCİ<sup>a</sup>,  
 Ali SAYAN<sup>b</sup>,  
 Mustafa Onur ÖZTAN<sup>c</sup>,  
 Tunç ÖZDEMİR<sup>a</sup>,  
 Gökhan KÖYLÜOĞLU<sup>c</sup>

<sup>a</sup>Department of Pediatric Surgery,  
University of Health Sciences  
Tepecik Training and Research Hospital,  
<sup>b</sup>Department of Pediatric Surgery,  
Tepecik Training and Research Hospital,  
<sup>c</sup>Department of Pediatric Surgery,  
İzmir Katip Çelebi University  
Tepecik Training and Research Hospital,  
İzmir, TURKEY

Received: 11 Sep 2019

Received in revised form: 11 Nov 2019

Accepted: 03 Dec 2019

Available online: 13 Dec 2019

Correspondence:

Volkan Sarper ERİKCİ  
University of Health Sciences  
Tepecik Training and Research Hospital,  
Department of Pediatric Surgery, İzmir,  
TURKEY/TÜRKİYE  
verikci@yahoo.com

This study was presented as a poster at  
37<sup>th</sup> National Congress of Pediatric Surgery and  
23<sup>rd</sup> National Congress of Pediatric Surgery  
Nursing, STEPS 2019 (Strategies and Trends in  
European Pediatric Surgery), 15-19 October  
2019, Ankara, Turkey.

**ABSTRACT Objective:** The megameatus intact prepuce (MIP) is a rare type of hypospadias which is usually diagnosed during circumcision. In this study, it is aimed to present our experience with glanular approximation procedure (GAP) in the management of MIP. **Material and Methods:** A retrospective study of 13 patients with MIP variant of hypospadias who were repaired between September 2017 and April 2019 using GAP technique was performed. The total number of hypospadias cases during the study period was 85 and MIP cases constituted 15.3% of these patients. The surgical aims in GAP are to achieve a conical glans containing vertical slit, tip-cited meatus and a normal projectile urine flow. **Results:** The age range of the patients was between 18 months and 7 years. The locations of urethral meatus were glanular in 8 and coronal in 5. In all the cases, the neourethra was constructed using 7/0 polydioxanone (PDS)<sup>®</sup> in a subcuticular and uninterrupted fashion. Except for 5 patients with coronal meatus that an intermediate layer from nearby dartos fascia was interposed to support urethroplasty suture line, no intermediate layer was transposed between the tissue layers with two overlying suture lines. Good cosmetic result was obtained in all patients with a normal appearing conical glans penis. One patient developed urethrocutaneous fistula requiring surgical closure. **Conclusion:** The MIP is a simple form of hypospadias which sometimes may produce problems to surgeons. The GAP procedure is a simple technique with good cosmetic results producing patient satisfaction. Except for more severe MIP cases, GAP technique is useful in hypospadiac patients with MIP especially having glanular and coronal meatus.

**Keywords:** Hypospadias; megameatus intact prepuce; glanular approximation technique

**ÖZET Amaç:** Megameatus intakt pepisyum (MİP) nadir bir hipospadias çeşididir ve sıklıkla sünnet sırasında saptanır. Bu çalışmada MİP'li olgulardaki glanuler yaklaştırma tekniğine (GYT) ait tecrübemiz sunulmuştur. **Gereç ve Yöntemler:** Eylül 2017 ile Nisan 2019 tarihleri arasında MİP'li 13 olgu GYT ile tedavi edilmişlerdir. Çalışma dönemindeki toplam hipospadias olgu sayısı 85 olup bunların %15,3'ünü MİP olguları teşkil etmektedir. Sunulan teknikteki amaç koni şekilli glans, uca yerleşik üretral meatus ve normal projektilesi olan idrar akımı elde etmektir. **Bulgular:** Olguların yaş aralığı 18 ay ile 7 yıl arasında değişmektedir. Üretral meatus yerleşimi 8 olguda glanuler, 5 olguda da koronal düzeydedir. Tüm olgularda neouretra 7/0 polidioksanone (PDS)<sup>®</sup> kullanılarak subkütiküler devamlı dikiş tekniği ile oluşturulmuştur. Koronal düzeyde meatusu buluna 5 olgu dışında hiçbir olguya orijinal GYT'deki gibi doku tabakaları arasına herhangi bir ara tabaka konulmamıştır ve iki sütür hattı üst üste gelmektedir. Tüm olgularda konik şekilli glans penisin elde edildiği tatminkar bir kozmetik sonuç alınmıştır. Bir olguda üretral fistül gelişmiş ve fistül onarımı uygulanmıştır. **Sonuç:** MİP hipospadiasın basit bir şekli olup bazen cerrahlar için sorun teşkil edebilmektedir. GYT iyi kozmetik sonuçları olan ve hasta memnuniyetini sağlayan basit bir tekniktir. Ağır MİP olguları dışında özellikle glanuler ve koronal düzeyde üretral meatusu olan MİP olgularında GYT yararlıdır.

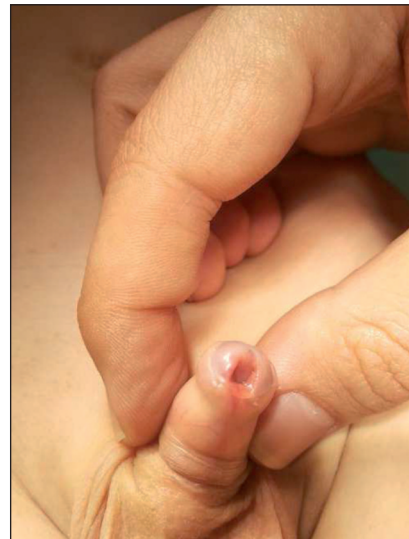**Anahtar Kelimeler:** Hipospadias; megameatus intakt pepisyum; glanuler yaklaştırma tekniği

**M**egameatus and intact prepuce (MIP) is an uncommon type of hypospadias. The locations of the urethral meatus in patients with MIP vary greatly. Patients with MIP usually have a wide coronal or subcoronal meatus with a deep glanular groove. These patients typically have a normal prepuce without penile chordee. No other urological anomalies are associated with MIP.

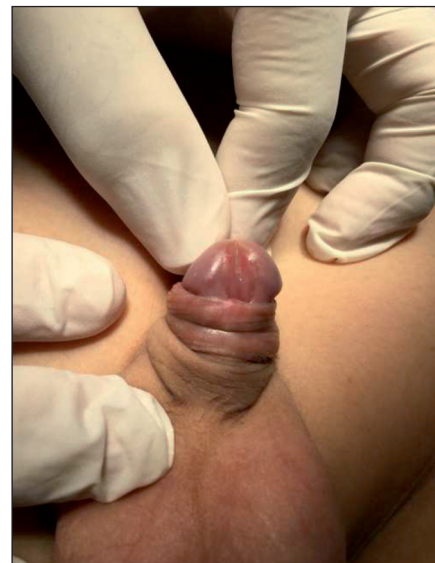The purpose of this study is to shed light on its anatomy and surgical treatment options of this entity. It is also aimed to present our experience with Glanular approximation procedure (GAP) technique in the management of the patients with MIP.

## MATERIAL AND METHODS

Thirteen patients with MIP were repaired between September 2017 and April 2019 using GAP technique. The total number of hypospadias cases during the study period was 85 and MIP cases constituted 15.3% of these patients. All patients with MIP were uncircumcised. The locations of urethral meatus were glanular in 8 and coronal in 5 (Figure 1 and Figure 2). In the GAP technique, a U-shaped incision around the megameatus and urethral plate was performed and wide dissection of glanular wings followed this. After degloving of the penile skin, neourethra was created using 7/0 polydioxanone (PDS)<sup>®</sup> over a dripping 8Fr ventriculoperitoneal (V-P) shunt catheter in a subcuticular running uninterrupted fashion as described before.<sup>1</sup> An intermediate layer from nearby dartos fascia was interposed to support only proximal part of urethroplasty measuring of 2-3 mm in 5 patients with coronal urethral meatus and in the patients with glanular wide meatus no intermediate layer was interposed between tissue layers. After one-layer glanduloplasty using 5/0 polyglycolic acid (Vicryl)<sup>®</sup> the excess skin was trimmed and circumcision was performed. The final appearance of the penis with a vertically slit meatus at the tip of the glans penis is depicted in Figure 3. A 8 Fr dripping catheter was used and it was removed on the 6<sup>th</sup> postoperative day. The urine flow with regard to projection and calibration was evaluated 3 weeks postoperatively. The mean follow-up period was 19 months (range 6-24 months). The study was car-



**FIGURE 1:** Megameatus intact prepuce (MIP) variant of hypospadias in a boy with typical wide mouth glanular meatus.



**FIGURE 2:** Megameatus intact prepuce (MIP) variant of hypospadias in a 7-year-old boy. Note the characteristic wide mouth coronal meatus.

ried out in compliance with the Helsinki Declaration and was approved by the ethics committee of Tepecik Training Hospital, and the written consent from the families or the legal representatives of the cases were taken.

## RESULTS

Thirteen patients with MIP were treated during the period of 2 years. The ages of the patients were

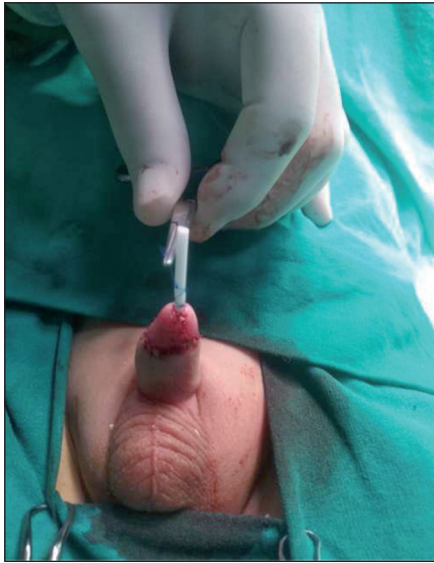


FIGURE 3: Postoperative ventral view of penis after GAP technique.

between 18 months and 7 years. All the patients were uncircumcised and they had an intact prepuce and all of our cases were diagnosed during circumcision. The planned circumcision was postponed in these cases. The total number of hypospadias cases during the study period was 85 and MIP cases constituted 15.3% of these patients. Urethral meatus was located glandular in 8 patients and coronal in 5 (Figures 1 and 2). These patients were repaired using GAP technique with an addition of an intermediate layer in 5 patients with coronal meatus to support proximal part of urethroplasty suture line and for the remaining patients with wide glandular meatus, there was no need for an intermediate layer for interposition. Good cosmetic result was obtained in all patients (Figure 3). No wound infection or disruption, an improper urine flow and unsatisfactory glanular appearance were observed in these patients. One patient developed a urethrocutaneous fistula requiring surgical closure.

## DISCUSSION

The first description of MIP was reported by Juskiewenski et al in 1983 and later only scattered number of articles have shed light on this type of hypospadias.<sup>2</sup> Duckett and Keating described this anomaly in detail.<sup>3</sup> The incidence of MIP among

hypospadiac cases in the literature is 3-6%.<sup>3-5</sup> A rather high incidence of 15.3% of all hypospadias cases in our series with respect to those reported may be explained that our clinic is a referral center for these unusual variant of hypospadias cases.

Although the embryological origin of MIP is unclear, it has been suggested that MIP is a variant of megalourethra.<sup>6,7</sup> Although it has been suggested that the origin might be the consequence of neonatal circumcision by some authors, this has been discarded by Peretz and Westreich.<sup>7</sup> MIP is not a certain type of hypospadias but rather it includes a spectrum of different appearances.<sup>5</sup> The distinct anatomical features of MIP include a spatulated glans with a distal, wide patulous meatus located at the glans penis or at the deep subcoronal groove, an intact foreskin, a very thin corpus spongiosum and no ventral chordee and if chordee is present, it is invariably dorsal.<sup>3</sup> There are no other urological anomalies associated with MIP so no radiological evaluation is needed in these patients.

A careful clinical examination is important in diagnosing MIP. Before any circumcision, it is recommended that the foreskin should be fully retracted and the glans with urethral meatus inspected. There are conflicting opinions of the effect of circumcision in patients with MIP. According to some researchers, circumcision limits the success of surgical interventions in patients with MIP.<sup>8-13</sup> Others oppose this notion and according to them, the prepuce does not have any importance in the repair of MIP.<sup>3,14,15</sup> It has been stated that circumcision did not seem to be associated with a high complication rate in MIP patients.<sup>15</sup> It is commonly admitted that when MIP is discovered during circumcision, the circumcision should be postponed and the families should be informed about this.<sup>16,17</sup>

With respect to the timing of surgical treatment in MIP variant of hypospadias, similar to the other forms of hypospadias, the surgical intervention should be performed between the ages of 6 and 18 months. The aims of surgery in MIP include to have a normal conical glans, an urethral meatus with a normal caliber and a normal urinary stream without any symptoms.<sup>18</sup>

Although the GAP is a very easy handy procedure, the most problematic part could be to obtain the conical shape of the glans since sometimes proximal glans is very thin. In those specific cases, proximal glanular detachment or urethral stricture can be seen. Stricture is thought to be poor glanular blood supply over the neourethra. Indeed, pyramid or flap surgeries are developed because of those troubling complications. Hopefully, in our series no proximal glanular detachment or urethral stricture was seen. Another point that must be addressed is the use of urethral catheters in these cases following surgical intervention. Although there are cases of MIP treated with GAP technique without using urethral catheter, our clinical algorithm in these cases includes the use of urethral catheter for decompressive purposes. Six days of urine drainage in our cases after surgical intervention was found to be enough.

Urethrocutaneous fistula at the glans, particularly proximal one is the worst horrifying complication. It may easily end up with a full complete redo repair of the case. In our series only one patient developed urethrocutaneous fistula which was repaired with fistula closure only without necessitating complete redo repair. Another point is the overlying barrier layer in some GAP cases. It generally harms the coronal groove appearance of the glans and almost always retract into penis.

Several surgical approaches have been suggested for the treatment of MIP. These are GAP, the pyramid urethroplasty, cutaneous advancement procedure, subcutaneous frenulum flap urethroplasty, perimeatal based flaps, meatal advancement and glanuloplasty (MAGPI) technique and tubularized incised plate urethroplasty.<sup>3,5,8-14,19,20</sup> Our choice of surgical treatment in these cases is GAP technique and in the presented series, GAP has been the preferred surgical treatment with excellent results. The GAP technique does not require for large flaps like the Thiersch-Duplay method.<sup>19,21</sup> Except for more severe cases, the GAP technique

should be the first choice of surgical treatment in MIP patients. Although in the original GAP technique there is no use of urethral stents, in our series 8 Fr V-P dripping shunt catheters were used without any morbidities.

## CONCLUSION

In conclusion, due to wide spectrum of locations of urethral meatus, MIP may pose a surgical challenge for attending surgeon. The GAP technique should be a choice of surgical treatment in most of the cases with MIP producing good cosmetic results and patient satisfaction with conical appearing glans penis, vertically slit urethral meatus having straight urine stream. In GAP technique, complications are rare and satisfactory functional outcomes are usually achieved.

### **Informed Consent**

*Informed consent was obtained from all individual participants included in the study.*

### **Source of Finance**

*During this study, no financial or spiritual support was received neither from any pharmaceutical company that has a direct connection with the research subject, nor from a company that provides or produces medical instruments and materials which may negatively affect the evaluation process of this study.*

### **Conflict of Interest**

*No conflicts of interest between the authors and / or family members of the scientific and medical committee members or members of the potential conflicts of interest, counseling, expertise, working conditions, share holding and similar situations in any firm.*

### **Authorship Contributions**

**Idea/Concept:** Volkan Sarper Erikci; **Design:** Ali Sayan; **Control/Supervision:** Gökhan Köylüoğlu; **Data Collection and/or Processing:** Tunç Özdemir; **Analysis and/or Interpretation:** Volkan Sarper Erikci; **Literature Review:** Mustafa Onur Öztan; **Writing the Article:** Volkan Sarper Erikci; **Critical Review:** Gökhan Köylüoğlu; **References and Fundings:** Volkan Sarper Erikci; **Materials:** Volkan Sarper Erikci.



## REFERENCES

- Ulman I, Erikçi V, Avanoğlu A, Gökdemir A. The effect of suturing technique and material on complication rate following hypospadias repair. *Eur J Pediatr Surg.* 1997;7(3):156-7. [[Crossref](#)] [[PubMed](#)]
- Juskiewenski S, Vaysee P, Guitard JK, Moscovoci J. [Treatment of anterior hypospadias. Place of balanoplasty]. *Chir Pediatr.* 1983;24(1):75-9. [[PubMed](#)]
- Duckett JW, Keating MA. Technical challenges of the megameatus intact prepuce hypospadias variant: the pyramid procedure. *J Urol.* 1989;141(6):1407-9. [[Crossref](#)] [[PubMed](#)]
- Sanal M, Karadağ E, Konca Y, Kocabaşoğlu U. Megameatus and intact prepuce (MIP) associated with meatal web: a case report. *Acta Chir Austriaca.* 2000;32:35-6. [[Crossref](#)]
- Bar-Yosef Y, Binyamini J, Mullerad M, Matzkin H, Ben-Chaim J. Megameatus intact prepuce hypospadias variant: application of tubularized incised plate urethroplasty. *Urology.* 2005;66(4):861-4. [[Crossref](#)] [[PubMed](#)]
- Duckett JW. Hypospadias. In: Campbell MF, Walsh PC, Retik AB, eds. *Campbell's Urology.* 7<sup>th</sup> ed. Philadelphia: Saunders; 1998. p.2093-119.
- Peretz D, Westreich M. Pseudo-iatrogenic hypospadias: the megameatus intact-prepuce hypospadias variant. *Plast Reconstr Surg.* 2003;111(3):1182-5. [[Crossref](#)] [[PubMed](#)]
- Gittes GK, Snyder CL, Murphy JP. Glans approximation procedur urethroplasty for the wide, deep meatus. *Urology.* 1998;52(3):499-500. [[Crossref](#)] [[PubMed](#)]
- Docimo SG. Subcutaneous frenulum flap (SCUFF) for iatrogenic or primary megameatus and reoperative hypospadias repair. *Urology.* 2001;58(2):271-3. [[Crossref](#)] [[PubMed](#)]
- Hill GA, Wacksman J, Lewis AG, Sheldon CA. The modified pyramid hypospadias procedure: repair of megameatus and deep glanular groove variants. *J Urol.* 1993;150(4):1208-11. [[Crossref](#)] [[PubMed](#)]
- Hinman F, Baskin LS. Glans approximation procedure. In: Hinman F, Baskin LS, eds. *Hinman's Atlas of Pediatric Urologic Surgery.* 2<sup>nd</sup> ed. Philadelphia: Saunders, Elsevier; 2008. p.698-9. [[Crossref](#)]
- Hinman F, Baskin LS. Pyramid procedure for repair of the megameatus intact prepuce hypospadias variant. In: Hinman F, Baskin LS, eds. *Hinman's Atlas of Pediatric Urologic Surgery.* 2<sup>nd</sup> ed. Philadelphia: Saunders, Elsevier; 2008. p.700-3. [[Crossref](#)]
- Azmy AF. Megameatus intact prepuce variant. In: Azmy AF, Hadidi AT, eds. *Hypospadias Surgery: an Illustrated Guide.* New York: Springer; 2004. p.135-8. [[Crossref](#)]
- Pieretti RV, Pieretti A, Pieretti-Vanmarcke R. Circumcised hypospadias. *Pediatr Surg Int.* 2009;25(1):53-5. [[Crossref](#)] [[PubMed](#)]
- Snodgrass WT, Khavari R. Prior circumcision does not complicate repair of hypospadias with an intact prepuce. *J Urol.* 2006;176(1):296-8. [[Crossref](#)] [[PubMed](#)]
- American Academy of Pediatrics. Report of the task force on circumcision. *Pediatrics.* 1989;84(2):388-91. [[PubMed](#)]
- Wilcox DT, Mouriquand P. Hypospadias. In: Thomas D, Duffy PG, Rickwood A, eds. *Essentials of Pediatric Urology.* 1<sup>st</sup> ed. United Kingdom: Informa Healthcare; 2002. p.213-31. [[Crossref](#)]
- Cendron M. The megameatus, intact prepuce variant of hypospadias: use of the inframeatal vascularized flap for surgical correction. *Front Pediatr.* 2018;6:55. [[Crossref](#)] [[PubMed](#)] [[PMC](#)]
- Zaontz MR. The GAP (glans approximation procedure) for glanular/coronal hypospadias. *J Urol.* 1989;141(2):359-61. [[Crossref](#)] [[PubMed](#)]
- Nonomura K, Kakizaki H, Shimoda N, Koyama T, Murakumo M, Koyanagi T. Surgical repair of anterior hypospadias with fish-mouth meatus and intact prepuce based on anatomical characteristics. *Eur Urol.* 1998;34(4):368-71. [[Crossref](#)] [[PubMed](#)]
- Zaontz MR, Dean GE. Glandular hypospadias repair. *Urol Clin North Am.* 2002;29(2):291-8. [[Crossref](#)] [[PubMed](#)]