

# Becker Nevus Syndrome with Bilateral Skin Involvement and Skeletal Malformations: A Rare Case

## Bilateral Deri Tutulumu ve İskelet Malformasyonlarının Eşlik Ettiği Becker Nevüs Sendromu: Nadir Bir Olgu

Atiye AKBAYRAK<sup>a</sup>, Cemre YAZAR<sup>a</sup>, Elif ÇETİN<sup>b</sup>, Nurdan YILMAZ<sup>c</sup>

<sup>a</sup>Department of Dermatology and Venereology, Gaziosmanpaşa University Faculty of Medicine, Tokat, TURKEY

<sup>b</sup>Department of Pathology, Gaziosmanpaşa University Faculty of Medicine, Tokat, TURKEY

<sup>c</sup>Department of Physical Therapy and Rehabilitation, Gaziosmanpaşa University Faculty of Medicine, Tokat, TURKEY

**ABSTRACT** Becker nevus (BN) is a hamartomatous lesion characterized by a hyperpigmented patch generally located in the shoulder or upper trunk. Although BN is reported to be congenital, it is frequently seen in the first or second decade. A diagnosis of BN can be made based on clinical findings and, ideally, a skin biopsy of the lesion. Becker nevus syndrome (BNS), which belongs to the epidermal nevus syndrome group, is a rare disorder characterized by BN associated with skin, muscle, or skeletal anomalies. Ipsilateral breast hypoplasia is the most common skin finding in BNS. Bilateral skin involvement is rarely seen in the syndrome. Herein, we present a female patient with BNS associated bilateral BN and musculoskeletal findings.

**ÖZET** Becker nevus (BN), genellikle omuz veya üst gövdede yerleşen hiperpigmente yama ile karakterize, hamartomatöz bir lezyondur. BN'nin konjenital olduğu bildirilse de, sıklıkla birinci veya ikinci dekatta ortaya çıkar. Tanısı klinik bulgularla konulabilmekle birlikte, ideal olan lezyondan deri biyopsidir. Epidermal nevus sendromu grubunda yer alan Becker Nevüs Sendromu (BNS), BN'ye eşlik eden deri, kas ve iskelet anomalileriyle karakterize nadir bir bozukluktur. BNS'unun en sık deri bulgusu ipsilateral meme hipoplazisidir. Sendromda bilateral deri tutulumu ise, oldukça nadirdir. Burada, bilateral BN ve iskelet-kas bulguları olan BNS'lu bir kadın olguyu sunduk.

**Keywords:** Becker nevus; Becker nevus syndrome; bilateral; scoliosis; sacralization

**Anahtar Kelimeler:** Becker nevus; becker nevus sendromu; bilateral; skolyoz; sakralizasyon

Becker nevus (BN) is a hamartomatous lesion characterized by a hyperpigmented patch located in the shoulder or pectoral region of adolescent men.<sup>1</sup> Becker nevus syndrome (BNS) is defined as the association of BN with skin, muscle, or skeletal anomalies. In BNS, the most common skin finding is ipsilateral breast hypoplasia and bilateral localization of BN is very rare. We report a case of BNS with bilateral skin involvement and musculoskeletal malformations.

### CASE REPORT

A 15-year-old female patient presented to dermatology clinic with two asymptomatic brown patches on

the trunk. The patches had been present since the age of five and have recently expanded and increased in darkness. We observed two patches with irregular borders on skin examination. One of them was located between the medial aspect of the right breast and the side of the trunk. It was about 15x25 cm in size and light brown in color. The other one was dark brown, about 18x18 in size extending down from below the left breast to the upper umbilicus (Figure 1). There were hyperpigmented hair in the outer regions of both lesions. The patient had no history of a systemic disease, drug use, allergy, or family history of similar lesions. Laboratory tests (complete blood count,

**Correspondence:** Atiye AKBAYRAK

Department of Dermatology and Venereology, Gaziosmanpaşa University Faculty of Medicine, Tokat, TURKEY/TÜRKİYE

**E-mail:** aogrum@yahoo.com



Peer review under responsibility of Türkiye Klinikleri Journal of Dermatology.

**Received:** 2 Jul 2020

**Received in revised form:** 27 Sep 2019

**Accepted:** 7 Oct 2019

**Available online:** 24 Dec 2020

2146-9016 / Copyright © 2020 by Türkiye Klinikleri. This is an open access article under the CC BY-NC-ND license (<http://creativecommons.org/licenses/by-nc-nd/4.0/>).

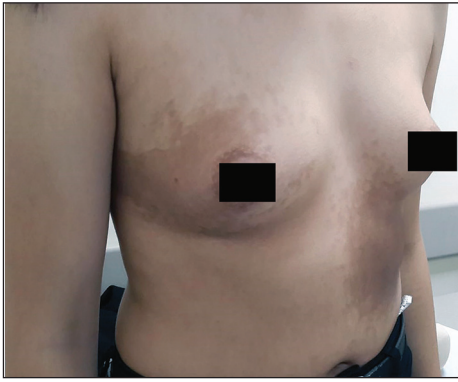


FIGURE 1: Two brown patches with irregular borders on the trunk.

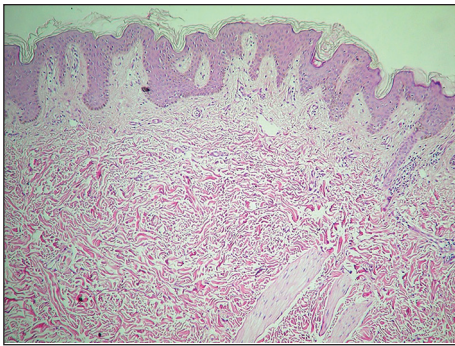


FIGURE 2: Moderate acanthosis in the epidermis, elongation of rete ridges, increased pigmentation in the basal layer, and smooth muscle bundles in the dermis not associated with hair follicles. (H&E x200).

liver function tests, and renal function tests) were within normal limits. Histopathological examination of the samples taken from both lesions revealed moderate acanthosis in the epidermis, elongation of rete ridges, increased pigmentation in the basal layer, and smooth muscle bundles in the dermis not associated with hair follicles (Figure 2). The findings were consistent with BN. Vertebral X-ray revealed scoliosis of 10 degrees in the left thoracolumbar region and sacralization (assimilation of L5 to the sacrum) (Figure 3). The patient was diagnosed with BNS using clinical, histopathological, and imaging methods. She was referred to the physical therapy clinic for scoliosis follow-up.

Written informed consent was obtained from the patient.

## DISCUSSION

BNS, which belongs to the epidermal nevus syndrome group, is a rare entity with non-skin malfor-

mations accompanied by a hamartomatous lesion.<sup>2</sup> The syndrome was first described by Happle in 1995.<sup>3</sup> The incidence of BNS is similar in both sexes unlike BN, which shows male predominance.<sup>3</sup> However, there are also studies reporting female predominance in BNS.<sup>2,4</sup>

Although BN is reported to be congenital, it is frequently seen in the first or second decade.<sup>3</sup> This clinical finding is known to result from increased androgen sensitivity at the lesion site. BN is often localized unilaterally with very few cases showing bilateral localization. It is usually localized on the shoulder and upper trunk.<sup>3,5</sup> However, abdominal skin lesions are one of the rare areas. In our case, the skin lesions were bilateral and these were located in the chest and abdominal regions.

A diagnosis of BN can be made based on clinical findings and, ideally, a skin biopsy of the lesion.<sup>6</sup> Histologically it is characterized by moderate acanthosis with elongation of the rete ridges and a variable degree of hyperkeratosis. The basal layer of the epidermis is hyperpigmented, although there is no increase in the number of melanocytes. Melanophages are present in the dermis and there is an increase in the number of arrector pili muscles.<sup>6</sup> We reached the

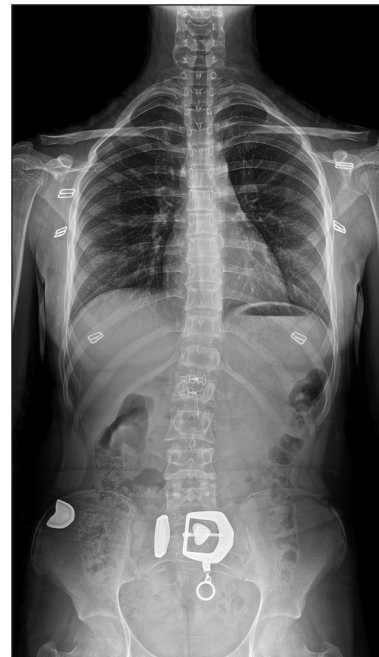

FIGURE 3: Scoliosis in the left thoracolumbar region and sacralization (Vertebral X-ray).

diagnosis through clinical findings and histopathological examination.

It has been reported that the most common malformation associated with BNS is ipsilateral breast hypoplasia and its frequency is higher in women.<sup>2</sup> It is thought that it is associated with increased androgen receptor levels at the lesion site. Jung et al. tried to treat hypoplasia with an anti-androgenic agent in a case of BNS and one month later they observed breast enlargement in the hypoplastic breast.<sup>7</sup> Another rare breast-related finding is supranumerary nipples.<sup>2</sup> There were no breast related malformations in our case.

The most common musculoskeletal malformations associated with the syndrome are extremity hypo/hyperplasia and scoliosis.<sup>8</sup> Maessen-Visch et al. found that scoliosis was observed in 26% of individuals with BN, while this rate is 2% in the normal population.<sup>9</sup> In the study of Schneider et al. with 84 BNS patients scoliosis was reported to be the third most common finding and more common in females and with thoracolumbar localization.<sup>2</sup> Our case was consistent with the literature in terms of gender and localization. We additionally found sacralization. Rare findings associated with the syndrome in the literature are genital malformation, lipodystrophy, maxillofacial dysplasia, pectoralis major muscle hypoplasia, or absence.<sup>2</sup>

According to a systematic review by Schneider et al., there is a regional correspondence between BN and non-skin malformation.<sup>2</sup> It has been suggested that this condition might be related to common mutation during embryogenesis. Breast hypoplasia, lipodystrophy, and maxillofacial dysplasia were reported to have the

strongest regional correspondence. However, this correspondence between BN and scoliosis could not be evaluated.

In conclusion, we reported a rare case of BNS with bilateral skin involvement, but the associated anomalies, scoliosis and sacralization. BNS is most commonly associated with skin-related malformations. However, even if skin findings are not observed, it can be useful to keep the possibility of BNS in mind in cases with Becker nevus.

#### Source of Finance

*During this study, no financial or spiritual support was received neither from any pharmaceutical company that has a direct connection with the research subject, nor from a company that provides or produces medical instruments and materials which may negatively affect the evaluation process of this study.*

#### Conflict of Interest

*No conflicts of interest between the authors and / or family members of the scientific and medical committee members or members of the potential conflicts of interest, counseling, expertise, working conditions, share holding and similar situations in any firm.*

#### Authorship Contributions

**Idea/Concept:** Atiye Akbayrak, **Design:** Atiye Akbayrak; **Control/Supervision:** Atiye Akbayrak; **Data Collection and/or Processing:** Atiye Akbayrak, Cemre Yazar, Elif Çetin, Nurdan Yılmaz; **Analysis and/or Interpretation:** Atiye Akbayrak, Elif Çetin, Nurdan Yılmaz; **Literature Review:** Atiye Akbayrak, Cemre Yazar; **Writing the Article:** Atiye Akbayrak; **Critical Review:** Atiye Akbayrak; **References and Fundings:** Atiye Akbayrak; **Materials:** Atiye Akbayrak, Cemre Yazar, Elif Çetin, Nurdan Yılmaz.

## REFERENCES

- Happle R, Koopman RJ. Becker nevus syndrome. *Am J Med Genet.* 1997;31;68(3):357-61. [\[Crossref\]](#) [\[PubMed\]](#)
- Schneider ME, Fritsche E, Hug U, Giovanoli P. Becker nevus syndrome and ipsilateral breast hypoplasia: a systematic literature review. *Eur J Plast Surg.* 2017;40(6):489-98. [\[Crossref\]](#)
- Alfaro A, Torreló A, Hernández A, Zambrano A, Happle R. [Becker nevus syndrome]. *Actas Dermosifiliogr.* 2007;98(9):624-6. [\[Crossref\]](#) [\[PubMed\]](#)
- Danarti R, König A, Salhi A, Bittar M, Happle R. Becker's nevus syndrome revisited. *J Am Acad Dermatol.* 2004;51(6):965-9. [\[Crossref\]](#) [\[PubMed\]](#)
- Yüksel EN, Kocatürk E, Duman H, Kunter AS, Cüre K, Korkmaz Ö. [Becker nevus on the face: a rare presentation: case report]. *Turkiye Klinikleri J Dermatol.* 2017;27(2):69-71. [\[Crossref\]](#)
- Cosendey FE, Martinez NS, Bernhard GA, Dias MF, Azulay DR. [Becker nevus syndrome]. *An Bras Dermatol.* 2010;85(3):379-84. [\[Crossref\]](#) [\[PubMed\]](#)
- Hoon Jung J, Chan Kim Y, Joon Park H, Woo Cinn Y. Becker's nevus with ipsilateral breast hypoplasia: improvement with spironolactone. *J Dermatol.* 2003;30(2):154-6. [\[Crossref\]](#) [\[PubMed\]](#)
- Schneider ME, Draths R, Fritsche E, Hug U. [The interesting case: unilateral hypoplasia of the breast in Becker nevus syndrome]. *Handchir Mikrochir Plast Chir.* 2014;46(4):266-7. [\[Crossref\]](#) [\[PubMed\]](#)
- Maessen-Visch MB, Hulsmans RF, Hulsmans FJ, Neumann HA. Melanosis naeviformis of Becker and scoliosis: a coincidence? *Acta Derm Venereol.* 1997;77(2):135-6. [\[Crossref\]](#) [\[PubMed\]](#)