

B-Cell Lymphoma Lesions Localized on the Mandible: Case Report

Mandibulada Lokalize B-Hücreli Lenfoma Lezyonları

Zühre ZAFERSOY AKARSLAN,^a
Ceyda KOCABAY,^b
Volkan AKAR,^b
Elif GÜLTEKİN,^c
Nalan AKYÜREK,^d

Departments of
^aOral Diagnosis and Radiology,
^bOral and Maxillofacial Surgery,
^cOral Pathology,
Gazi University Faculty of Dentistry,
^dDepartment of Surgical Pathology,
Gazi University Faculty of Medicine,
ANKARA

Geliş Tarihi/Received: 07.05.2007
Kabul Tarihi/Accepted: 12.06.2007

This case report took place as a poster presentation at the Aegean region chambers of dentists 7th International scientific congress and exhibition held on 27-29 April 2006 in Fethiye.

Yazışma Adresi/Correspondence:
Zühre ZAFERSOY AKARSLAN
Gazi University Faculty of Dentistry
Department of Oral Diagnosis and
Radiology, ANKARA
dtzuhre@yahoo.com

ABSTRACT In this case report, a patient who admitted to our clinic for the treatment of two lesions localized on the mandible, which in real were both B-cell Non-Hodgkin Lymphoma (NHL) lesions according to histopatological examination, is presented. A 71 year old male patient admitted to our clinic for the treatment of two painless and rapidly developing lesions localized on the mandible. Intraoral examination revealed a mass on the anterior, and a swelling associated with three molar teeth at the posterior region of the mandible. According to the histopatolocial examination, the lesions were found to be B-cell Non-Hodgkin Lymphoma's, and subsequently the patient was referred to the Oncology department to receive detailed examination and treatment. The patient was found to be at the terminal stage and had metastases of lymphoma. Primary or metastatic NHL lesions could be present in the oral cavity, therefore oncologists and dentists should be aware of this situation.

Key Words: Lymphoma; mandible; radiography

ÖZET Bu olgu sunumunda mandibulada lokalize ve yapılan histopatolojik inceleme sonucu Non-Hodgkin Lenfoma (NHL) tanısı konulan iki lezyonun tedavisi için kliniğine başvuran bir hasta rapor edilmektedir. Yetmiş bir yaşındaki erkek hasta mandibulada lokalize, hızlı büyüyen, ağrısız iki lezyonun tedavisi amacı ile kliniğimize başvurdu. Yapılan intraoral muayenede, anterior bölgede lokalize bir kitle ve posterior bölgede üç molar dişle ilişkili bir şişlik olduğu tespit edildi. Histopatolojik inceleme sonucunda lezyonların her ikisine de B-Hücreli Non-Hodgkin Lenfoma tanısı konularak, hasta ileri tetkik ve tedavi için onkoloji kliniğine yönlendirildi. Onkoloji kliniğinde yapılan tetkikler sonucuna, hastanın vücudunda lenfoma lezyonlarının metastazının bulunduğu ve hastalığın terminal safhasında olduğu belirlendi. Dişhekimleri ve onkolojistler, primer veya metastatik NHL lezyonlarının oral kavitede lokalize olabileceklerini göz önünde bulundurmaldırlar.

Anahtar Kelimeler: Lenfoma; mandibula; radyografi

Türkiye Klinikleri J Dental Sci 2008, 14:52-56

Lymphomas are hematopoetic neoplasms originating from immunocomponent cells, the lymphocytes, that spread to other lymphoid and nonlymphoid tissues, either by direct infiltration or hematogenous dissemination.¹

According to their differences in behavior pattern and histology, they are divided into two groups as, Hodgkin's disease (HD) and Non-Hodgkin's lymphoma (NHL).² HD almost always begins in the lymph nodes. NHL ari-

ses within lymph nodes³ and extranodal sites. Nearly 25% of the NHL's are reported to be localized at extranodal regions.^{4,5}

NHL is usually presented as an extranodal disease in the oral cavity. It may develop in the oral soft tissues or centrally within the jaws. Soft tissue lesions are non-tender, diffuse swellings and are generally localized in the buccal vestibule gingiva or the posterior region of the hard palate. The mucosa covering the lesions may be erythematous or purplish and sometimes ulcerated. The lesion could cause expansion of the bone, which perforates the cortical plate and produce a soft tissue swelling.³ Lesions arising in the jaws usually have non-specific symptoms, sometimes mimicking dental pathologies, such as a painful or painless swelling with numbness, parasthesia, mobility of teeth and cervical lymphadenopathy.⁶

Although there are various types, diffuse large B-cell lymphoma is reported to be the most frequent type.⁶⁻⁹ It is an aggressive lesion and sometimes mimics dental pathologies such as periodontitis, periodontal abscess, or osteomyelitis, so early diagnosis is important for proper treatment and survival, therefore, the dentist and oncologist should be aware of the condition.

The aim of the present case is to report the patient who was unaware of the two NHL lesions localized on the mandible, which differed in both clinical and radiographic appearance and referred to a dentist for treatment.

CASE REPORT

In November 2005, a 71 year old white male admitted to the Oral Diagnosis and Radiology Department with a complaint of a painless, rapidly proliferating mass and a swelling on the mandible during the recent weeks. Informed written consent was taken from the patient.

According to the patients' history, he had no systemic diseases, was non-medicated, but recently loss weight and perspired at night.

At the extraoral examination neither asymmetry, nor swelling was present. There was no lymphadenopathy at the submental, submandibular and cervical lymph nodes also.

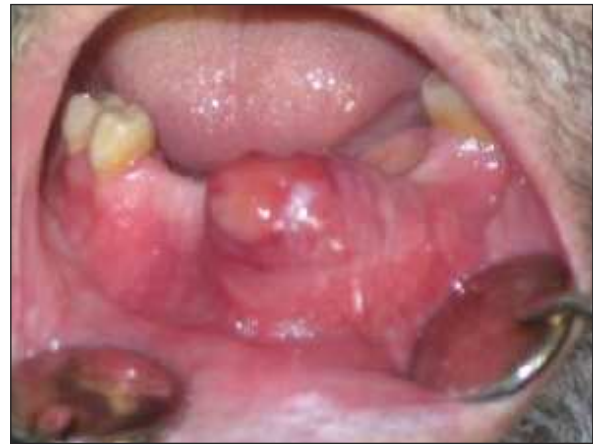

FIGURE 1. Intraoral appearance of the mass localized at the anterior region of the mandible.

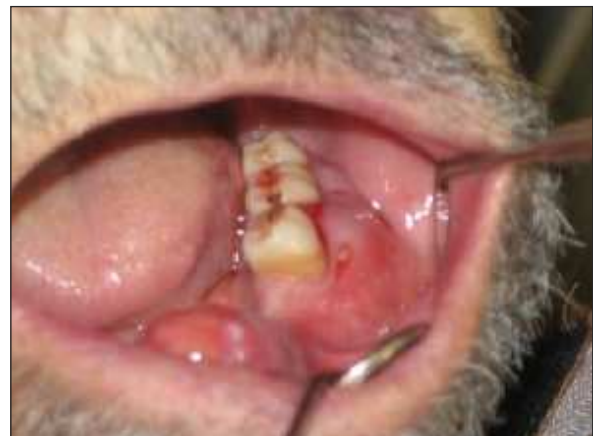

FIGURE 2. Intraoral appearance of the swelling localized at the posterior region of the mandible.

phadenopathy at the submental, submandibular and cervical lymph nodes also.

Intraoral examination revealed a mass on anterior region of vestibule mandible (Figure 1) and a swelling on the buccal gingival, associated with molar teeth (Figure 2). The oral hygiene status of the patient was poor.

The mass was firm, covered with purplish mucosa, including erythematous regions with no ulceration and has been rapidly growing during the recent weeks. There were no teeth associated with the lesion as they were extracted a long time ago. A radiolucent lesion with irre-

gular borders was seen on the panoramic radiograph.

The swelling was covered with normal featured mucosa, associated with three molar teeth, having prosthetic restorations and was painless. The teeth were mobile, having deep periodontal pockets but there was no puss derange. On the panoramic radiographic, a large radiolucent lesion, with irregular borders and disappearance of lamina dura of the roots of the first and second molar teeth was seen (Figure 3).

The clinical and radiographic appearances of the two lesions were apparently different from each others.

The clinical and radiographic appearance of the mass was not specific and it was thought it could be a malign lesion. Although the swelling resembled periodontal abscess, the painless history and the absence of puss derange, even in the past time, lead to a question in mind and incisional biopsies were made from both lesions.

Microscopically for both lesions, a diffuse tumoral infiltration which was composed of atypical lymphoid cells was observed from the ulcerated surface epithelium of mucosa through the bone. The malign cells were centroblast like cells with medium sized cytoplasm and they had large vesicular nuclei. Mitotic figures were frequently available. Apoptotic cells were seen within the tingible body macrophages (Figure 4). In immunohistochemical studies, neoplastic cells showed diffuse, strong and membranous staining with CD45 (LCA) and CD 20 (Figure 5) whereas rare mature T-cell lymphocytes were positively stained with CD3 and

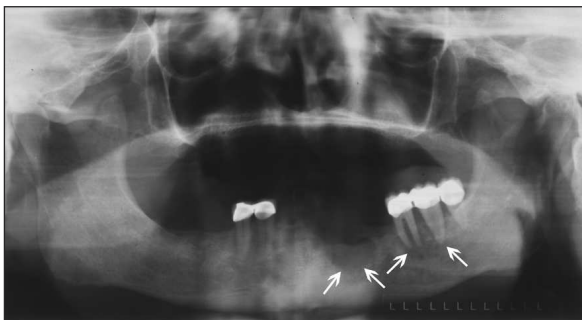

FIGURE 3. Panoramic radiograph of the patient.

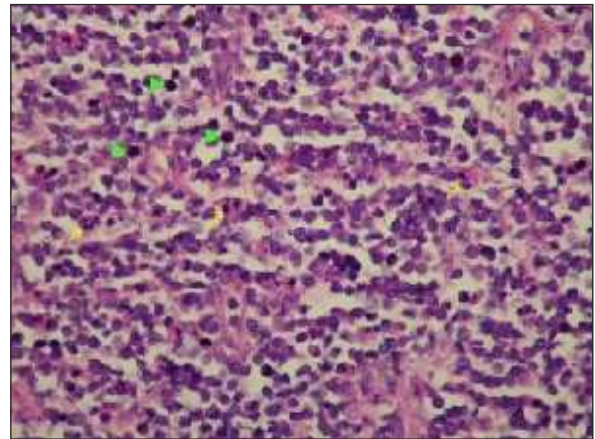


FIGURE 4. The tumour was composed of centroblast like malign cells. Tingible body macrophages (arrow) and mitotic figures were frequently present. (H&E, x100).

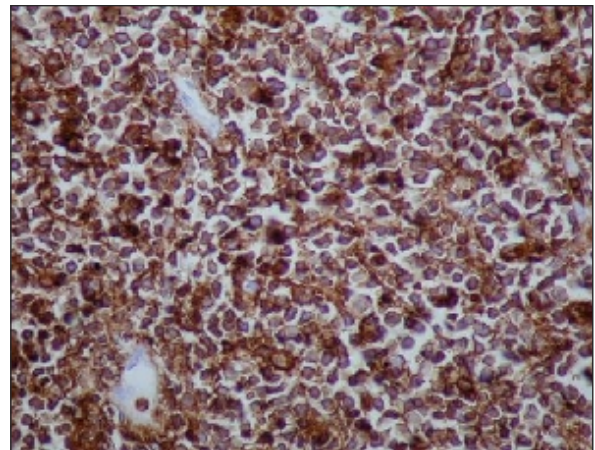


FIGURE 5. Strong and membranous CD 20 staining of neoplastic cells (DAB, x 200).

CD 5. Neoplastic cells had no staining with S-100 Cyclin D1, CD 38 and TdT antibodies. These findings revealed the diagnosis of Diffuse Large B cell Lymphoma according to WHO classification for both lesions.

Subsequently, the patient was referred to the Oncology Department for further examination and treatment. After the oncologists' physical examination, blood cell count, bone marrow biopsy, conventional radiographs taken from head, neck, chest and pelvic abdominal regions, it was confir-

med that the primary lesion was localized on the lungs and the lesions localized on the mandible were metastases of NHL. The patient was found to be at the terminal stage of the diseases. The patient passed away approximately three weeks after his visit to Oral Diagnosis and Radiology department; therefore neither further examination, nor treatment could be done.

DISCUSSION

In the present case report, based on clinical, radiological and histopathological examinations, both the mass and swelling were considered as NHL lesions. The importance of this case is that, the NHL lesions were localized in the oral cavity and the patient was unaware of his disease and referred to a dentist for treatment. In addition, although the two lesions were same, they differed in both clinical and radiographic features. The difference of the two lesions could be related with the teeth, as the teeth were absent in the anterior region, where the mass developed and were present in the posterior region, where the swelling developed. Dentists and oncologists should keep this in mind as multiple NHL lesions could be present in the same case with different features, so biopsy should be made for correct diagnosis.

It is reported that NHL lesions arising in the jaws usually have non-specific symptoms, such as a painful or painless swelling, numbness, paresthesia, mobility of teeth and cervical lymphadenopathy.^{2,9-12} In our case, the lesion present as a diffuse swelling showed such clinical features; as it was painless and the associated teeth were mobile.

The radiographic appearance of the NHL lesions show variations and are non-specific. They are commonly seen as a diffuse radiolucent lesion, disappearance of lamina dura of the associated teeth, resorption of the alveolar bone margin, resembling periodontitis or periodontal abscess.¹³ Sometimes, osteoblastic activity and bone resorption could occur together, thus appearing as a mixed radioopaque-radiolucent lesion.² In rare

cases, NHL lesions could cause a progressive increase in the size of mandibular¹⁴ and mental foramen.¹⁵ In addition, these lesions are shown to lead to a widening in the mandibular canal also.¹⁴⁻¹⁶ Yamada et al.¹⁴ reported a NHL lesion causing widening, extending from the mandibular foramen to the mental foramen, on a panoramic radiograph without bone destruction. In our case, the first lesion's radiographic appearance was a large radiolucent lesion with ill defined borders and the second as a large diffuse radiolucent lesion involving the first and second molars roots and furcations with disappearance of lamina dura.

According to the WHO classification, the NHL's are grouped into three types: Precursor cell Lymphoma, Peripheral B-cell neoplasms and Peripheral T and NK cell neoplasm's. In our case pathological examination revealed diffuse large B-cell Non-Hodgkin's Lymphoma. It is grouped as a subtype of peripheral B-cell lymphomas. According to the Non-Hodgkin's Lymphoma classification project data, it is the commonest type seen with a rate of 31%, followed by follicular (22%), B chronic lymphocytic leukemia/small lymphocytic lymphoma (6%), mantle cell (6%), peripheral T-cell (6%) and extra nodal marginal zone B-cell lymphoma of MALT type (5%).¹⁷

Although great progress in the treatment of NHL has been made in the last years, it is still, difficult to achieve and sustain remission in different lymphoma subtypes and some patients have poor prognosis. Monoclonal, antibodies, radioimmunotherapy, autologous stem cell transplantation are currently used modalities for the treatment of NHL.¹⁸⁻²⁰ As our patient was at the terminal stage no treatment could be done in our case.

As a conclusion, multiple NHL lesions could be present in the oral cavity with different clinical and radiographical features and the patient could be unaware of this condition, referring to a dentist for treatment, therefore dentists should be aware of this situation.

REFERENCES

- Kelly JJ, Karcher DS. Lymphoma and peripheral neuropathy: A clinical review. *Muscle Nerve* 31: 301, 2005
- Kolokotronis A, Konstantinou N, Christakis I, Papadimitriou P, Matiakis A, Zaraboukas T et al: Localized B-cell non-Hodgkin's lymphoma of oral cavity and maxillofacial region. A clinical study. *Oral Surg Oral Med Oral Pathol Oral Radiol Endod* 99: 303, 2005
- Neville BW, Damm DD, Allen CM, Bouquot JE: *Oral and Maxillofacial Pathology*. Philadelphia: WB Saunders, 1995, p. 431
- Rinaggio J, Aguirre A, Zeid M, Hatton MN: Swelling of nasolabial area. *Oral Surg Oral Med Oral Pathol Oral Radiol Endod* 89: 669, 2000
- Dey P, Luthra UK, Sheikh ZA, Mathews SB: Fine needle aspiration of primary non-Hodgkin's lymphoma of the tongue. A case report. *Acta Cytol* 43: 422, 1999
- Shindoh M, Takami T, Arisue M, Yamashita T, Saito T, Kohgo T et al.: Comparison between submucosal (extra-nodal) and nodal non-Hodgkin's lymphoma (NHL) in the oral and maxillofacial region. *J Oral Pathol Med* 26: 283, 1997
- Epstein JB, Epstein JD, Le ND, Gorsky M: Characteristics of oral and paraoral malignant lymphoma. A population-based review of 361 cases. *Oral Surg Oral Med Oral Pathol Oral Radiol Endod* 92: 519, 2001
- Regezi JA, Zarbo RJ, Stewart JC: Extra nodal oral lymphomas: Histological subtypes and immunophenotypes (in routinely processed tissue). *Oral Surg Oral Med Oral Pathol Oral Radiol Endod* 72: 702, 1991
- Leong IT, Fernandes BJ, Mock D: Epstein Barr virus detection in non-Hodgkin's lymphoma of the oral cavity: an immunocytochemical and in situ hybridization study. *Oral Surg Oral Med Oral Pathol Oral Radiol Endod* 92: 184, 2001
- Pecorari P, Melato M: Non-Hodgkin's lymphoma (NHL) of the oral cavity. *Anticancer Res* 18: 1299, 1998
- Eisenbud L, Sciubba J, Mir R, Sachs SA: Oral presentations in Non-Hodgkin's lymphoma: a review of thirty-one cases. Part I. Data analysis. *Oral Surg Oral Med Oral Pathol Oral Radiol Endod* 56: 151, 1983
- Söderholm A-L, Lindqvist C, Heikinheimo K, Forssell K, Happonen RP: Non-Hodgkin's lymphomas presenting through oral symptoms. *Int J Oral Maxillofac Surg* 19: 131, 1990
- Mealey BL, Tunder GS, Pemble CW: Primary extranodal malignant lymphoma affecting periodontium. *J Periodontol* 73: 937, 2002
- Yamada T, Kitagawa Y, Ogasawara T, Yamamoto S, Ishii Y, Urasaki Y: Enlargement of mandibular canal without hypesthesia caused by extranodal non-Hodgkin's lymphoma: a case report. *Oral Surg Oral Med Oral Radiol Endod* 89: 388, 2000
- Barber HD, Stewart JC, Baxter WD: Non-Hodgkin's lymphoma involving the inferior alveolar canal and mental foramen: report of a case. *J Oral Maxillofac Surg* 50: 1334, 1992
- Bertolotto M, Cecchini G, Martinoli C, Perrone R, Garlaschi G: Primary lymphoma of the mandible with diffuse widening of the mandibular canal report of a case. *Eur Radiol* 6: 637, 1996
- Chan JKC: The new World Health Organization classification of lymphomas: The past, the present and the future. *Hematol Oncol* 19: 129, 2001
- Fanale MA, Younes A: Monoclonal antibodies in the treatment of non-Hodgkin's lymphoma. *Drugs* 67: 333, 2007
- Mazur G, Wróbel T, Jarczok W, Butrym A: New trends in non-Hodgkin's lymphoma therapy. *Postepy Hig Med Dosow* 60: 707, 2006
- Macklis RM, Pohlman B: Radioimmunotherapy for non-Hodgkin's lymphoma: A review for radiation oncologists. *Int J Radiation Oncology Biol Phys* 66: 833, 2006