

Imaging Features of Primitive Neuroectodermal Tumor in the Maxilla: A Case Report and Literature Review

Maksilladaki Primitif Nöroektodermal Tümörün Görüntüleme Bulguları: Olgu Sunumu ve Literatür Derlemesi

Esin BOZDEMİR,^a
Yavuz FINDIK,^b
Elif BİLGİR,^a
Mustafa Asım AYDIN^c

Departments of
^aDentomaxillofacial Radiology,
^bOral and Maxillofacial Surgery,
Süleyman Demirel University
Faculty of Dentistry,
^cPlastic, Reconstructive and
Aesthetic Surgery,
Süleyman Demirel University
Faculty of Medicine,
Isparta

Geliş Tarihi/Received: 30.06.2016
Kabul Tarihi/Accepted: 21.10.2016

Yazışma Adresi/Correspondence:
Esin BOZDEMİR
Süleyman Demirel University
Faculty of Dentistry,
Department of Dentomaxillofacial
Radiology, Isparta,
TURKEY/TÜRKİYE
dtesin@hotmail.com

*This case report was presented as e-poster
in European Society of Head and Neck
Radiology 28th Congress and Refresher
Course, 24-26 September, 2015,
Krakow, Poland.*

ABSTRACT Primitive neuroectodermal tumor (PNET) is a term used to describe a group of highly malignant neoplasms composed of undifferentiated round cell tumors of neuroectodermal origin with variable cell differentiation. PNET generally occurs in the central nervous system (CNS), but peripheral PNET occurring outside the CNS has also been reported. The most common location of PNET in head and neck region is the orbit, followed by the neck and the parotid gland. PNET of the maxilla is rare. The aims of this report are to present the case of a 41-year-old female diagnosed with PNET tumor of the maxilla after detailed clinical, radiological, and histopathological examinations and to review the previously reported cases of PNET of the maxilla in the literature.

Key Words: Neuroectodermal tumors, primitive, peripheral; maxilla; diagnosis; cone-beam computed tomography

ÖZET Primitif nöroektodermal tümör (PNET), nöroektodermal kökenli farklılaşmamış yuvarlak hücreli tümörlerden oluşan son derece malign tümörlerin bir grubunu tanımlamak için kullanılan bir terimdir. PNET genellikle santral sinir sisteminde meydana gelir fakat santral sinir sistemi dışında ortaya çıkan periferik PNET olguları da rapor edilmiştir. Baş-boyun bölgesinde en fazla gözde görülür. Gözden sonra en sık boyun ve parotis bezinde görülür. Maksilladaki PNET nadirdir. Bu raporun amacı detaylı klinik, radyolojik ve histopatolojik incelemelerden sonra maksillada PNET tanısı koyulan 41 yaşında kadın hastayı sunmak ve literatürde daha önce rapor edilen maksilladaki PNET vakalarını incelemektir.

Anahtar Kelimeler: Nöroektodermal tümörler, primitif, periferik; maksilla; tanı; konik ışıklı bilgisayarlı tomografi

Türkiye Klinikleri J Dental Sci Cases 2016;2(3):106-12

P primitive neuroectodermal tumor (PNET) is a term used to describe a group of highly rare and malignant neoplasms composed of undifferentiated round cell tumors of neuroectodermal origin with variable cell differentiation. PNET generally occurs in the central nervous system (CNS); peripheral PNET occurring outside the CNS has also been reported. Peripheral PNET is commonly related to Ewing's sarcoma (ES). However, it exhibits a more aggressive clinical behavior than ES, with extremely rapid metastasis. PNET has a poor prognosis and is commonly seen in children and young adults.¹ Because this tumor presents aggressive biological behavior and tends toward loco-regional and systemic metastases, it is a tumor with an extremely poor survival rate.² The incidence of head and neck PNET

varies among different studies, ranging from 0% to 42%.³ The most common location of PNET in the head and neck region is the orbit; followed by the neck and the parotid gland.⁴ However, peripheral PNET has also been reported in the temporal region, paranasal sinuses, skull and masseter muscle in the head and neck region. PNET of the maxilla is rare.

The imaging features of PNETs are non-specific with regard to the differentiation of PNETs from other types of bone and soft tissue tumors and it cannot be diagnosed solely on the basis of radiographic evaluation. Both magnetic resonance imaging (MRI) and computed tomography (CT) provide valuable information about the character and extent of the tumor for preoperative evaluation and the surgical planning and in determining recurrence and metastasis.^{1,2} However, cone beam computed tomography (CBCT) is a relatively new technique that has not been routinely used for the detection of bone invasion, although it has advantages superior to conventional CT such as lesser radiation dose. The CBCT might be used instead of CT for preoperative evaluation.⁵

The aim of this report is to present the case of a 41-year-old female diagnosed with PNET of the maxilla after detailed clinical, radiological, and histopathological examinations. A further aim is to review the previously reported cases of PNET of the maxilla in the literature.

CASE REPORT

This study didn't need any approval by the ethics committee and written informed consent agreement was obtained from the patient.

A 41-year-old woman presented with severe pain, progressively enlarging mass on the right maxilla, and swelling in the right zygomatic facial region that had continued for 2 months. On intraoral examination, a tender, fixed, lobular, relatively well-defined mass that was soft in consistency was found on the right alveolar process extending to the vestibular sulcus and gingiva. There were whitish plaques with debris, calculus, and telangiectasia on the overlying mucosa (Figure 1). Extraoral exami-

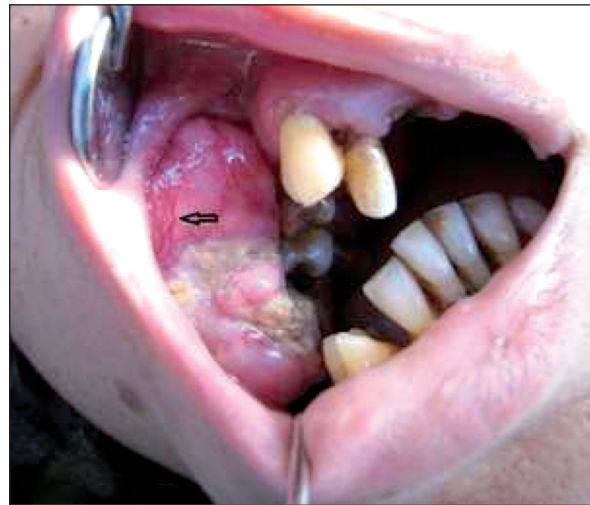

FIGURE 1: Clinical appearance of soft tissue mass on the right the alveolar process and vestibular sulcus.

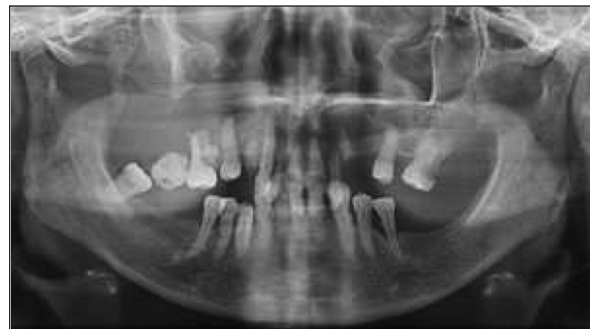

FIGURE 2: The panoramic projection showing erosion of medial, inferior and posterolateral walls of the right maxillary sinus and destruction on right maxilla with an appearance of teeth floating air.

nation revealed tender and soft diffuse swelling on the right side of the face with obliteration of the nasolabial fold resulting in facial asymmetry (Figure 2). A single enlarged submandibular lymph node was palpable on the right side. This was non-tender, firm in consistency, and immobile.

Panoramic radiography revealed destruction of the cortical outline of the posterolateral and inferior walls of the right maxillary sinus, with the molar part of the right maxilla and zygomatic buttress. It showed resorption on mesiobuccal-palatinal roots of the first molar and mesiobuccal-distobuccal-palatinal roots of second molars, with complete resorption of surrounding bone structures leading to the appearance of floating teeth on the right side of maxilla and the displacement of upper

right second molar (Figure 3). Cone beam computed tomography (CBCT) was taken prior to biopsy and revealed a dense soft tissue lesion on the right nasal cavity and maxillary and ethmoidal sinuses, with bony destruction of the medial, lateral, and posterior walls of the right maxillary sinus and the lateral displacement of medial wall of the left maxillary sinus (Figure 4, 5). An incisional biopsy specimen was taken. After clinical and radiological examination, pathologies considered as the prediagnosis were peripheral giant cell granuloma, minor salivary gland neoplasms, squamous cell carcinoma, non-Hodgkin's lymphoma. Immunohistochemistry showed strong, diffuse membrane positivity for CD99 or MIC2 and that the tumor cells also expressed neuron-specific enolase (NSE). Thus the diagnosis of PNET was made.

DISCUSSION

Clinically, PNET is seen in a wide age range, from newborn to 74 years, with a mean age of 21 years; it mainly affects children and adolescents. The sex distribution of patients has varied among different cases.¹ PNET accounts for 1-4% of all soft tissue

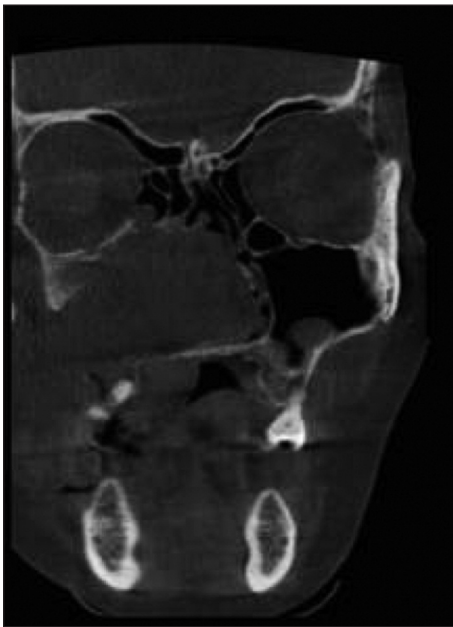

FIGURE 3: Coronal section on cone beam computed tomography revealed cortical destruction of the walls of the right maxillary sinus and medially invaded into the right nasal cavity, orbit and pterygopalatine fossa, ethmoid sinuses.

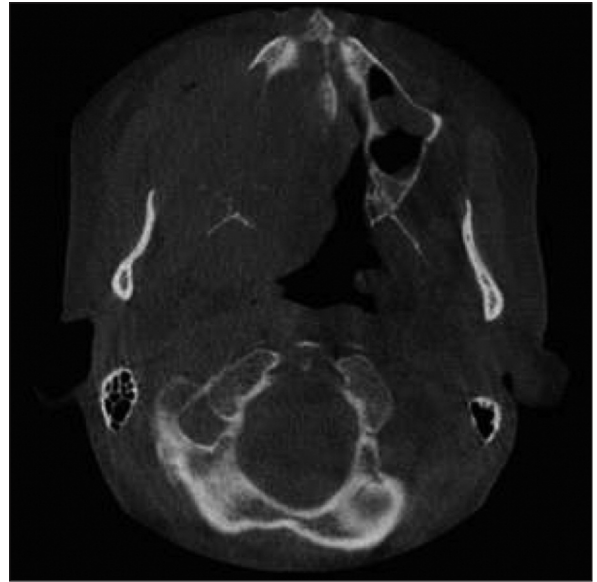


FIGURE 4: Axial section on cone beam computed tomography showing destruction of right maxilla.

neoplasms, and it generally affects the thoracopulmonary region, pelvis, abdominal region, and extremities; in rare cases, it occurs in the head and neck areas.^{1,6}

Eighteen cases of PNETs of the maxilla have been reported in the literature according to the MEDLINE/PubMed database. The clinical presentations and imaging features of these cases are presented in Table 1. Ten patients were under the age of 20 years (min 20 months, max 74 years). In general, the gender distribution of patients with PNET varies among different studies.^{1,3,6} We found that women slightly predominate, as distinct from the previously maxillary PNET cases reported by Shah et al. in 2014 (male/female ratio of 9:10) (Table 1).¹

As in our case, there was either as a soft tissue mass or swelling in the most of the reported cases of PNETs of the maxilla in Table 1. The patient was admitted to our clinic with progressively increasing, painful swelling on the right side of the face that had been ongoing for 2 months. Similar to the case presented by Shah et al., telangiectasia was evident in the soft tissue mass on the right the alveolar process and vestibular sulcus (Figure 1).⁹ Like PNETs of other body parts, head-neck PNETs have non-specific radiological findings. Meanwhile, the radiographic appearance of these tumors is not spe-

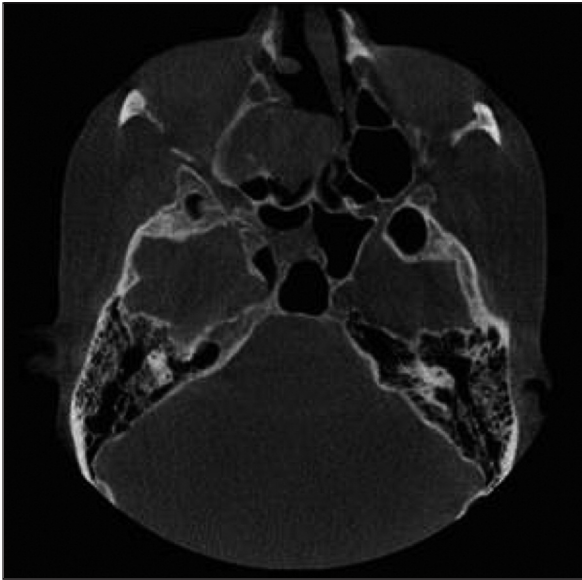


FIGURE 5: Axial section on cone beam computed tomography showing lesion medially invaded into the right nasal cavity, ethmoid sinuses.

cific for differentiation of PNETs from other types of bone and soft tissue tumors.

Clinically, differential diagnoses of intraoral PNET included epulis, pyogenic granuloma, ossifying fibroma, locally aggressive benign odontogenic tumors, minor salivary gland neoplasms, peripheral giant cell granuloma, low-grade malignant odontogenic tumors, sinonasal malignancies arising in adolescence, non-Hodgkin's lymphoma, hemangioma, and metastatic tumors. However, definitive diagnosis is based on immunohistochemical analysis and electromicroscopic features that demonstrate various degrees of neural differentiation.¹⁹

Pathologically, the differential diagnosis of PNETs includes other small round cell tumors such as malignant lymphoma, leukemia, neuroblastoma, leiomyosarcoma, rhabdomyosarcoma, undifferentiated carcinoma.¹⁵ The tumor cells of PNET show membranous immunoexpression for CD99/MIC2. Also, histological markers suggesting neuroectodermal differentiation such as NSE, synaptophysin, and vimentin may be positive, especially in PNET.²⁰ The Mic-2 gene product (CD99) for all Ewing's Sarcoma family tumors with over 95% of the cases show positivity for this marker.²¹ In our case, CD99 and NSE were identified to be positive.

Radiographic features of the malignant tumors: they show ill-defined border with lack of cortication and absence of encapsulation. Shape is generally irregular. Because the most of malignancies do not produce bone or stimulate the formation of reactive bone, internal aspect is typically radiolucent. They result in bone destruction, irregular widening of the periodontal ligament, floating teeth appearance due to bone destruction, resorption of cortical outlines, and invasion of adjacent structures. Rarely, root resorption (in sarcomas, multiple myeloma) and periosteal reaction with sunray/hair on end appearance (in osteosarcoma, prostate metastases) may occur.²²

Imaging studies are particularly useful in determining the limits of tumor involvement and metastatic evaluation. There are studies reported that both CT and MRI are very useful in preoperative staging with surgical planning and in the detection of recurrence and metastasis. MRI is more effective than CT in the delineation of soft tissue abnormalities and their relation to adjacent vascular and nervous structures. Cystic necrotic components and hemorrhagic changes are usually obvious on MRI. Therefore MRI can be considered as the imaging modality more effective than CT for pre- and post-surgical assessments of PNET.¹ However, the combination of PET or PET/CT with conventional imaging has demonstrated sensitivity and specificity > 90% in the preoperative staging of Ewing sarcoma family of tumors.²³

Cone beam computed tomography in head and neck cancer can be used as an imaging modality, especially as an alternative to CT because it needed the lesser radiation dose, the short scan time and avoids soft tissue distortions caused by gravity and showed reliable negative predictive value in application to cortical bone invasion, high resolution. Most of studies have reported that CBCT has greater sensitivity compared with the other imaging techniques such as orthopantomography (OPG), CT, MRI, and bone scintigraphy. However, CBCT has limitations such as limited soft tissue contrast, movement artifacts and a smaller detection field. The researchers concluded that the combined use of CBCT and MRI might be a promising approach.

TABLE 1: Summary of clinical and radiological findings of our case and 18 patients with maxillary PNETs in the literature.

Authors and year of study	Age	Sex	Clinical presentation Site/duration	Imaging features
Slootweg et al. 1983 ⁷	10	M	Swelling left maxilla. 3 months.	Loss of bony structures in the left anterior maxilla (CT)
Jones et al. 1995 ⁸	13	F	Maxillary and ethmoid sinuses (no other description available)	Loss of bony structures in the left anterior maxilla (CT)
Shah et al. 1995 ⁹	42	M	On extraoral examination a diffuse nontender swelling. Intraoral examination revealed a 5x2 cm2 soft tissue mass on the left alveolus and palate arising from the socket of extracted teeth 14 and 15. The swelling was lobular, relatively well defined, nontender, and soft in consistency. The overlying mucosa was ulcerated and sloughed as a result of trauma from the occluding lower teeth. Telangiectasia was evident in the left palatal and tuberosity region. 1 year.	A panoramic radiograph showed a well-defined radioopaque mass in the left posterior alveolus. Bone scan showed positive concentration in the mass on the left side in the open-mouth view.
Ibarburen et al. 1996 ¹⁰	20 month	F	Swelling left maxilla	Large soft tissue mass causing lytic destruction of the maxilla and orbit (CT)
Kao et al. 2002 ¹¹	74	M	Ulcerated fleshy mass/ right maxillary gingiva 2 months.	Lytic destruction of maxilla and soft tissue mass in parapharyngeal space (CT)
Alobid et al. 2003 ¹²	23	F	Left-sided nasal obstruction, rhinorrhea, recurrent bloody discharge. 2 months.	Large mass in the left maxillary sinus with lytic destruction and invasion of the left orbital floor and pterygomaxillary fossa (CT). Heterogeneous, hyperintense signal (T2- weighted MRI).
Sun et al. 2005 ¹³	49	F	A firm non-tender fixed mass on the right hard palate extending to the alveolar process and gingiva. 6 months.	Radiographs showed bone destruction and invasion in the molar part of the right maxilla and zygomatic buttress. The density of the maxillary sinus was increased and the medial wall had disappeared.
Mohindra et al. 2008 ¹⁴	5	M	Diffuse swelling over the right side of the face arising from the right maxillary region crossing midline, extending laterally up to the right ear lobule, superiorly up to eyebrow and inferiorly up to the lower border of the mandible. Right eye proptosis and associated periorbital edema. The overlying skin was stretched. 4 months.	A computed tomography scan of the primary site revealed a 5x5x3 cm3 sized soft tissue mass lesion arising from the right maxillary sinus invading right orbit and right pterygopalatine fossa with proptosis and deformation of right eye ball. Medially it invaded into the right nasal cavity and anterolaterally there was extension into subcutaneous tissue.
Hormozi et al. 2010 ¹⁵	28	F	Swelling left maxilla. 1 years.	CT scan showed destruction of the walls of the left maxillary sinus
Bakhshi et al. 2011 ⁶ (5 cases)	Min 4, max 14 year	2F 3M	All patients (five cases) presented with jaw swelling and pain. 2-3 months	CT scan of face showed variably enhancing mass lesion with heterogeneous attenuation in all cases. There was bone destruction in all cases with tumor extension beyond the jaw.
Yesswanth et al. 2012 ¹⁶	29	F	A fleshy pedunculated mass in the right middle meatus. 1year.	CT revealed soft tissue density lesion in the right nasal cavity, maxillary, frontal, ethmoidal and bilateral sphenoid sinuses with bony erosions of medial and posterior wall of the right maxillary sinus.
Shah et al. 2014 ¹	67	M	Granulation tissue and debris in the extracted socket area with associated gingivobuccal swelling. Three months after the surgery, the patient was readmitted with an enlarged left submandibular lymph node. 2 weeks.	Panoramic radiograph revealed generalized sclerosis of both maxillary sinuses with increased radiopacity in the left maxillary sinus. Both the panoramic and posteroanterior skull projections showed erosion of the posterolateral wall of the left maxillary sinus. MR images revealed a solid mass presumably arising from and occupying the left maxillary sinus with infiltration into the retroantral space posteriorly, and gingivobuccal sulcus inferiorly. A slightly hyperintense T2 signal and minimal enhancement were noted.
Wang et al. 2014 ¹⁷	16	M	Firm, fixed mass with a local sensation of warmth was identified in the right zygomatic facial region. 2 months.	CT of the head and neck revealed that the right maxillofacial tumor had caused cortical destruction of the wall of the right maxillary sinus and a sunburst like periosteal reaction. The solid section of the tumor was isointense to the normal muscle on the T1 weighted images and heterogeneous hyperintense on the T2 WI. On the contrast enhanced T1-WI, a marked heterogeneous enhancement with a necrotic area was identified following the intravenous administration of gadolinium.
Krithika et al. 2015 ¹⁸	23	F	Growth in gingiva in the left second and third molar teeth region with dull pricking type of pain and swelling on the left side of the face for 3 months	CT revealed a soft tissue density lesion filling the nasal cavity and paranasal sinuses, with bulging of the sinus walls on the left side. There was destruction of anterior and lateral wall of maxillary sinus and alveolar process of maxilla on the left side. Significant enhancement was seen on contrast administration, with extra-osseous extension of the soft tissue mass
Present Case	41	F	Severe pain, progressively enlarging mass on the right maxilla, and swelling in the right zygomatic facial region. On intraoral examination, a tender, fixed, lobular, relatively well-defined mass that was soft in consistency.	The panoramic projection showed erosion of medial, inferior and posterolateral walls of the right maxillary sinus and destruction on right maxilla with an appearance of teeth floating air. Cone beam computed tomography revealed cortical destruction of the walls of the right maxillary sinus and medially invaded into the right nasal cavity, orbit and pterygopalatine fossa, ethmoid

The replacement of CT by CBTC could be considered due to the easier handling, lower costs, and particularly reduced radiation exposure.⁵

PNETs often demonstrate distant metastases and local recurrence after treatment. They have often metastasized at the time of diagnosis due to rapidly progress. Distant metastases are determined in 20 to 25% of newly diagnosed patients, especially bone and bone marrow metastases. The most common sites of metastasis include the lung, bone, and bone marrow.²⁴ Because of high metastases rate, a detailed clinical and radiological evaluation is necessary of PNET. Chest radiograph, bone scintigraphy can be used to determine the metastasis. Positron Emission Tomography (PET) scan is also indicated in cases suspected bone metastases. Fluorine-18-fluorodeoxyglucose (FDG) positron emission tomography (PET) is very sensitive in the detection of recurrent bone lesions compared with other imaging modalities such as bone scintigraphy, MRI. Conversely, spiral CT seems to be superior to FDG-PET in the detection of pulmonary metastases.^{2,25}

The imaging features of these tumors are not specific for differentiation of PNETs from other types of bone and soft tissue tumors. In terms of their radiographic appearance, they resemble large, ill-defined, non-calcified soft tissue masses with cystic or necrotic areas and aggressive infiltration into adjacent tissues and bones. The most frequently involved bone in head and neck region is the mandibular ramus.^{4,15}

In the skull, these tumors present as penetrative, destructive lesions with large related to soft tissue components, reflecting their aggressive nature.²³ PNETs appeared as areas of bone destruction with invasion of surrounding walls on plain radiographs. On CT, PNETs usually appear isodense or slightly hypodense when compared with the normal muscle and as heterogeneously enhancing masses with bone destruction on CT images with intravenous contrast agents.¹⁷ On MRI scans, the majority of PNETs are isointense or slightly hyperintense on T1-weighted images and hyperintense on T2-weighted images. Furthermore, the tumor is

often heterogeneously marked following the intravenous administration of gadolinium.¹⁷ In the previously reported PNET cases of the maxilla, these tumors have had intermediate signal intensity on T1-weighted magnetic resonance imaging (MRI) and a hyperintense signal on T2-weighted images (Table 1). The observation of an ill-defined, aggressive mass and variable enhancement on CT and MR images may suggest the diagnosis of PNET. Because PNET does not show pathognomonic features, it cannot be diagnosed based on radiographic techniques alone.^{4,20}

In our case, the panoramic projection showed erosion of the medial, inferior, and posterolateral walls of the right maxillary sinus and destruction on right maxilla with an appearance of teeth floating in air and increased radiopacity in the right maxillary sinus as in the cases of Shah et al.¹ and Sun et al.¹³(Figure 2). Cone beam CT revealed cortical destruction of the walls of the right maxillary sinus and medial invasion into the right nasal cavity, orbit and pterygopalatine fossa, and ethmoid sinuses (Figures 3, 4, 5). CBCT showed cortical destruction and bone erosion in the surrounding anatomic structures similar to CT findings of cases in Table 1.

Because PNET of the maxilla is rare, its differential diagnosis is crucial. CT and MRI are useful for delineating the extent of the tumor and identifying distant metastases. In this case report, the radiological and clinical findings related to a case of PNET in the right maxilla were reported and a brief literature review of diagnosis and management of the 18 cases of PNETs of the maxilla that were previously reported is have been provided.

Conflict of Interest

Authors declared no conflict of interest or financial support.

Authorship Contributions

Esin Bozdemir and Elif Bilgir examined the patient and made literature research. Yavuz Fındık and Mustafa A. Aydın received biopsy from the patient. Esin Bozdemir wrote the article.

REFERENCES

- Shah S, Huh KH, Yi WJ, Heo MS, Lee SS, Choi SC. Primitive neuroectodermal tumor of the maxillary sinus in an elderly male: A case report and literature review. *Imaging Sci Dent* 2014;44(4):307-14.
- Ghosh A, Saha S, Pal S, Saha PV, Chattopadhyay S. Peripheral primitive neuroectodermal tumor of head-neck region: our experience. *Indian J Otolaryngol Head Neck Surg* 2009;61(3):235-9.
- Nikitakis NG, Salama AR, O'Malley BW Jr, Ord RA, Papadimitriou JC. Malignant peripheral primitive neuroectodermal tumor-peripheral neuroepithelioma of the head and neck: a clinicopathologic study of five cases and review of the literature. *Head Neck* 2003;25(6):488-98.
- Hou H, Xu Z, Xu D, Zhang H, Liu J, Zhang W. CT and MRI findings of primitive neuroectodermal tumor in the maxillofacial region. *Oral Radiology* 2016;32(1):14-21.
- Sarrión Pérez MG, Bagán JV, Jiménez Y, Margaix M, Marzal C. Utility of imaging techniques in the diagnosis of oral cancer. *J Craniomaxillofac Surg* 2015;43(9):1880-94.
- Bakhshi S, Pathania S, Mohanti BK, Thulkar S, Thakar A. Therapy and outcome of primitive neuroectodermal tumor of the jaw. *Pediatr Blood Cancer* 2011;56(3):477-81.
- Slootweg PJ, Straks W, Noorman van der Dussen MF. Primitive neuroectodermal tumour of the maxilla. Light microscopy and ultrastructural observations. *J Maxillofac Surg* 1983;11(2):54-7.
- Jones JE, McGill T. Peripheral primitive neuroectodermal tumors of the head and neck. *Arch Otolaryngol Head Neck Surg* 1995; 121(12):1392-5.
- Shah N, Roychoudhury A, Sarkar C. Primitive neuroectodermal tumor of maxilla in an adult. *Oral Surg Oral Med Oral Pathol Oral Radiol Endod* 1995;80(6):683-6.
- Ibarburen C, Haberman JJ, Zerhouni EA. Peripheral primitive neuroectodermal tumors. CT and MRI evaluation. *Eur J Radiol* 1996; 21(3):225-32.
- Kao SY, Yang J, Yang AH, Chang KW, Chang RC. Peripheral primitive neuroectodermal tumor of the maxillary gingivae with metastasis to cervical lymph nodes: report of a case. *J Oral Maxillofac Surg* 2002;60(7):821-5.
- Alobid I, Bernal-Sprekelsen M, Alós L, Benítez P, Traserra J, Mullol J. Peripheral primitive neuroectodermal tumour of the left maxillary sinus. *Acta Otolaryngol* 2003; 123(6):776-8.
- Sun G, Li Z, Li J, Wang C. Peripheral primitive neuroectodermal tumour of the maxilla. *Br J Oral Maxillofac Surg* 2007;45(3):226-7.
- Mohindra P, Zade B, Basu A, Patil N, Viswanathan S, Bakshi A, et al. Primary PNET of maxilla: an unusual presentation. *J Pediatr Hematol Oncol* 2008;30(6):474-7.
- Hormozi AK, Ghazisaidi MR, Hosseini SN. Unusual presentation of peripheral primitive neuroectodermal tumor of the maxilla. *J Craniofac Surg* 2010;21(6):1761-3.
- Yeshvanth SK, Ninan K, Bhandary SK, Lakshinarayana KP, Shetty JK, Makannavar JH. Rare case of extraskeletal Ewings sarcoma of the sinonasal tract. *J Cancer Res Ther* 2012;8(1):142-4.
- Wang C, Qiu TT, Yu XF, Xuan M, Gu QQ, Qian W, et al. Rare presentation of peripheral primitive neuroectodermal tumor in the maxilla and mandible: A report of two cases. *Oncol Lett* 2014;8(2):615-9.
- Krithika CL, Sathivasubramanian S, Vedeswari CP. Peripheral Primitive Neuroectodermal Tumour of the Maxilla and Paranasal Sinuses: A Rare Clinical Presentation. *J Clin Diagn Res* 2015;9(5):ZD32-4.
- Joshi M, Rathod RS, Shah A, Thakur R. Destructive radiolucent lesion involving right maxillary alveolus: Report of a rare case. *J Indian Acad Oral Med Radiol* 2015;27(3):449-52.
- Zhang WD, Chen YF, Li CX, Zhang L, Xu ZB, Zhang FJ. Computed tomography and magnetic resonance imaging findings of peripheral primitive neuroectodermal tumors of the head and neck. *Eur J Radiol* 2011;80(2):607-11.
- Brazão-Silva MT, Fernandes AV, Faria PR, Cardoso SV, Loyola AM. Ewing's sarcoma of the mandible in a young child. *Braz Dent J* 2010;21(1):74-9.
- Wood RE. Malignant diseases of jaws. In: White SC, Pharoah MJ, eds. *Oral Radiology: Principles and Interpretation*. 6th ed. St. Louis, MO: Mosby/Elsevier; 2009. p.405-27.
- Thorn D, Mamot C, Krasniqi F, Metternich F, Prestin S. Multimodality Treatment in Ewing's Sarcoma Family Tumors of the Maxilla and Maxillary Sinus: Review of the Literature. *Sarcoma* 2016;2016:3872768.
- Kadagad P, Umarani MV, Pinto PX. Primitive Neuroectodermal Tumor of Maxilla: A Rare Case. *World J Dentistry* 2011;2(3):281-3.
- Treglia G, Salsano M, Stefanelli A, Mattoli MV, Giordano A, Bonomo L. Diagnostic accuracy of ¹⁸F-FDG-PET and PET/CT in patients with Ewing sarcoma family tumours: a systematic review and a meta-analysis. *Skeletal Radiol* 2012;41(3):249-56.