

# Ultrasound-Guided Thrombin Injection for the Treatment of Iatrogenic Femoral Artery Pseudoaneurysms

## İatrojenik Femoral Arter Psödoanevrizmaların Tedavisinde Ultrason Eşliğinde Trombin Enjeksiyonu

Şevki Murat AKSOY,<sup>a</sup>  
İnanç Şamil SARICI,<sup>b</sup>  
Adem UÇAR,<sup>c</sup>  
Fatih YANAR,<sup>b</sup>  
Orhan AĞCAOĞLU,<sup>b</sup>  
Mehmet KURTOĞLU<sup>b</sup>

Departments of  
<sup>a</sup>General Surgery,  
<sup>c</sup>Radiology,  
Bahçeşehir University Faculty of Medicine,  
<sup>b</sup>Department of General Surgery,  
İstanbul University  
İstanbul Faculty of Medicine, İstanbul

Geliş Tarihi/Received: 10.12.2013  
Kabul Tarihi/Accepted: 07.03.2014

Yazışma Adresi/Correspondence:  
İnanç Şamil SARICI  
İstanbul University  
İstanbul Faculty of Medicine,  
Department of General Surgery, İstanbul,  
TÜRKİYE/TURKEY  
isamilsarici@hotmail.com

**ABSTRACT Objective:** The aim of this study is to review our experience with percutaneous ultrasonography (USG) guided thrombin injection to treat iatrogenic femoral artery pseudoaneurysms and to assess the safety of the procedure. **Material and Methods:** From January 2007 to January 2011, 41 patients with iatrogenic femoral pseudoaneurysms, were included in the study. The medical records concerned the demographics, the pseudoaneurysm size and site, thrombin dose that was injected, efficacy and safety of the procedure and postinterventional follow-up for one year. **Results:** There were 39 (95.1%) patients, who were eligible to be included in the study. Twenty-four (61.5%) patients were male and 15 (38.5%) patients were female. The mean age was 72±11 years (49–88). All of the pseudoaneurysms were originated from the common femoral arteries. The mean maximum transverse diameter of the pseudoaneurysms was 3.7±1.1 cm (2 - 6.5 cm). The mean neck diameter was 5±1.1 mm (3-7.5 mm). After the first thrombin injection, complete thrombosis of the pseudoaneurysm occurred in 34 (87.1%) of the patients. A secondary thrombin injection was required in 5 (12.8%) patients. USG-guided thrombin injection failed in 2 (5.3%) patients. There was not any complications during the follow-up. **Conclusion:** USG-guided thrombin injection is an effective technique for the treatment of post-catheterisation pseudoaneurysms, which is easy to perform; safe, well tolerated and highly successful in good selected patients.

**Key Words:** Aneurysm, false; ultrasonography

**ÖZET Amaç:** Bu çalışmanın amacı iatrojenik femoral arter psödoanevrizmalarında ultrason eşliğinde perkütan trombin enjeksiyonu deneyimlerimizi gözden geçirmek, tedavi ve prosedürün güvenilirliğini değerlendirmektir. **Gereç ve Yöntemler:** Ocak 2007-2011 tarihleri arasında iatrojenik femoral psödoanevrizma tanısı konulan 41 hasta çalışmaya alındı. Demografik bulgular, psödoanevrizmanın yer ve boyutu, enjektöre edilen trombin dozu, prosedürün etkinliği ve güvenilirliği, işlem sonrası bir yıllık izlem kayıtlarda incelendi. **Bulgular:** Çalışmaya uygun olan 39 (%95,1) hasta dâhil edildi. Hastaların 24 (%61,5)'ü erkek ve 15 (%38,5)'i kadın idi. Yaş ortalaması 72±11 yıl (49-88) idi. Psödoanevrizmaların tümü ortak femoral arter kaynaklı idi. Psödoanevrizmaların ortalama maksimum transvers çapı 3,7±1,1 cm (2-6,5 cm) idi. Ortalama boyun çapı 5±1,1 mm (3-7,5 mm) idi. İlk trombin enjeksiyonundan sonra, psödoanevrizmalı hastaların 34 (% 87,1)'ünde tam tromboz görüldü. Beş (%12,8) hastada ikinci trombin enjeksiyonu gerekli oldu. Ultrason eşliğinde trombin enjeksiyonu 2 (%5,3) hastada başarısız oldu. İzlem sırasında herhangi bir komplikasyon görülmedi. **Sonuç:** USG eşliğinde trombin enjeksiyonu kateterizasyon sonrası gelişen psödoanevrizmaların tedavisinde güvenli, iyi tolere edilen ve iyi seçilmiş hastalarda son derece başarılı, gerçekleştirilmesi kolay etkili bir yöntemdir.

**Anahtar Kelimeler:** Anevrizma, yalancı; ultrasonografi

Türkiye Klinikleri J Cardiovasc Sci 2014;26(1):11-5

The incidence of iatrogenic femoral artery pseudoaneurysms (IFPx) has increased recently and the incidence ranges from 0.8 to 2.2%.<sup>1</sup> The increase in rate may be related to extensive use of diagnostic angiography or percutaneous interventions and frequent use of concomitant

anticoagulation and antiplatelet therapy in this cohort of patients.<sup>2</sup>

Traditionally, surgery has been considered the “gold standard” treatment in femoral Px. However, the development of less invasive therapeutic approaches such as ultrasound (USG) guided compression or USG-guided thrombin injection (UGTI) has led to lesser use of surgery in these conditions.<sup>3-5</sup> Nevertheless, despite high rates of success, USG-guided compression may be associated with disadvantages such inability to treat noncompressible pseudoaneurysms; possible technical failure in patients, who are on anticoagulants; patient discomfort during compression, and long procedure times ranging between 30 and 100 min, as well as work overload in certain departments.<sup>6-9</sup>

The use UGTI has allowed the repair of IFPx with success rates, ranging from 93% to 100%.<sup>10-12</sup> Although complications are rarely seen with this technique, such as distal embolization or allergic reactions; they are reported.<sup>13-17</sup> The aim of this study is to review our experience with percutaneous UGTI to treat IFAPs and to assess the safety of the procedure.

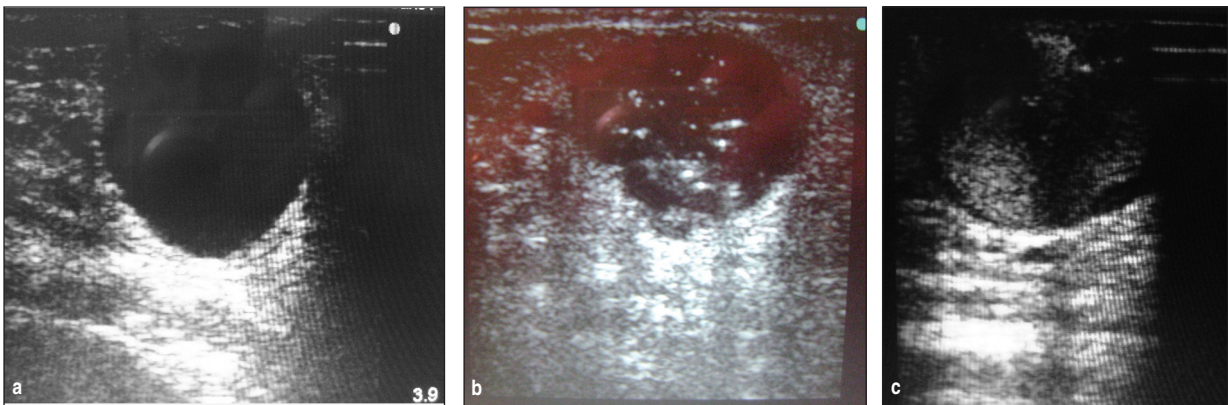
## MATERIAL AND METHODS

From January 2007 to January 2011, all consecutive patients, who were admitted to Peripheral Vascular Surgery Unit, Department of Surgery, Istanbul Medical Faculty, Istanbul University with iatro-

genic femoral pseudoaneurysms, were included in the study. The medical records of the patients were analyzed retrospectively. The medical records concerned the demographics, the pseudoaneurysm size and site, thrombin dose that was injected, efficacy and safety of the procedure and postinterventional follow-up. Technical success was defined as complete thrombosis of the IFPx. Safety was defined as freedom from complications.

The diagnosis was made with physical examination and duplex ultrasound findings or computed tomography angiography. USG-guided thrombin injection was performed, if the largest diameter of the pseudoaneurysm was more than 2 cm. Contraindications to the technique included pseudoaneurysms, which were complicated with skin necrosis, arteriovenous (AV) fistula, local infection, and history of allergic reaction to thrombin and pseudoaneurysms with wide necks, which are more than 8 mm in diameter. Patients with pseudoaneurysms resulting from previous vascular surgery or trauma were excluded from the study.

The intervention was performed by one experienced operator or one radiologist. Before the injection of thrombin, each pseudoaneurysm was visualized in a transverse as well as in a longitudinal view (Figure 1a). After preparation of human thrombin (500 IU/mL) (Tisseel Kit, Baxter Healthcare, Norfolk, UK) and saline solution, the skin was prepared with a local disinfectant. With direct ul-



**FIGURE 1: a-c.** Grey-scale sonogram image obtained in sagittal (longitudinal) direction in patient with simple pseudoaneurysm originating from femoral artery (a), Partial thrombosis of the pseudoaneurysm after injection of 250 IU of thrombin (b), Complete thrombosis of the pseudoaneurysm after a total injection of 500 IU of thrombin (c).

trasound guidance in a transverse view, the needle was positioned in the centre of the Px. An initial bolus of 250 IUs of thrombin was slowly injected without aspirating any blood (Figure 1b). In the case of residual flow in the Px, an additional 250 IUs (or more) were injected using the same technique (Figure 1c). Following the intervention, the Px was probed to ensure the absence of colorful blood-flow signals between pseudoaneurysm and femoral artery. Treated patients remained in bed for 4 hours. Distal pulses were checked before and after the procedure. The patients were discharged on the day of intervention, if they were not hospitalized for any other reasons. They were put on acetyl-salicylic-acid (ASA) or routine antiplatelet or anticoagulation therapy.

All patients had out-patient clinic follow-up at four weeks. The follow-up visits included physical examination and duplex ultrasound at the 3<sup>rd</sup>, 6<sup>th</sup> and 12 months. In case of remnant flow in the Px, it was regarded as a technical failure, and the patients was scheduled to a subsequent thrombin injection.

## RESULTS

There were 41 patients, who were admitted to the hospital with IFPxs. Two (4.8%) patients had an accompanying AV fistula, and they were not scheduled for an UGTI and excluded from the study. There were 39 (95.1%) patients, who were eligible to be included in the study. Of 39 patients treated, 24 (61.5%) patients were male and 15 (38.5%) patients were female. The mean age was  $72 \pm 11$  years (49-88). Comorbid diseases included congestive heart failure and severe ischemic heart disease in 22 (56.4%) patients, renal failure in 11 (28.2%) patients, diabetes mellitus in 18 (46.1%) and chronic obstructive pulmonary disease in 6 (15.3%) patients. There were 31 (79.5%) patients, who were already on either antiplatelet therapy with aspirin or clopidogrel or both, or anticoagulation during the index procedure. All patients displayed clinical symptoms of a groin complication. Twenty five (64.1%) patients presented with pain, 12 (30.7%) patients presented with swelling and pain and 2 patients (5.1%) presented with severe bruising of the groin.

The diagnosis of femoral pseudoaneurysms was made by duplex ultrasound in all cases. The mean duration of the application of patients was  $18 \pm 7$  hours (6-32 hours). Iatrogenic femoral artery pseudoaneurysms developed following percutaneous coronary interventions and diagnostic angiography in 36 (92.3%) and 3 (7.7%) patients, respectively. All of the pseudoaneurysms were originated from the common femoral arteries. The mean maximum transverse diameter of the pseudoaneurysms was  $3.7 \pm 1.1$  cm (2-6.5 cm). The mean neck diameter was  $5 \pm 1.1$  mm (3-7.5 mm).

After the first thrombin injection, complete thrombosis of the pseudoaneurysm occurred in 34 (87.1%) of the patients. A secondary thrombin injection was required in 5 (12.8%) patients. UGTI failed in 2 (5.3%) patients. These two patients underwent a surgical procedure. The mean thrombin dose was  $450 \pm 150$  units (250-1000 units).

UGTI-related complications such as significant arterial thrombotic events or allergic reactions and infections did not occur.

The postinterventional treatment included antiplatelet therapy in 22 (56.4%) patients, dual antiplatelet therapy in 9 (23%) patients, anticoagulation and antiplatelet therapy in 5 (12.8%) patients and anticoagulation alone in 3 (7.8%) patients. The mean follow-up period was  $9 \pm 2.5$  month (6-24 months). During the follow-up, there was not any recurrence, which was detected with physical examination or duplex ultrasound.

## DISCUSSION

There has been a remarkable advance in endovascular techniques during the last few decades and the rate of endovascular interventions has dramatically increased. Common femoral artery is the most common site of arterial access for a wide range of both diagnostic and interventional procedures.<sup>18</sup> Therefore, the incidence of iatrogenic Px of common femoral artery (CFA) has increased considerably. This retrospective study focused on the results of UGTI in iatrogenic femoral pseudoaneurysms and it has shown that UGTI is a safe and efficient method in the treatment of iatrogenic femoral Px.

Conventionally, iatrogenic femoral pseudoaneurysms were treated by surgery. However, surgery may be associated with groin complications, bleeding, lymphocele, radiculopathy as well as perioperative myocardial infarction and death.<sup>19</sup> Moreover, a subsequent surgical intervention is risky in this cohort of patients, who have accompanying diseases such as ischemic heart disease, nephropathy, stroke etc. Therefore, less invasive techniques such as ultrasound guided compression have been popularized in the treatment. This technique included compression of the neck of the Px under ultrasound guidance until the flow in the Px is ceased and the pseudoaneurysm is thrombosed. The occlusion rate ranged from 71% to 99%.<sup>6-8</sup> Nevertheless, this technique has disadvantages such as discomfort of the patient during the compression therapy and the time required for this technique may be a burden on the radiology department. We have adopted the technique of UGTI recently because of the disadvantages of the ultrasound guided compression therapy (UGCT), which have been mentioned previously.

USG-guided thrombin injection was introduced in 1986 by Cope and Zeit.<sup>20</sup> It is currently the method of choice in treating femoral pseudoaneurysms in many centers. The overall success rate is between 96% and 98%.<sup>21,22</sup> The technique may be applied in majority of the patients. Nevertheless, a small percentage of patients are not a good candidate for the procedure. Patients, who are diagnosed with a wide-necked aneurysm and/or accompanying AV fistula will not be able to benefit from this intervention because a poor outcome is expected, when the diameter of the neck is >8.0 mm and pulmonary emboli may ensue in case of an AV fistula.<sup>8</sup> Nevertheless, most of the patients, who present with Px are candidates for UGTI. In our series, 95% of the patients were scheduled for UGTI. There were only two patients, who were not found to be eligible and the reason for the drawback was the presence of an AV fistula in both patients. We consider surgical repair as first-line treatment in these patients with AV fistula.

In our serial the primary technical success rate was 87.1%. There were 5 patients, who did not

benefit from the treatment. Nevertheless, the secondary thrombin injection was successful in 3 of the patients. Although the primary success rate in our serial does not seem satisfactory, we have achieved a secondary success rate of 94.7%. There were 2 patients, who had to undergo a surgical repair for the Pxs. One of them was a sixteen year girl and she had a bleeding disorder of hemophilia A. We believe that the main reason of the failure was this accompanying disease. The other patient developed pseudoaneurysm 1 day after UGTI because of phenprocoumon therapy associated with local compression symptoms and haemodynamic instability. Moreover, failures at first attempt were seen in the first half of the patients. This finding may be attributed to learning curve of the technique. Even so, it took a short while to adopt the technique. It has also been previously stated that the learning curve for this technique is short.<sup>16</sup>

Schneider et al. primarily successfully treated in 267 of 274 patients (97%) with UGTI.<sup>23</sup> In their serial 3 of 7 patients with a remaining pseudoaneurysm a second injection was required and three patients were treated by ultrasound-guided compression because of the small size of the remaining pseudoaneurysm (<1 cm diameter). Only one patient was treated by surgical repair of the pseudoaneurysm because a further pseudoaneurysm developed under phenprocoumon therapy. Vlachou et al. performed total of 85 patients UGTI and they were successful in 81(95%) pseudoaneurysms.<sup>24</sup> Seventy-nine pseudoaneurysms thrombosed immediately after one injection, whereas two patients required a second session of thrombin injection in their study. No patient underwent ultrasound-guided compression in their study. Ultrasound-guided thrombin injection was unsuccessful in 4 patient because of pseudoaneurysm measuring  $\geq 6$  cm in maximum diameter and this patients were treated surgically.

There are various suggestions concerning the technique to perform the thrombin injection in the literature.<sup>4</sup> According to Krüger et al. it is not necessary to inject larger thrombin doses with the exception of pseudoaneurysms with larger cavities.<sup>4</sup> The authors recommend injecting into the deepest



cavity, hence all cavities and the neck thrombose directly, so the required thrombin dose can be reduced.<sup>23</sup> We prefer to inject thrombin in the center of the cavity and we try to inject slowly. The maneuver of withdrawing the syringe to ensure that the needle is in the cavity should be avoided because it will end with thrombosis of the lumen of the needle and the syringe. And this will block the needle and prevent the procedure.

Although the complications rates are usually low in previously published series, there are few papers, which report unwanted and fatal complications.<sup>21,22</sup> Allergic reaction is a possibility but, the use of human thrombin for injection therapy should be superior to bovine thrombin regarding the risk of allergic reactions theoretically. The bovine form should not be used with a history of previous exposure due to the risk of IgE mediated-anaphylaxis following repeated exposure.<sup>24</sup> We used human

thrombin all of the cases. We have not encountered any complication during or after the intervention.

There are some limitations of this study. This study was a retrospective study with its inherent limitations. There was no control group in which the UGTI technique was not used to document whether this technique is superior to other techniques with respect to successful results or complications. Also, as noted, the number of patients with disease was quite small. The blood pressure, body mass index, and the sheath size that was used for the catheterization were not measured. These factors could be important for the success and failure of the procedure.

## CONCLUSION

UGTI is a technique for the treatment of post-catheterisation pseudoaneurysms, which is easy to perform; safe, well tolerated and highly successful in good select patients.

## REFERENCES

- Katzenschlager R, Ugurluoğlu A, Ahmadi A, Hülsmann M, Koppensteiner R, Larch E, et al. Incidence of pseudoaneurysm after diagnostic and therapeutic angiography. *Radiology* 1995;195(2):463-6.
- Webber GW, Jang J, Gustavson S, Olin JW. Contemporary management of postcatheterization pseudoaneurysms. *Circulation* 2007;115(20):2666-74.
- Coley BD, Roberts AC, Fellmeth BD, Valji K, Bookstein JJ, Hye RJ. Postangiographic femoral artery pseudoaneurysms: further experience with US-guided compression repair. *Radiology* 1995;194(2):307-11.
- Krueger K, Zaehlinger M, Strohe D, Stuetzer H, Boecker J, Lackner K. Postcatheterization pseudoaneurysm: results of US-guided percutaneous thrombin injection in 240 patients. *Radiology* 2005;236(3):1104-10.
- Kobeiter H, Lapeyre M, Becquemin JP, Mathieu D, Meliere D, Desgranges P. Percutaneous coil embolization of postcatheterization arterial femoral pseudoaneurysms. *J Vasc Surg* 2002;36(1):127-31.
- Fellmeth BD, Roberts AC, Bookstein JJ, Freischlag JA, Forsythe JR, Buckner NK, et al. Postangiographic femoral artery injuries: nonsurgical repair with US-guided compression. *Radiology* 1991;178(3):671-5.
- Cox GS, Young JR, Gray BR, Grubb MW, Hertzler NR. Ultrasound-guided compression repair of postcatheterization pseudoaneurysms: results of treatment in one hundred cases. *J Vasc Surg* 1994;19(4):683-6.
- Paschalidis M, Theiss W, Kölling K, Busch R, Schömig A. Randomised comparison of manual compression repair versus ultrasound guided compression repair of postcatheterisation femoral pseudoaneurysms. *Heart* 2006;92(2):251-2.
- Kang SS, Labropoulos N, Mansour MA, Baker WH. Percutaneous ultrasound guided thrombin injection: a new method for treating postcatheterization femoral pseudoaneurysms. *J Vasc Surg* 1998;27(6):1032-8.
- Taylor BS, Rhee RY, Muluk S, Trachtenberg J, Walters D, Steed DL, et al. Thrombin injection versus compression of femoral artery pseudoaneurysms. *J Vasc Surg* 1999;30(6):1052-9.
- Ferguson JD, Whattling PJ, Martin V, Walton J, Banning AP. Ultrasound guided percutaneous thrombin injection of iatrogenic femoral artery pseudoaneurysms after coronary angiography and intervention. *Heart* 2001;85(4):E5.
- Brophy DP, Sheiman RG, Amatulle P, Akbari CM. Iatrogenic femoral pseudoaneurysms: thrombin injection after failed US-guided compression. *Radiology* 2000;214(1):278-82.
- D'Ayala M, Smith R, Zarieski G, Fahoum B, Tortoliani AJ. Acute arterial occlusion after ultrasound-guided thrombin injection of a common femoral artery pseudoaneurysm with a wide, short neck. *Ann Vasc Surg* 2008;22(3):473-5.
- Sheldon PJ, Oglevie SB, Kaplan LA. Prolonged generalized urticarial reaction after percutaneous thrombin injection for treatment of a femoral artery pseudoaneurysm. *J Vasc Interv Radiol* 2000;11(6):759-61.
- O'Sullivan GJ, Ray SA, Lewis JS, Lopez AJ, Powell BW, Moss AH, et al. A review of alternative approaches in the management of iatrogenic femoral pseudoaneurysms. *Ann R Coll Surg Engl* 1999;81(4):226-34.
- Hanson JM, Atri M, Power N. Ultrasound-guided thrombin injection of iatrogenic groin pseudoaneurysm: Doppler features and technical tips. *Br J Radiol* 2008;81(962):154-63.
- Morgan R, Belli AM. Current treatment methods for postcatheterization pseudoaneurysms. *J Vasc Interv Radiol* 2003;14(6):697-710.
- Görge G, Kunz T, Kirstein M. A prospective study on ultrasound-guided compression therapy or thrombin injection for treatment of iatrogenic false aneurysms in patients receiving full-dose anti-platelet therapy. *Z Kardiol* 2003;92(7):564-70.
- Kresowik TF, Khoury MD, Miller BV, Winniford MD, Shamma AR, Sharp WJ, et al. A prospective study of the incidence and natural history of femoral vascular complications after percutaneous transluminal coronary angioplasty. *J Vasc Surg* 1991;13(2):328-33; discussion 333-5.
- Cope C, Zeit R. Coagulation of aneurysms by direct percutaneous thrombin injection. *AJR Am J Roentgenol* 1986;147(2):383-7.
- Ahmad F, Turner SA, Torrie P, Gibson M. Iatrogenic femoral artery pseudoaneurysms--a review of current methods of diagnosis and treatment. *Clin Radiol* 2008;63(12):1310-6.
- Yao Q, Cong H, Wu S, Sun S, Dong Q, Chen D, et al. Ultrasound-guided thrombin injection: an alternative treatment for femoral artery pseudoaneurysm with better efficiency and safety. *J Huazhong Univ Sci Technol Med Sci* 2008;28(3):373-4.
- Schneider C, Malisius R, Küchler R, Lampe F, Krause K, Bahlmann E, et al. A prospective study on ultrasound-guided percutaneous thrombin injection for treatment of iatrogenic post-catheterisation femoral pseudoaneurysms. *Int J Cardiol* 2009;131(3):356-61.
- Vlachou PA, Karkos CD, Bains S, McCarthy MJ, Fishwick G, Bolia A. Percutaneous ultrasound-guided thrombin injection for the treatment of iatrogenic femoral artery pseudoaneurysms. *Eur J Radiol* 2011;77(1): 172-4.