

Evaluation of Pharyngeal Airway Space After Mandibular Setback Operations¹

ALT ÇENE GERİ KONUMLANDIRMA OPERASYONLARI SONRASINDA FARİNGEAL HAVA YOLU BOŞLUĞUNUN İNCELENMESİ

Orhan GÜVEN*, Umut SARAÇOĞLU**, Çağrı DELİLBAŞI **

* Professor, Ankara University Faculty of Dentistry, Department of Oral and Maxillofacial Surgery

** Research Assistant, Ankara University Faculty of Dentistry, Department of Oral and Maxillofacial Surgery, Ankara, TURKEY

Summary

Purpose: Changes in the positions of tongue and the hyoid bone due to mandibular setback operations can cause narrowing of the pharyngeal airway space and development of obstructive sleep apnea syndrome (OSAS). The purpose of this study was to investigate the changes in pharyngeal airway space (PAS) and development of obstructive sleep apnea syndrome in patients undergoing mandibular setback operations with either sagittal split ramus osteotomy (SSRO) or body osteotomy (BO) technique.

Patients and Methods: Changes in the posterior airway space were evaluated using lateral cephalometric radiographs of 15 patients. 7 patients were operated using SSRO and 8 were operated using BO technique. Radiographs were taken within 2 weeks preoperatively and 6 to 12 months postoperatively. All the patients were assessed for the development of OSAS during the follow-up.

Results: A significant reduction in pharyngeal airway space area was found after mandibular setback operations ($p<0.05$). There was a significant reduction in the length of the mandible after the operations ($p<0.05$). There was no positive correlation between the amount of setback and the change in pharyngeal airway space area ($p>0.05$). None of our patients developed any signs or symptoms of postoperative obstructive sleep apnea syndrome.

Conclusion: The results of this study indicate that narrowing of pharyngeal airway space is likely to occur after mandibular setback operations regardless of the amount of setback; however, this may not be indicative for the development of obstructive sleep apnea syndrome.

Key Words: Mandibular setback,
Obstructive sleep apnea syndrome,
Orthognathic surgery,
Posterior airway space

T Klin J Dental Sci 2002, 8:144-148

Özet

Amaç: Alt çene geri konumlandırma operasyonlarına bağlı olarak dil ve hyoid kemiğin pozisyonlarının değişmesi, faringeal hava yolu boşluğunun daralmasına ve obstrüktif uyku apne sendromunun (OUAS) gelişmesine neden olabilir. Bu çalışmanın amacı, sagittal split ramus osteotomi (SSRO) veya body osteotomi (BO) tekniği kullanılarak alt çene geri konumlandırma operasyonu uygulanan hastalarda faringeal hava yolu boşluğundaki değişikliğin ve obstrüktif uyku apne sendromu gelişmesinin araştırılmasıdır.

Hastalar ve Metod: Alt çene geri konumlandırma operasyonu uygulanan 15 hastanın lateral sefalometrik radyografileri incelendi. 7 hasta SSRO tekniği ile, 8 hasta BO tekniği ile opere edildi. Radyografiler operasyondan 2 hafta önce ve operasyondan 6 ila 12 ay sonra çekildi. Ayrıca tüm hastalar takip döneminde OUAS gelişmesi açısından değerlendirildi.

Bulgular: Alt çene geri konumlandırma operasyonları sonrası faringeal hava yolu boşluğunda anlamlı bir daralma tespit edildi ($p<0.05$). Operasyon sonrasında mandibulanın uzunluğunda anlamlı bir azalma bulundu ($p<0.05$). Geri konumlandırma miktarı ile faringeal hava yolu boşluğundaki değişim arasında bir ilişki saptanmadı ($p>0.05$). Hiçbir hastada operasyon sonrasında OUAS geliştiğine dair bir bulguya rastlanmadı.

Sonuç: Alt çene geri konumlandırma operasyonları sonrasında, geri konumlandırma miktarına bağlı olmaksızın faringeal hava yolu boşluğunda bir daralma meydana gelebileceği; ancak bunun OUAS gelişmesi açısından belirleyici olmadığı sonucuna varıldı.

Anahtar Kelimeler: Alt çene geri konumlandırma,
Obstrüktif uyku apne sendromu,
Ortognatik cerrahi,
Arka hava yolu boşluğu

T Klin Diş Hek Bil 2002, 8:144-148

Obstructive sleep apnea syndrome (OSAS), has received increased recognition in several fields because of multisystem complications associated with the clinical condition and the high prevalence

of the syndrome in adult population. Orthognathic surgical procedures are designed to correct congenital or acquired dentofacial deformities; achieve cosmetic improvement of the face and

dentition and to normalize stomatognathic function (1). Orthognathic surgical procedures inevitably affect the size and position of the surrounding soft tissues by changing the pre-existing soft tissue-hard tissue relationship. It has been stated that following mandibular setback operations, the hyoid bone and therefore the root of the tongue move downward and backward. When the tongue is carried backward and downward, a restriction in the hypopharyngeal airway space may take place. This narrowing can cause OSAS, which may be seen in obese patients, adenotonsillar hypertrophy, macroglossia, large uvula and significant retrognathic (2,3). A number of studies of OSAS patients have shown diminished cross-sectional area of the pharynx that may lead to pharyngeal collapse. Body osteotomy (BO) was a popular technique in the past for the treatment of mandibular prognathism or open bite cases, but sagittal split ramus osteotomy (SSRO) has been commonly used instead of BO in recent years.

The purpose of this study was to evaluate the posterior airway space (PAS) after the two different mandibular setback techniques and to assess the relationship between these operations and the development of OSAS.

Patients and Methods

The data were obtained from presurgical and postsurgical lateral cephalometric radiographs of 15 orthognathic surgery patients who initially had mandibular prognathism. The study group consisted of 10 male and 5 female patients, age ranging from 18 to 26 years with a mean of 20.7. 7 patients were operated using SSRO and 8 patients were operated using BO technique. All of them received presurgical and postsurgical orthodontic treatment in order to create a stable postoperative occlusion. Patients with maxillary hypoplasia and facial asymmetry were not included. Radiographs were taken in natural head position with teeth in occlusion and lips in repose, within 2 weeks prior to the surgery and 6 months to 12 months after surgery. All of the operations were performed by the same surgeon. Titanium miniplates were used for osteosynthesis and no maxillomandibular fixa-

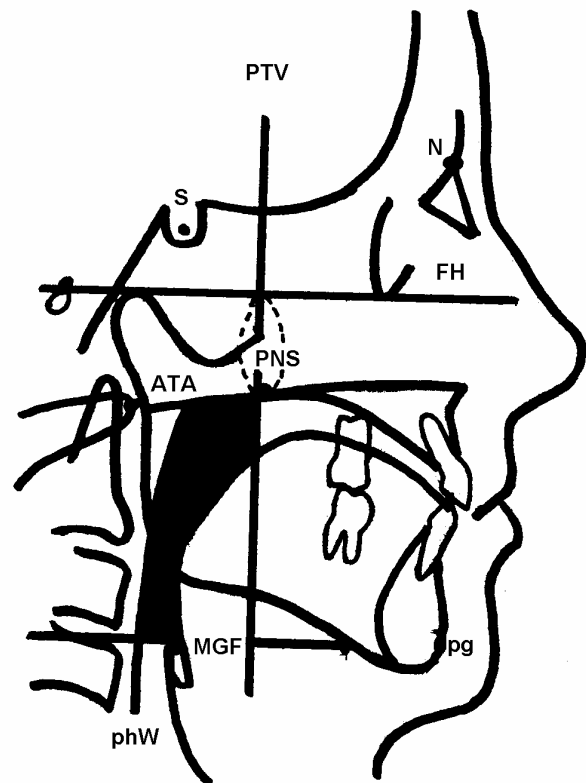


Figure 1. Cephalometric landmarks used for evaluation of the posterior airway space (shaded area) and the amount of mandibular setback.

tion was used postoperatively. The following cephalometric landmarks were used for analysis.

A line drawn across the median glossoepiglottic fold (MGF) parallel to Frankfurt Horizontal Plane (FH) defined the inferior border of the PAS. A line connecting the posterior nasal spine (PNS) and anterior tubercle of the atlas (ATA) defined the superior border. The posterior border of the PAS was defined as the posterior pharyngeal wall (PhW) and the anterior border was defined as the posterior tongue outline and the Pterygoid Vertical Plane (PTV). The amount of mandibular setback was measured in millimeters as a change in value of the line connecting the pogonion (Pg) and the PTV drawn parallel to FH (Figure 1). All landmarks were determined and measured by the same investigator. Superimpositions of radiographs were made on a sella-nasion line with best fit of the anterior and posterior cranial landmarks. Templates of the mandible, made from the

Table 1. Preoperative and follow-up cephalometric findings of the patients.

Surgical technique	Case no	Gender	Age (yrs)	PAS area (cm ²)		Po-PTV (mm)	
				Preop	Postop	Preop	Postop
SSRO	1	M	20	10.51	9.38	64.0	59.0
	2	F	23	7.73	6.35	43.0	41.5
	3	M	26	7.42	10.92	80.0	65.0
	4	M	21	13.19	11.75	47.0	38.5
	5	M	20	13.29	10.72	75.0	68.0
	6	M	20	13.71	11.95	61.0	56.5
	7	M	21	14.57	9.03	78.0	65.0
BO	8	M	21	10.75	8.69	51.5	42.0
	9	M	20	8.28	11.34	74.0	45.5
	10	F	23	8.48	7.21	62.0	54.0
	11	F	18	12.68	10.10	52.0	47.0
	12	M	20	11.30	10.20	79.0	56.5
	13	F	19	7.66	7.59	43.0	42.0
	14	F	18	7.21	5.39	64.0	42.0
	15	M	21	9.51	7.66	48.5	50.5

presurgical radiographs were superimposed along the mandibular symphysis and utilized to transfer relevant landmarks to the postsurgical radiographs. The measurement of PAS area was done twice by using planometer and mean value was used. The patients were examined for the development of OSAS during the follow-up. None of the patients had subjective complaints preoperatively that would be consistent with OSAS.

Changes in posterior airway space after the operations and the amount of setback were analyzed by paired t-tests. Pearson's coefficient of correlation was used to evaluate the dependence of the change of posterior airway space and the amount of mandibular setback. P values <0.05 were considered significant.

Results

Data of the patients, preoperative values and follow-up changes in the cephalometric parameters were shown in Table 1. The mean decrease in postoperative PAS area was 1.20 cm² that corresponds to nearly 11.6% reduction. When preoperative PAS area (10.41±2.58) and postoperative PAS area (9.21±2.02) were compared, significant reduction was found (p=0.05). There was a significant reduction in the length of the mandible when pre-

operative Po-PTV (61.46±13.43) and postoperative Po-PTV(51.53±9.8) values were compared (p=0.0001). The mean amount of mandibular setback was 10.1 mm, which corresponded to an 16.5% decrease in the length of the mandible from preoperative values. The amount of mandibular setback did not have a strongly positive correlation with the PAS area change (p=0.189). None of our patients had clinical symptoms and complaints indicating airway obstruction (snoring, observed apnea during sleep, daytime sleepiness) after the operation. Statistical values were given as mean±standard deviation.

Discussion

Surgery for the correction of mandibular prognathism produces changes in the skeletal and soft tissue components of the orofacial complex. Alterations have been shown in position of the tongue and the hyoid bone, consequently narrowing of the PAS may occur (4). The narrowing of hypopharyngeal airway space is due to posterior and inferior movement of the tongue. Although the lower tongue point begins to return to its preoperative position, the upper tongue point seems to adapt to the positional changes of the mandible after the setback operations (2).

Mandibular advancement operation has been successfully used to increase airway in patients with OSAS (5,6). Turnbull and Battagel (7) found a significant decrease in the retrolingual airway dimension in all patients after mandibular setback surgery and a significant increase in this dimension after mandibular advancement. Mehra et al. (5) reported that double-jaw surgery with counter-clockwise rotation of the maxillomandibular complex significantly affected the pharyngeal airway space and velopharyngeal anatomy in patients with high occlusal plane facial morphology, with both mandibular advancement and setback. A number of studies in OSAS patients have shown a diminished cross-sectional area of the pharynx that may lead to pharyngeal collapse. However, it is known that patients rarely develop airway maintenance difficulties associated with setback procedures. So far a few cases of OSAS due to setback procedures have been reported (8). This should be taken into consideration by clinicians; thus, careful monitoring and long-term follow-up of the patients are essential. Turnbull and Battagel (7) evaluated sleep disturbance after orthognathic surgery procedures. They reported no significant change in snoring incidence or apnoeic events after mandibular setback surgery; however, for the mandibular advancement group, improvement in sleep quality was detected but only in cases with signs of a pre-existing sleep disorder. Our result also supports that OSAS is not associated with mandibular setback operations.

The methods for evaluating PAS include cephalometric radiographs, CT, 3D-CT and MRI. Although the diagnostic value of CT and MRI is superior to 2 dimensional radiographs (9,10), they are impractical for routine clinical application (1, 11).

The correlation between the amount of setback and PAS narrowing is controversial. Tselnik et al. (3) and Kawamata et al. (10) reported nearly the same percentage of change in both parameters whereas Enacar et al. (2) and Hochban et al. (12) did not find any relation. The result of our study is consistent with the latter. If there is a positive correlation, one can predict the approximate postop-

erative reduction in PAS area after operation. So the surgeon should be aware of the potential for the development of postoperative OSAS in patients undergoing mandibular setback.

The results of this study suggest that narrowing of the PAS is likely to occur after mandibular setback operations regardless of the amount of setback. This should be taken into consideration if predisposing factors exist; such as preoperative OSAS patients who have already decreased PAS dimension, presence of specific craniofacial type and/or obesity or insufficiency of individual neuromuscular adaptation to compensate for the reduction in airway size. We did not compare the two techniques, because the number of patients in each group is small. We believe the necessity of further studies with large patient groups to investigate the effects of different orthognathic surgery procedures on posterior airway space change and obstructive sleep apnea syndrome.

REFERENCES

1. Achilleos S, Krogstad O, Lyberg T: Surgical mandibular setback and changes in uvuloglossopharyngeal morphology and head posture: a short and long term cephalometric study in males. *Eur J Orthod* 22: 383, 2000
2. Enacar A, Aksoy AU, Sencift Y, Haydar B, Aras K: Changes in hypopharyngeal airway space and in tongue and hyoid bone positions following the surgical correction of mandibular prognathism. *Int J Adult Orthod Orthognath Surg* 9: 285, 1994
3. Tselnik M, Pogrel MA: Assessment of the pharyngeal airway space after mandibular setback surgery. *J Oral Maxillofac Surg* 58: 282, 2000
4. Gu G, Gu G, Nagata J, Suto M, Anraku Y, Nakamura K, Kuroe K, Ito G: Hyoid position, pharyngeal airway and head posture in relation to relapse after the mandibular setback in skeletal Class III. *Clin Orthod Res* 3: 67, 2000
5. Mehra P, Downie M, Pita MC, Wolford LM: Pharyngeal airway space changes after clockwise rotation of the maxillomandibular complex. *Am J Orthod Dentofacial Orthop* 120: 154, 2001
6. Liukkonen M, Vahatalo K, Peltomaki T, Tiekso J, Happonen RP: Effect of mandibular setback surgery on the posterior airway size. *Int J Adult Orthodon Orthognath Surg* 17: 41, 2002
7. Turnbull NR, Battagel JM: The effects of orthognathic surgery on pharyngeal airway dimensions and quality of sleep. *J Orthod* 27: 235, 2000

8. Riley RW, Powell NB, Guilleminault C, Ware W: Obstructive sleep apnea syndrome following surgery for mandibular prognathism. J Oral Maxillofac Surg 45: 450, 1987
9. Athanasios AE, Toutountzakis N, Mavreas D, Ritzau M, Wenzel A: Alterations of hyoid bone position and pharyngeal depth and their relationship after surgical correction of mandibular prognathism. Am J Orthod Dentofac Orthop 100: 259, 1991
10. Kawamata A, Fujishita M, Arijii Y, Arijii E: Three-dimensional computed tomographic evaluation of morphologic airway changes after mandibular setback osteotomy for prognathism. Oral Surg Oral Med Oral Pathol Oral Radiol Endod 89: 278, 2000
11. Greco JM, Froberg U, Van Sickels JE: Long-term airway changes after mandibular setback using bilateral sagittal split osteotomy. Int J Oral Maxillofac Surg 19: 103, 1990
12. Hochbahn W, Schurmann R, Brandenburg U, Conrads R: Mandibular setback for surgical correction of mandibular hyperplasia-does it provoke sleep-related breathing disorders? Int J Oral Maxillofac Surg 25: 333, 1996

Yazışma Adresi: Dr. Dt. Çağrı DELİLBAŞI
Ankara Üniversitesi Diş Hekimliği Fakültesi
Ağız-Diş-Çene Hastalıkları ve Cerrahisi AD,
ANKARA
delilbasi@hotmail.com

¶*This study was presented in Turkish-Israeli Third Bi-National Conference on Oral and Maxillofacial Surgery, Antalya, 9-13 May 2001*