

Multidetector Computed Tomographic Angiography in the Assessment of the Hepatic Artery Variations

Hepatik Arter Varyasyonlarının Değerlendirilmesinde Çok Kesitli Bilgisayarlı Tomografik Anjiyografi

Aysel TÜRKVATAN, MD,^a
Ahmet AKGÜL, MD,^b
Sarper ÖKTEN, MD,^a
Özlem YENER, MD,^a
Mustafa ÖZDEMİR, MD,^a
Tülay ÖLÇER, MD,^a
Turhan CUMHUR, MD^a

^aDepartment of Radiology,
Türkiye Yüksek İhtisas Hospital,
^bBakırköy Dr Sadi Konuk Research
and Training Hospital, İstanbul
Ankara

Geliş Tarihi/Received: 04.12.2008
Kabul Tarihi/Accepted: 24.02.2009

Yazışma Adresi/Correspondence:
Aysel TÜRKVATAN, MD
Türkiye Yüksek İhtisas Hospital,
Department of Radiology, Ankara
TÜRKİYE/TURKEY
aturkvatan@yahoo.com

ABSTRACT Objective: The aim of this study is to assess the prevalence of hepatic artery variations seen during multidetector computed tomographic (MDCT) angiography. **Material and Methods:** The images of 700 consecutive patients who underwent hepatic artery angiography as a part of triphasic MDCT examination of the abdomen were retrospectively reviewed. The hepatic arterial anatomy was evaluated and analyzed for the presence of anatomic variants; classified according to a system created by Michels by noting the origins of the right and left hepatic arteries, and the presence of any accessory hepatic arteries. **Results:** Five hundred forty-eight (78.3%) cases had normal hepatic arterial anatomy (type 1) and 152 (21.7%) cases had variant anatomy. The most frequent variant (7.3%) was a replaced left hepatic artery from the left gastric artery (type 2) and the second most frequent variant (5.1%) was a replaced right hepatic artery from the superior mesenteric artery (type 3). Accessory left and right hepatic arteries (type 5 and 6) were identified in 2% and 2.1% of cases, respectively. The Michels' classification was not applicable in 8 (1.1%) cases. **Conclusion:** Due to the increasing availability of living liver transplant donors and the advent of interventional and new surgical techniques to treat primary and metastatic liver disease, the accurate definition of the hepatic arterial anatomy is important. MDCT angiography provides high quality 3D reconstructed images and enables noninvasive evaluation of normal anatomy and variants of the hepatic artery.

Key Words: Hepatic artery; tomography, X-ray computed; angiography.

ÖZET Amaç: Bu çalışmanın amacı çok kesitli bilgisayarlı tomografik (ÇKBT) anjiyografi sırasında görülen hepatic arter varyasyonlarının prevalansını değerlendirmektir. **Gereç ve Yöntemler:** Abdominal trifazik ÇKBT incelemesinin bir parçası olarak hepatic arter anjiyografisi geçiren ardışık 700 hastanın görüntüleri retrospektif olarak tekrar gözden geçirildi. Hepatic arteriyel anatomi, sağ ve sol hepatic arterlerin orijinleri ve aksesuar hepatic arterlerin varlığını dikkate alarak Michels tarafından oluşturulan bir sisteme göre sınıflandırılarak, anatomik varyantların varlığı açısından değerlendirildi ve analiz edildi. **Bulgular:** Beş yüz kırk sekiz (%78.3) olgu normal hepatic arteriyel anatomiye (tip 1), 152 (%21.7) olgu varyant anatomiye sahipti. En sık görülen varyant sol gastrik arterden köken alan sol hepatic arter (tip 2), ikinci sık varyant ise superior mezenterik arterden köken alan sağ hepatic arterdi (tip 3). Aksesuar sol ve sağ hepatic arterler (tip 5 ve 6) sırasıyla olguların %2 ve %2.1'inde tespit edildi. Michels sınıflandırması 8 (%1.1) olguda uygulanabilir değildi. **Sonuç:** Canlı karaciğer transplantasyon vericilerinin gittikçe artan kullanılabilirliği ve primer ve metastatik karaciğer tümörlerini tedavi etmek için girişimsel ve yeni cerrahi tekniklerin ortaya çıkması nedeni ile hepatic arteriyel anatominin doğru olarak belirlenmesi önemlidir. ÇKBT anjiyografi, yüksek kaliteli üç boyutlu rekonstrüksiyon görüntüleri sağlar ve hepatic arterin normal anatomi ve varyantlarının noninvaziv olarak değerlendirilmesine olanak verir.

Anahtar Kelimeler: Hepatic arter; bilgisayarlı tomografi; anjiyografi.

Knowledge of the variation of the hepatic vasculature is important in liver surgery especially in liver transplantation. Living related liver transplantation, a safe and efficacious treatment for end-stage liver disease, is becoming increasingly frequent because of the lack of compatible cadaveric donors.¹ This procedure allows healthy adults to donate a portion of their liver to a compatible recipient.² However, living related liver transplantation is technically more challenging than cadaveric whole liver transplantation, since donor liver resection must be performed in a way that results in a well vascularized graft without damage to the remaining liver of the donor. The complexity of the hepatic vascular anatomy contributes to the difficulty of surgical resection and the presence of variants could change the surgical approach, thus, an exact depiction of vascular anatomy of the donor liver before surgery is crucial.³ In addition, aberrant hepatic arteries can be of major significance during the surgery of the gallbladder, the upper intestinal tract and pancreas and in hepatic arterial infusion chemotherapy via catheter for treatment of unresectable advanced hepatic tumors.⁴ Conventional catheter angiography represents the gold standard of vascular imaging. Even though usually considered safe, it may be associated with complications that result from its invasive nature, with a complication rate of up to 1%.⁸ The introduction of MDCT has greatly improved the role of computed tomography (CT) in vascular studies. MDCT scanners have provided shorter image acquisition times, narrower collimation, improved temporal and spatial resolution, decreased motion and partial volume artifacts and near isotropic data acquisition compared with single-detector spiral CT. MDCT scanners are particularly useful for angiographic applications because they provide larger anatomic coverage, increased contrast enhancement of the arteries, and higher longitudinal spatial resolution.^{9,10} Several authors have reported that MDCT angiography was valuable in delineating hepatic vascular anatomy. Reported accuracy of MDCT angiography was 97-98% compared with conventional angiography for detecting hepatic arterial variants.^{11,12}

The purpose of this study was to assess and describe the prevalence of the variations in hepatic arteries seen with MDCT angiography in a large series of patients.

MATERIAL AND METHODS

PATIENTS

From June 2008 to November 2008, the hepatic arterial anatomy of the 722 consecutive patients who underwent hepatic artery angiography as part of triphasic MDCT examination of the abdomen in our department was retrospectively reviewed. Twenty-two patients were excluded from the study due to the presence of pathological conditions likely to affect normal vascular anatomy (n= 8) and severe artefact from respiratory motion (n= 14). All of the other 700 patients, in whom the MDCT angiographic procedure was technically adequate and provided necessary data with optimum arterial opacification, were included in this study. There were 407 (58%) male patients and 293 (42%) female patients. The mean age of the patients was 56.7 years (range 28 to 90).

Informed consent was obtained from all patients before they underwent MDCT examination, according to a protocol approved by the institutional review board. However, approval and informed consent were not required for retrospective review of patient images.

MDCT SCANNING TECHNIQUE

All MDCT examinations were performed by using a 16-slice MDCT scanner (GE Lightspeed Ultra, General Electrical Medical Systems, Milwaukee, Wisc.; USA). Patients were examined while supine and all images were acquired during a single breathhold, extending from the diaphragm to the lower pole of the right kidney for hepatic arterial phase of the triphasic abdominal MDCT. Imaging parameters were as follows: tube voltage, 120 kV; tube current, 120-240 mA, collimation, 16 x 1.25 mm; slice thickness, 1.25 mm; increment 0.6 mm; table feed 11.2 mm/sec; and gantry rotation time, 0.5 sec. The imaging data was acquired during an intravenous injection of 120 mL of iodinated contrast agent (Iodixanol, Visipaque 320 mgI/mL, GE

Healthcare, Milwaukee, Wisc.; USA) at a rate of 4 ml/sec. The scanning delay is determined with a bolus tracking technique. The examination was initiated 5 seconds after the attenuation of region of interest positioned in the aorta at the level of the celiac trunk reached 100 HU. For two-dimensional (2D) and three-dimensional (3D) image reconstruction, the raw CT data were processed on a separate workstation (Advanced Workstation 4.2, GE Healthcare, Milwaukee, Wisc.; USA).

IMAGE ANALYSIS

The study was regarded as diagnostic when the vascular structures were sufficiently contrast enhanced to allow reliable determination or exclusion of anatomic variants. Analysis of the image data was based on axial images and 2D and 3D postprocessing images (multiplanar reformatting, maximum intensity projection and volume rendering). Interpretations of all images were performed retrospectively by two radiologists and discrepancies were resolved by consensus. The hepatic arterial anatomy was evaluated and analyzed for the presence of anatomic variants, classified according to a system created by Michels by noting the origins of the right and left hepatic arteries and the presence of any accessory hepatic arteries (Table 1).¹³

RESULTS

According to the classification by Michels images in 548 (78.3%) cases revealed normal anatomy (type 1), with both lobes supplied by single arteries originating from the celiac trunk via the common and proper hepatic artery (Figure 1). In 152 (21.7%) cases, images revealed variants of the hepatic arterial supply. The most common hepatic artery variant in our series was a replaced left hepatic artery from the left gastric artery (type 2: n= 51, 7.3%), (Figure 2). The other variants were a replaced right hepatic artery from the superior mesenteric artery (type 3; n= 36, 5.1%), coexistence of a replaced left hepatic artery from the left gastric artery and a replaced right hepatic artery from the superior mesenteric artery (type 4; n= 11, 1.6%), an accessory left hepatic artery arising from left gastric artery (type 5; n= 14, 2%), an accessory right hepatic artery arising from the superior mesenteric artery (type 6; n= 15, 2.1%), coexistence of an accessory left hepatic artery arising from left gastric artery, and an accessory right hepatic artery arising from the SMA (type 7; n= 4, 0.6%) and a common hepatic artery arising from the superior mesenteric artery (type 9; n= 13, 1.9%), (Figures 3, 4, 5). No patients had type 8 and 10 anatomy.

TABLE 1: Variability of the hepatic arteries according to the Michels' classification compared to our study.

Anatomic Variation	Description	No. of cases in Michels' study (n= 200)	No. of cases in current study (n= 700)
Type 1	Normal	55% (110)	78.3% (548)
Type 2	Replaced LHA from LGA	10% (20)	7.3% (51)
Type 3	Replaced RHA from SMA	11% (22)	5.1% (36)
Type 4	Replaced LHA+ Replaced RHA	1% (2)	1.6% (11)
Type 5	Accessory LHA	8% (16)	2.0% (14)
Type 6	Accessory RHA	7% (14)	2.1% (15)
Type 7	Accessory LHA + Accessory RHA	1% (2)	0.6% (4)
Type 8	Combinations of Replaced + Accessory hepatic arteries	2% (4)	0
Type 9	CHA from SMA	4.5% (9)	1.9% (13)
Type 10	CHA from LGA	0.5% (1)	0
Others		0	1.1% (8)

LHA: Left hepatic artery, LGA: Left gastric artery, RHA: Right hepatic artery, SMA: Superior mesenteric artery, CHA: Common hepatic artery.

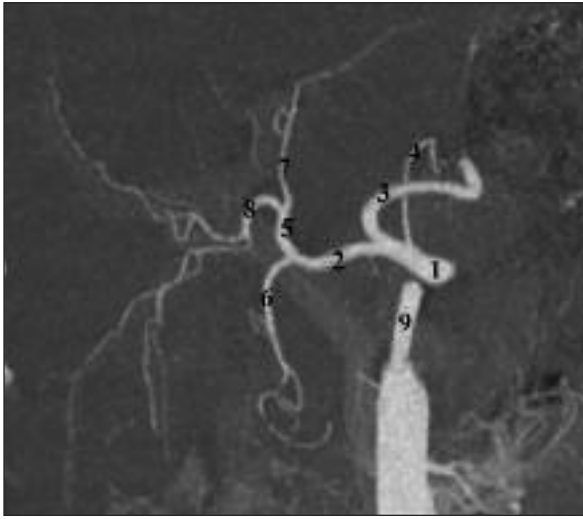


FIGURE 1: Coronal maximum intensity projection image shows classic (Michels type 1) hepatic arterial anatomy (1: celiac axis, 2: common hepatic artery, 3: splenic artery, 4: left gastric artery, 5: proper hepatic artery, 6: gastroduodenal artery, 7: left hepatic artery, 8: right hepatic artery, 9: superior mesenteric artery).

The Michels' classification system was not applicable in 8 (1.1%) cases of our study population. They were a common hepatic artery originating from the aorta ($n= 4, 0.6\%$), the right hepatic artery originating from the celiac axis ($n= 2, 0.3\%$), the right hepatic artery originating from the aorta ($n= 1, 0.1\%$) and the left hepatic artery originating

from the celiac axis ($n= 1, 0.1\%$) (Figure 6). Table 1 summarizes the our results of MDCT analysis of the hepatic arterial system according to the Michels' classification system.

DISCUSSION

The variations of the hepatic arterial anatomy has been widely described in the literature. Michels' classic autopsy series of 200 dissections, published in 1966, defined the basic anatomic variations in hepatic arterial supply and has served as the benchmark for all subsequent contributions in this area.¹³ Michels described 10 types of configuration for the hepatic artery, including normal anatomy in type 1 and gathering all the other variants in types 2 to 10. The term 'replaced' was used by Michels to refer to cases in which the entire blood supply to a side of the liver originates from an atypical location and the term 'accessory' was used to refer to cases in which a blood supply in addition to the normal arterial supply.¹³ Due to the difficulties in angiographic differentiation between replaced and accessory hepatic arteries, Michels's classification was modified and simplified by Hiatt in 1994.¹⁴ Hiatt distinguishes only six categories of configuration for the hepatic arterial anatomy: the normal anatomy (type 1), the replaced or accessory left he-

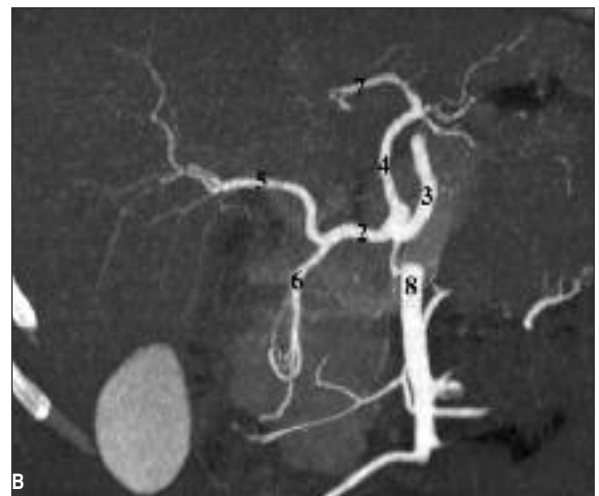
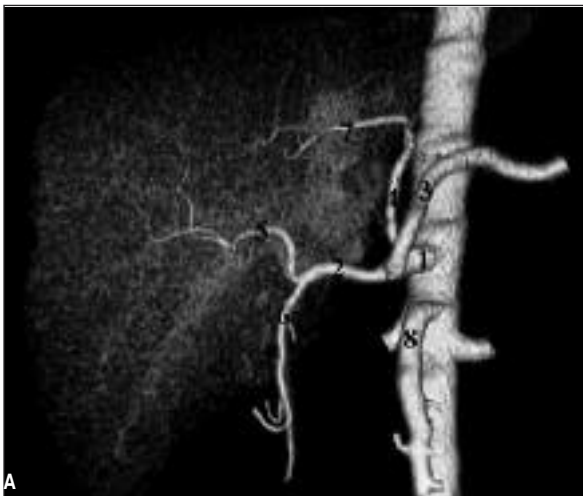

FIGURE 2: Coronal volume rendering (A) and maximum intensity projection (B) images show replaced left hepatic artery originating from the left gastric artery (Michels type 2). (1: celiac axis, 2: common hepatic artery, 3: splenic artery, 4: left gastric artery, 5: right hepatic artery, 6: gastroduodenal artery, 7: replaced left hepatic artery, 8: superior mesenteric artery).

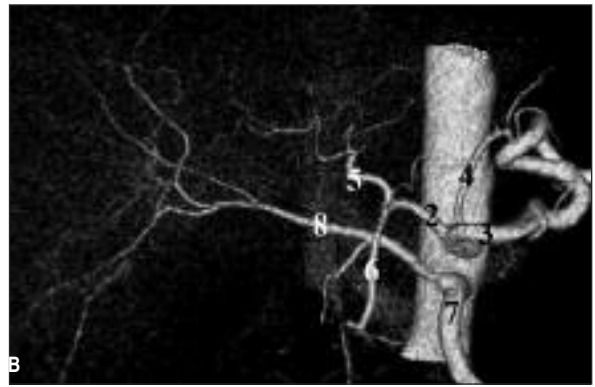
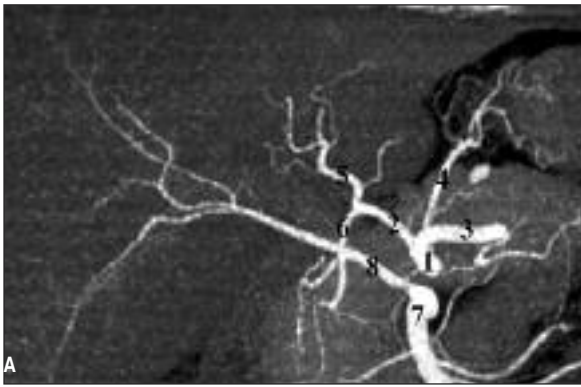

FIGURE 3: Coronal maximum intensity projection (A) and volume rendering (B) images show replaced right hepatic artery originating from the superior mesenteric artery (Michels type 3). (1: celiac axis, 2: common hepatic artery, 3: splenic artery, 4: left gastric artery, 5: left hepatic artery, 6: gastroduodenal artery, 7: superior mesenteric artery, 8: replaced right hepatic artery).

hepatic artery arising from the left gastric artery (type 2), the replaced or accessory right hepatic artery originating from the superior mesenteric artery (type 3), every combination of double replaced pattern (type 4), the common hepatic artery arising from the superior mesenteric artery (type 5) and the common hepatic artery arising directly from the aorta (type 6).¹⁴

Even though it is an anatomical classification having less relevance in today's modern surgical practice than in the past, we referred to Michels' classification to describe hepatic artery variants since it is the most commonly used one.

In normal hepatic arterial anatomy, the celiac trunk arises from the abdominal aorta and splits into three branches. The first branch is the left gastric artery, after which the vessel divides into the splenic artery and the common hepatic artery. The common hepatic artery then bifurcates into the gastroduodenal artery and the proper hepatic artery, and the proper hepatic artery bifurcates into the right hepatic artery and the left hepatic artery. The normal hepatic arterial anatomy was reported in 55% of patients by Michels.¹³ However, most of angiographic studies showed a higher rate of normal hepatic anatomy.¹⁵⁻²¹ Koops et al and Arjhansiri et al reported that the prevalence of normal hepatic anatomy was 79.1% and 80.5%, respectively.^{20,21} Like these studies, our MDCT angiography

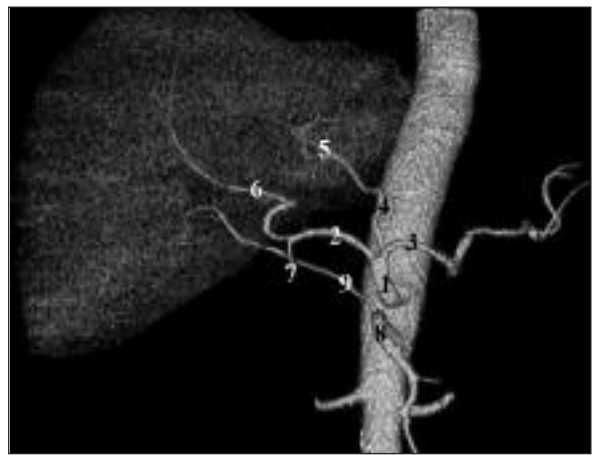

FIGURE 4: Coronal volume rendering image shows both replaced left hepatic artery originating from the left gastric artery and replaced right hepatic artery originating from the superior mesenteric artery (Michels type 4). (1: celiac axis, 2: common hepatic artery, 3: splenic artery, 4: left gastric artery, 5: replaced left hepatic artery, 6: middle hepatic artery, 7: gastroduodenal artery, 8: superior mesenteric artery, 9: replaced right hepatic artery).

study showed a higher rate (78.3%) of normal hepatic artery anatomy. According to the Michels' classification, the most common (11%) hepatic arterial variant is a replaced right hepatic artery originating from the superior mesenteric artery (type 3) and the second most common (10%) variant is a replaced left hepatic artery originating from the left gastric artery (type 2).¹³ Although most of conventional and MDCT angiographic studies showed that the most common variant is type 3, in our study we

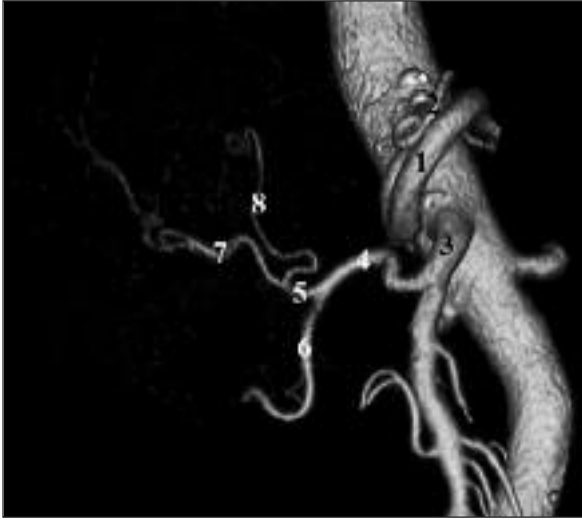

FIGURE 5: Coronal volume rendering image shows the common hepatic artery arising from the superior mesenteric artery (Michels type 9). (1: splenic artery, 2: left gastric artery, 3: superior mesenteric artery, 4: common hepatic artery, 5: proper hepatic artery, 6: gastroduodenal artery, 7: right hepatic artery, 8: left hepatic artery).

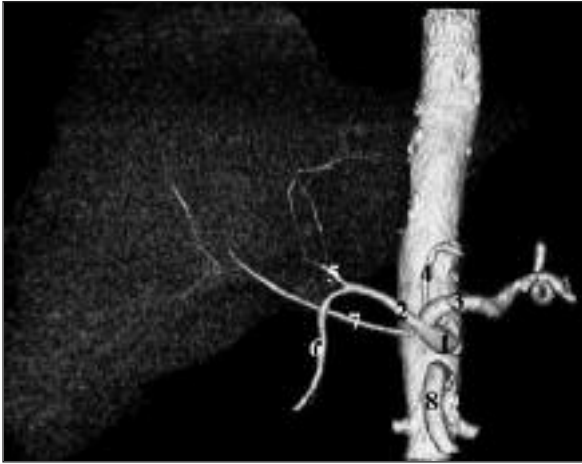


FIGURE 6: Coronal volume rendering image shows right hepatic artery originating from the celiac axis (double hepatic artery). (1: celiac axis, 2: common hepatic artery, 3: splenic artery, 4: left gastric artery, 5: left hepatic artery, 6: gastroduodenal artery, 7: right hepatic artery, 8: superior mesenteric artery).

found that the most common variant (7.3%) is type 2 and the second most common (5.1%) variant is type 3.^{16,17,19-23} Similar to our study results, Suzuki et al and Chen et al reported the frequency of type 2 variants as 8% and 7.8% respectively, and the frequency of type 3 variant as 3.5% and 5.2% respec-

tively.^{15,18} Recognition of a replaced right hepatic artery is important when performing pancreaticoduodenectomy and for porta hepatis dissection during hepatic resection. Thereby, if a head or uncinate process pancreatic cancer involves this vessel, it precludes the patient from surgical resection.⁶ Also, it is important to identify a replaced left hepatic artery, prior to the left hepatectomy since this vessel must be ligated; the recognition of this variant facilitates portal dissection because the major arterial branch to the left lobe of the liver does not need to be found in the porta hepatis.^{5,6}

In our study, the accessory left and right hepatic arteries (Michels type 5 and 6) were identified respectively in 2% and 2.1% of the patients. This result is lower than that reported by Michels, but in concordance to the most angiographic studies.^{6,13,16,18,20} There was a general variability in the number of detected accessory hepatic arteries, with lower rates of these anatomic patterns in the recent angiographic studies. We considered that this difference is due to the small size of these accessory branches, causing lower detectability by angiography. The difficulty in imaging associated with the subdivision into accessory or replaced aberrant hepatic arteries may lead the accessory arteries to be missed in angiography generally. In establishing the extent of probable ischemic complications related to the loss of hepatic arteries it is essential to know whether an aberrant artery can be considered as replaced or an accessory. However, embryologic and postmortem studies have shown that even accessory arteries supply a specific territory of the liver, suggesting that these arteries should be considered as replacing arteries as well.^{24,25}

No cases of Michels type 8 and 10 variants were found in our study, whereas the literature reports a mean prevalence of $0.4 \pm 0.7\%$ and $0.1 \pm 0.2\%$, respectively.²² The prevalences of the rare anomalies not classified by Michels ranged from 1% to 14.7% in angiographic studies.¹⁵⁻²¹ The Michels' classification system was not applicable in 8 (1.1%) cases of our study population. The common hepatic artery arising directly from the aorta (Hiatt type 6) was seen in 0.6% of the patients in our

study. A 'double hepatic artery' as described by Fasel et al refers to a right or left hepatic artery originating from the celiac trunk or the aorta.²⁶ This variant was seen in 0.5% of patients in our study population, a result similar to that reported by Koops et al as seen in digital subtraction angiography.²⁰

In 1969, Redman and Reuter reported that most of the variations of the hepatic artery have a little surgical significance.²⁷ However, today, the exact depiction and definition of the hepatic arterial variants are important due to the increasing availability of living related liver transplant donors and the advent of interventional and new surgical techniques to treat both primary and metastatic liver disease. It is also essential that interventional radiologists who perform hepatic arterial embolization be familiar with both common and rare hepatic arterial variants, since failure to recognize the presence of an aberrant vessel can cause incomplete embolization.

Conventional catheter angiography has traditionally been used for the evaluation of vascular architecture, though recently MDCT angiography has been emerged as a noninvasive alternative.^{9,10} MDCT offers the latest advancements in CT technology by combining multiple rows of detectors and faster gantry rotation speeds. MDCT technology has further improved the capability of spiral CT to provide precise and high definition vascular details noninvasively. The rapid scanning capability of MDCT allows optimal phase scanning in a short breath-hold, which is within the time of dynamic administration of a single bolus of contrast material. The advantages of increased z-axis coverage and thinner slice acquisition during the shorter scanning time have resulted in improved spatial resolution and better depiction of vascular deta-

ils.^{9,10} Chambers et al showed the ability of helical CT without reconstructions to correctly depict hepatic arterial anatomy, with 96% sensitivity and 87% specificity for detecting aberrant hepatic arteries.²⁸ However, 2D and 3D images provide better definition and better display of the anatomy and course of the vessels, which resembles traditional arteriograms and provides the surgeon with a 3D model of the patient's arterial anatomy.^{22,23,29} Volume rendering and maximum intensity projection techniques are optimal choices in situations when the vessels are tortuous. Maximum intensity projection images are more useful especially for the evaluation of smaller branch vessels and it is widely used in the assessment of the hepatic vasculature.³⁰ In the study by Byun et al the maximum intensity projection technique was found to be superior to volume rendering technique for hepatic arterial assessment in terms of depicting anatomic variations and of postprocessing time in MDCT angiography.³¹

A limitation of this study is that we do not have conventional angiographic or surgical confirmation of the accuracy of the MDCT findings. However, the overall prevalence of hepatic arterial variants in our study is in concordance with that described in the conventional catheter angiography literature.

CONCLUSION

Due to the increasing availability of living related liver transplant donors and the advent of interventional and new surgical techniques to treat both primary and metastatic liver diseases, the exact depiction of the hepatic arterial anatomy is important. MDCT enables high quality 3D reconstructed images and allows noninvasive evaluation of normal anatomy and variants of hepatic artery.

REFERENCES

1. Broelsch CE, Frilling A, Testa G, Malago M. Living donor liver transplantation in adults. *Eur J Gastroenterol Hepatol* 2003;15(1):3-6.
2. Hashikura Y, Makuuchi M, Kawasaki S, Matsunami H, Ikegami T, Nakazawa Y, et al. Successful living-related partial liver transplantation to an adult patient. *Lancet* 1994; 343(8907):1233-4.
3. Imamura H, Makuuchi M, Sakamoto Y, Sugawara Y, Sano K, Nakayama A, et al. Anatomical keys and pitfalls in living donor liver transplantation. *J Hepatobiliary Pancreat Surg* 2000;7(4):380-94.
4. Sahani D, Mehta A, Blake M, Prasad S, Harris G, Saini S. Preoperative hepatic vascular evaluation with CT and MR angiography: implications for surgery. *Radiographics* 2004; 24(5):1367-80.
5. Catalano OA, Singh AH, Uppot RN, Hahn PF, Ferrone CR, Sahani DV. Vascular and biliary variants in the liver: implications for liver surgery. *Radiographics* 2008;28(2):359-78.
6. Winston CB, Lee NA, Jamagin WR, Teitcher J, DeMatteo RP, Fong Y, et al. CT angiography for delineation of celiac and superior mesenteric artery variants in patients undergoing hepatobiliary and pancreatic surgery. *AJR Am J Roentgenol* 2007;189(1):W13-9.
7. Ganeshan A, Upponi S, Hon LQ, Warakaulle D, Uberoi R. Hepatic arterial infusion of chemotherapy: the role of diagnostic and interventional radiology. *Ann Oncol* 2008;19(5): 847-51.
8. Hyare H, Desigan S, Nicholl H, Guiney MJ, Brookes JA, Lees WR. Multi-section CT angiography compared with digital subtraction angiography in diagnosing major arterial hemorrhage in inflammatory pancreatic disease. *Eur J Radiol* 2006;59(2):295-300.
9. Prokop M. Multislice CT angiography. *Eur J Radiol* 2000;36(2):86-96.
10. Duddalwar VA. Multislice CT angiography: a practical guide to CT angiography in vascular imaging and intervention. *Br J Radiol* 2004; 77(Spec No 1):S27-38.
11. Sahani D, Saini S, Pena C, Nichols S, Prasad SR, Hahn PF, et al. Using multidetector CT for preoperative vascular evaluation of liver neoplasms: technique and results. *AJR Am J Roentgenol* 2002;179(1):53-9.
12. Takahashi S, Murakami T, Takamura M, Kim T, Hori M, Narumi Y, et al. Multi-detector row helical CT angiography of hepatic vessels: depiction with dual-arterial phase acquisition during single breath hold. *Radiology* 2002;222(1): 81-8.
13. Michels NA. Newer anatomy of the liver and its variant blood supply and collateral circulation. *Am J Surg* 1966;112(3):337-47.
14. Hiatt JR, Gabbay J, Busuttill RW. Surgical anatomy of the hepatic arteries in 1000 cases. *Ann Surg* 1994;220(1):50-2.
15. Suzuki T, Nakayasu A, Kawabe K, Takeda H, Honjo I. Surgical significance of anatomic variations of the hepatic artery. *Am J Surg* 1971;122(4):505-12.
16. Daly JM, Kemeny N, Oderman P, Botet J. Long-term hepatic arterial infusion chemotherapy. Anatomic considerations, operative technique, and treatment morbidity. *Arch Surg* 1984;119(8):936-41.
17. Rygaard H, Forrest M, Mygind T, Baden H. Anatomic variants of the hepatic arteries. *Acta Radiol Diagn (Stockh)* 1986;27(4):425-7.
18. Chen CY, Lee RC, Tseng HS, Chiang JH, Hwang JI, Teng MM. Normal and variant anatomy of hepatic arteries: angiographic experience. *Zhonghua Yi Xue Za Zhi (Taipei)* 1998;61(1):17-23.
19. Covey AM, Brody LA, Maluccio MA, Getrajdman GI, Brown KT. Variant hepatic arterial anatomy revisited: digital subtraction angiography performed in 600 patients. *Radiology* 2002;224(2):542-7.
20. Koops A, Wojciechowski B, Broering DC, Adam G, Krupski-Berdién G. Anatomic variations of the hepatic arteries in 604 selective celiac and superior mesenteric angiographies. *Surg Radiol Anat* 2004;26(3):239-44.
21. Arijhansiri K, Charoenrat P, Kitsukijit W. Anatomic variations of the hepatic arteries in 200 patients done by angiography. *J Med Assoc Thai* 2006;89(Suppl 3):S161-8.
22. Iezzi R, Cotroneo AR, Giancristofaro D, Santoro M, Storto ML. Multidetector-row CT angiographic imaging of the celiac trunk: anatomy and normal variants. *Surg Radiol Anat* 2008;30(4):303-10.
23. Schroeder T, Radtke A, Kuehl H, Debatin JF, Malagó M, Ruehm SG. Evaluation of living liver donors with an all-inclusive 3D multi-detector row CT protocol. *Radiology* 2006; 238(3):900-10.
24. Miyaki T, Sakagami S, Ito H. Intrahepatic territory of the accessory hepatic artery in the human. *Acta Anat (Basel)* 1989;136(1):34-7.
25. Miyaki T. Patterns of arterial supply of the human fetal liver. The significance of the accessory hepatic artery. *Acta Anat (Basel)* 1989; 136(2):107-11.
26. Fasel JH, Muster M, Gailloud P, Mentha G, Terrier F. Duplicated hepatic artery: radiologic and surgical implications. *Acta Anat (Basel)* 1996;157(2):164-8.
27. Redman HC, Reuter SR. Angiographic demonstration of surgically important vascular variations. *Surg Gynecol Obstet* 1969;129(1): 33-9.
28. Chambers TP, Fishman EK, Bluemke DA, Urban B, Venbrux AC. Identification of the aberrant hepatic artery with axial spiral CT. *J Vasc Interv Radiol* 1995;6(6):959-64.
29. Ferrari R, De Cecco CN, Iafate F, Paolantonio P, Rengo M, Laghi A. Anatomical variations of the coeliac trunk and the mesenteric arteries evaluated with 64-row CT angiography. *Radiol Med* 2007;112(7):988-98.
30. Saba L, Mallarini G. Multidetector row CT angiography in the evaluation of the hepatic artery and its anatomical variants. *Clin Radiol* 2008;63(3):312-21.
31. Byun JH, Kim TK, Lee SS, Lee JK, Ha HK, Kim AY, et al. Evaluation of the hepatic artery in potential donors for living donor liver transplantation by computed tomography angiography using multidetector-row computed tomography: comparison of volume rendering and maximum intensity projection techniques. *J Comput Assist Tomogr* 2003;27(2):125-31.