

A Clinical and Densitometric Study with Demineralized Bone Matrix and Collagraft™ Bone Graft Matrix[¶]

DEMİNERALİZE KEMİK GREFTİ VE COLLAGRAFT™ KEMİK GREFT MATERYALI İLE YAPILAN BİR KLİNİK VE DENSİTOMETRİK ÇALIŞMA

Nejat Bora SAYAN*, Ümit Kıymet AKAL**, Zafer Özgür PEKTAŞ***, Meltem ŞAHİN****, Ebru ACAR***

* Prof., University of Ankara, Faculty of Dentistry, Dept. of Oral and Maxillofacial Surgery,

** Ass. Prof, University of Ankara, Faculty of Dentistry, Dept. of Oral and Maxillofacial Surgery,

*** DDS, University of Ankara, Faculty of Dentistry, Dept. of Oral and Maxillofacial Surgery,

**** DDS, University of Ankara, Faculty of Dentistry, Dept. of Oral Diagnosis and Radiology, Ankara, TURKEY

Summary

Purpose: The purpose of this study is to demonstrate the clinical application of Collagraft™ strip bone graft matrix and demineralized bone matrix (DBM) in maxillofacial surgery and compare these two bone substitutes radiographically with densitometric analysis.

Materials and Methods: From 32 patients who was referred to Ankara University Faculty of Dentistry Department of Oral and Maxillofacial Surgery, Collagraft™ was applied to 12 patients with 14 bony defects, DBM was used in 10 patients with 10 bony defects and 10 patients served as the control group. Standard radiographic examination was performed preoperatively, on postoperative first week, first month and third month.

Results: The bone densitometric analysis was used on the radiographs and the data was evaluated statistically. Postoperative first month data of each three group are evaluated and there was a statistically significant difference between them. ($p < 0.005$)

Conclusion: The total mean values for Collagraft™ and DBM groups were higher than the control group.

Key Words: Demineralized bone matrix, Bone graft matrix, Bone densitometric analysis.

T Klin J Dental Sci 2002, 8:134-139

Özet

Amaç: Bu çalışmanın amacı; Collagraft™ strip kemik matriksi ile demineralize kemik matriksi (DBM)'nin klinik uygulanabilirliğini ve densitometrik analizle elde edilen radyolojik sonuçlarını karşılaştırmaktır.

Materyal ve Metod: Ankara Üniversitesi Diş Hekimliği Fakültesi Oral ve Maksillofasiyal Cerrahi bölümüne başvuran 32 hastadan, 12'sinde 14 kemik defektine Collagraft™, 10 hastada 10 kemik defektine DBM uygulandı. 10 hasta da kontrol grubu olarak alındı. Operasyon öncesi ve operasyon sonrası 1. hafta, 1. ay ve 3. ay radyografik muayeneleri tamamlandı.

Bulgular: Radyografların densitometrik analizleri yapıldı ve sonuçlar istatistiksel olarak değerlendirildi. Her 3 grubun sonuçlarına göre postoperatif 1. ayda her üç grup arasındaki fark istatistiksel olarak anlamlı bulundu. ($p < 0.05$)

Sonuçlar: Densitometrik analiz sonrası total değerlere bakıldığında, Collagraft™ ve DBM gruplarının, kontrol grubuna göre daha yüksek sonuçlar verdiği görüldü.

Anahtar Kelimeler: Demineralize kemik matriksi, Kemik grefti, Densitometrik kemik analizi

T Klin Diş Hek Bil 2002, 8:134-139

Reconstruction of craniofacial skeletal defects as a consequence of trauma, infection, pathologic conditions, developmental anomalies or oncologic resections, remains a challenge in maxillofacial surgery. In a small bony defect, the blood clot is replaced by immature bone and this replacement is completed by osteoblasts that differentiate from the endosteum or marrow spaces while healing of larger skeletal defects takes place from the

periphery over a period of months. When a bony defect left to heal spontaneously, the rapid ingrowth of the connective tissue to the defect site could hinder the bone healing. To overcome this problem, a great number of graft materials have been developed and each year, more than 250.000 bone graft procedures are being performed by reconstructive surgeons to restore lost tissue (1). Other indications for bone grafting comprise the

augmentation of atrophic jaws, temporomandibular joint surgery, orthognathic surgery, sinus lifting and implantation, surgical management of maxillofacial fractures and closure of oro-nasal and oro-antral fistulas. Grafting of craniofacial bony defects can be accomplished by; autogenous bone, allogenic bone, xenogenic bone, lyophilized cartilage and by alloplastic bone substitutes (2-6). Within these groups, autogenous bone grafts remains the most effective grafting material because of its advantages. They are biocompatible, do not cause an immunological reaction, have a high revascularization rate, cost effective and provide the three elements, osteoconduction, osteoinduction and osteogenic cells for bone healing. Although autogenous bone remains the most effective material for bone grafting (7), these techniques subject patients to a second surgical site, which may increase morbidity (8-10%), complications and hospitalization (8). Further complications of autogenous grafting involves the greater risk for wound infection, blood loss, long lasting return to normal function, limited amount of harvested bone and unpredictable graft resorption. From this point of view, many alternative graft materials have been proposed to eliminate or decrease the possible complications or shortcomings associated with autogenous grafting. Collagraft™ Strip bone graft matrix and demineralized bone matrix (DBM) are two of these bone graft substitutes that have been developed to facilitate the grafting procedures in bony reconstruction.

The purpose of this study is to demonstrate the clinical application of Collagraft™ Strip bone graft matrix and demineralized bone matrix (DBM) in maxillofacial surgery and compare these two bone substitutes radiographically with densitometric analysis.

Material and Methods

The study involves thirty-two patients that were referred to Ankara University, Faculty of Dentistry, Department of Oral and Maxillofacial Surgery from the Department of Oral Diagnosis and Radiology for the management of various degenerative, inflammatory and cystic lesions. After the surgical enucleation of these lesions, Collagraft™ was applied to twelve patients with fourteen bony defects, DBM was used in ten patients with ten bony defects while another ten patients served as the control group. Standard radiographic examination was performed preoperatively, on postoperative first week, first month and third month for each patient. The periapical radiographs were obtained using Kodak Ultraspeed-D films (Figure 1,2). For standardization of parallel techniques, Rinn XCP (extension cone paralleling) was used for each patient. The X-ray tube was Heliodent Dentotime with an electronic timer at 15 mA ,70 kvp and 0.4 sec. exposure time. Panoramic machine was Trophy, 10 mA ,75 kvp and 12 sec. exposure time. The parallel and panoramic films were developed

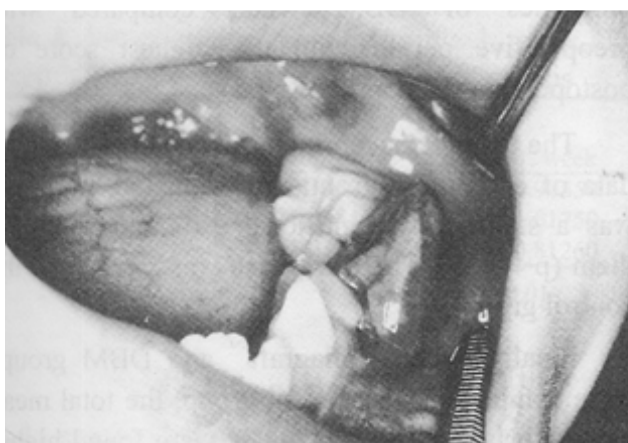


Figure 1A. Clinical appearance of intraluminal ameloblastoma in the left mandibular bicuspidal region.

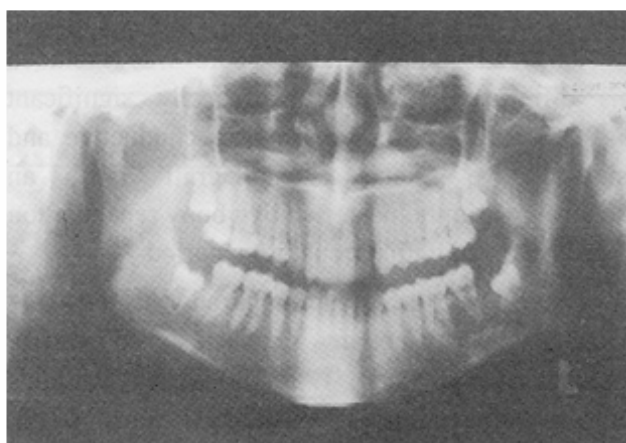


Figure 1B. Radiographic view of the lesion.

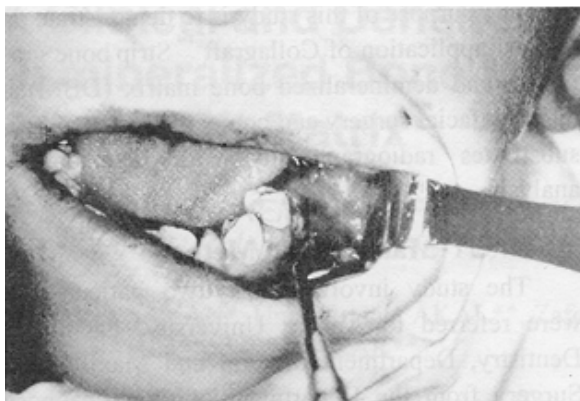


Figure 1C. Bony defect following the enucleation of the lesion.

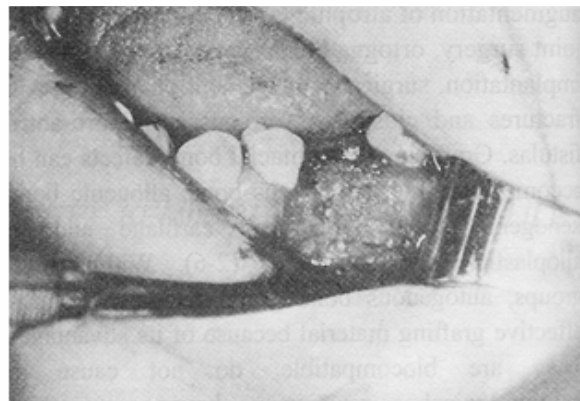


Figure 1D. Reconstruction of bone defect with DBM putty.

by using a Durr Dental DL-24 automatic developing machine with Hacettepe solution.

The bone densitometric analysis was used on the radiographs and the data was evaluated statistically with Friedman, Wilcoxon signed Ranks and Kruskal-Wallis tests.

Results

Preoperative, postoperative 1. week, 1.month and 3. month results of densitometric analysis concerning Collagraft™, DBM and control groups were compared in each three separate group, and between these groups (Table 1).

When the data concerning Collagraft™ group is compared between itself, the difference between, preoperative, postoperative 1.week, 1.month and 3. month's results was found statistically significant ($p < 0.05$). When preoperative score was excluded this difference was not statistically significant ($p > 0.05$) and this shows the osteoconductive and osteoinductive effect of Collagraft™ with an enhancement in the postoperative bony regeneration when compared with preoperative period.

When DBM group is compared with the same method, the difference between preoperative, postoperative 1. week, 1. month and 3. month's scores was found statistically significant ($p < 0.05$). The difference was mainly because of data obtained on 1. month. The results also revealed the osteoinductive, osteoconductive and regenerative

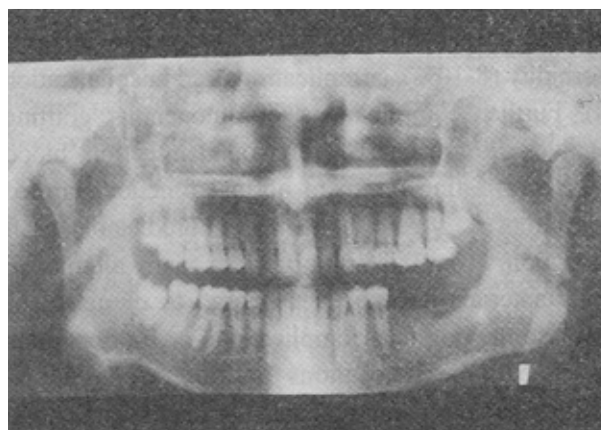


Figure 1E. Radiographic appearance after application of DBM putty form to the defect (postop. 3. month).

properties of DBM when compared with preoperative period with the highest score on postoperative 1. month ($p < 0.05$).

The results concerning postoperative 1. month data of each three group are evaluated and there was a statistically significant difference between them ($p < 0.05$). The difference was a result of the control group.

Finally, when Collagraft™ and DBM groups were compared with control group, the total mean values for two bone substitutes were found higher than the control group with a slight increase in DBM although the difference was not statistically significant ($p > 0.05$).

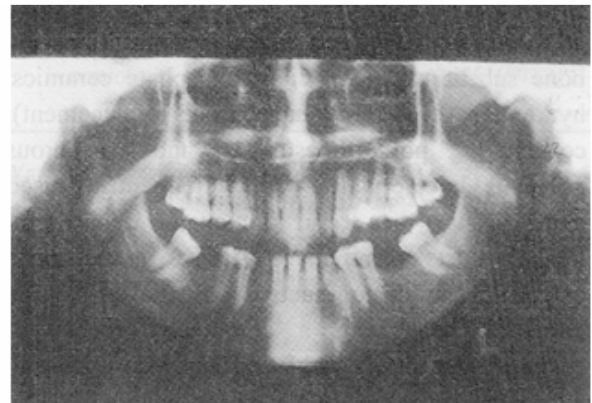
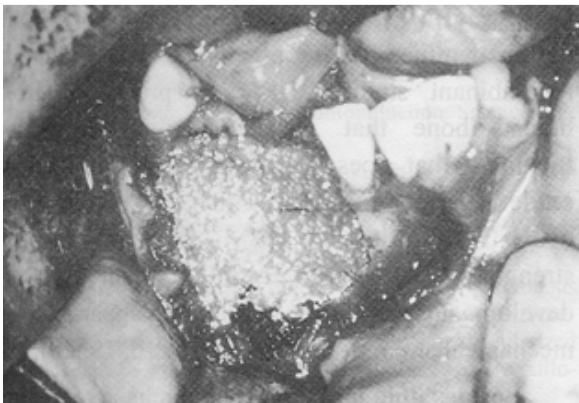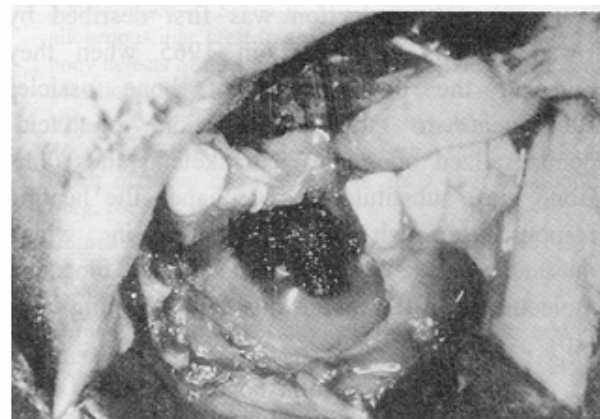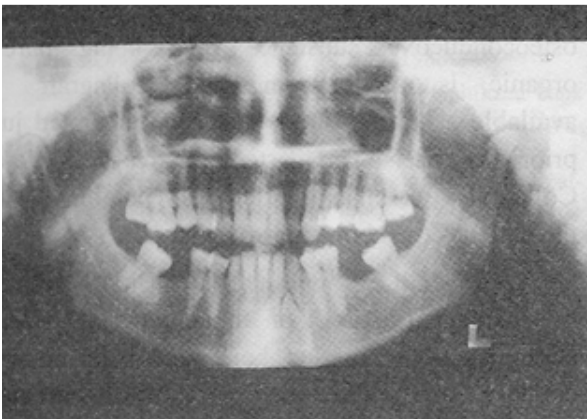


Figure 2C. Application of Collagraft™ Strip Bone Graft Matrix to bony defect.

Figure 2D. Radiographic appearance after application of Collagraft™ Strip Bone Graft Matrix to the defect (postop. 3. month).

Table 1. Pre-operative, post-operative 1. week, 1.month and 3. month results of densitometric analysis concerning Collagraft, DBM and control groups

	preoperative	1. week	1.month	3. month	mean
Collagraft	0.97821	0.97350	1.13914	1.13386	1.0822
DBM	1.04840	1.01750	1.20890	1.11070	1.1124
Control	1.01230	0.81260	0.82980	0.91960	0.8540

P= 0.01

Discussion

As a general clinical acceptance, an ideal bone substitute should be biocompatible, have good mechanical properties and show osteoinductive or at least osteoconductive capacities (9). Production

of new bone through osteoconductive healing permits bone graft substitutes to provide a suitable matrix for cells to infiltrate and populate (10). Herein, bone graft substitute acts as a scaffold for bone ingrowth and is supposed to be replaced by

bone (9). Osteoinduction was first described by Urist and his colleagues in 1965 when they revealed the development of bone ossicles subsequent to the implantation of acid-demineralized bone into extraskelatal sites (11). Bone graft substitutes may enhance the healing response through osteoinduction in which mesenchymal cells are stimulated by bioactive molecules to differentiate into bone-forming cells (10).

A number of various bone substitutes have been used for many years for the reconstruction of craniofacial defects. Allogenic bone grafts or banked bone substitutes mainly consist of freeze-d, freeze-dried (lyophilized), demineralized, decalcified, deproteinized, fresh-freezed bone and dehydrated bone with solvents while a wide range of materials have been introduced as alloplastic bone substitutes. Tricalcium phosphate ceramics, hydroxyapatite, HTR (Hard Tissue Replacement), cement, polyorthoester and porous polymethylmetacrylate are frequently used materials for the reconstruction of craniofacial bony defects. Autogenous bone grafts have osteogenic and osteoinductive potential while the allografts heal with a combined process of osteoinduction, osteoconduction and resorption and alloplastic grafts heal with osteoconduction (12-15). Despite the current bone graft alternatives that are available in different forms and patterns, many studies are still being held to achieve an ideal graft material.

Collagraft™ Strip Bone Graft Matrix is a composite of suspended fibrillar collagen and a porous calcium phosphate ceramic. The fibrillar collagen is highly purified collagen obtained from bovine dermis and is ninety-five percent type I collagen with small amounts (5%) of type III collagen. The porous calcium phosphate ceramic consists of granules composed of approximately sixty-five percent hydroxyapatite and thirty-five percent tricalcium phosphate. The granules have a pore volume of approximately seventy percent and range in diameter from 0.5 to 1.0 mm. Porous hydroxyapatite and tricalcium phosphate ceramics have demonstrated osteoconductive properties and

purified xenographic collagen is also an affective osteoconductive substance that, being purely organic, is rapidly remodeled. Collagraft™ is available as sterile strips that are rehydrated just prior to use. The osteoinductive effect of Collagraft™ was also reported when combined with the patient's own bone marrow (16-18).

Demineralized bone matrix (DBM) is formed by acid extraction of bone, which leaves noncollagenous proteins, bone growth factors and collagen in continuity in a composite. Currently, DBM is available freeze-dried and is processed from cortical or corticocancellous bone as a powder, as crushed granules and as chips. The enhanced osteoinductive capability of DBM is afforded most notably by bone morphogenetic proteins (BMP), although the amount of BMP within demineralized grafts is far lower than in recombinant studies. DBM is processed from human bone that incorporates a permeation treatment that doesn't expose tissue to ethylene oxide or gamma radiation, which may protect more of the BMP. Although DBM offers no structural strength, it has proved useful in facilitating the development of bone that is comparable in mechanical strength to autograft (9, 10, 19, 20).

Besides the individual researchs concerning the results and clinical applications of these two graft materials, a comparative clinical or radiographical study is not available to our knowledge. The results of this study reveals an enhancement for bone healing using allogenic and alloplastic bone grafts with their osteoinductive and osteoconductive properties and they help to overcome the disadvantages associated with autogenous grafts. Nevertheless, the choice and the pattern of bone grafting should be considered according to individual factors for each case.

REFERENCES

1. Goldberg V, Stevenson S, Shafer J: Biology of autografts and allografts. In Friedlaender GE, Goldberg VM (eds). Bone and Cartilage Allografts: Biology and Clinical Application. Park Ridge, IL. AAOS, 1991, p.3-12.
2. Horowitz I, Bodner L: Use of xenograft bone with aspirated bone marrow for treatment of cystic defects of the jaws. Head Neck, 11: 516, 1989

3. Richter M, Laurent F, Cheusse JM: Homologous cancellous bone grafts for large jaw defects caused by bone cysts. *J Oral Maxillofac. Surg*, 44: 447, 1986
4. Sailer HF: Experience with the use of lyophilized bank cartilage for facial contour correction. *J Max. Fac. Surg*, 4: 149, 1976
5. Spengos MN: Irradiated allogenic bone grafts in the treatment of odontogenic cysts. *J Oral Surg*, 32: 674, 1974
6. Szabo G, Suba Z, Barabas J: Use of Bioplast HTR synthetic bone to eliminate major jawbone defects: long-term human histological examinations. *J Cranio-Maxillofac. Surg*, 25: 63, 1997
7. Goldberg VM, Stevenson S: Natural history of autografts and allografts. *Clin Orthop*, 225: 7, 1987
8. Yunger Em, Chapman MW: Morbidity at bone graft donor sites. *J Orthop Trauma*, 3: 192, 1989
9. Dupoirieux L, Costes V, Jammet P, Souyris F: Experimental study on demineralized bone matrix (DBM) and coral as bone graft substitutes in maxillofacial surgery. *Int J Oral Maxillofac. Surg*, 23: 395, 1994
10. Chesmel KD, Branger J, Wertheim H, Scarborough N: Healing response to various forms of human demineralized bone matrix in athymic rat cranial defects. *J Oral Maxillofac. Surg*, 56: 857, 1998
11. Urist MR: Bone: formation by autoinduction. *Science*, 150: 893, 1965
12. Cohen ES: Guided tissue regeneration in combination with demineralized freeze-dried bone allograft using a nonresorbable membrane. *Compend Contin Educ Dent*, 16: 846 1995
13. Schmelzeisen R, Boetel C, Schuberth HJ, Pohlmeier K: Experimental transplantation of vascularized autologous and allogenic bone grafts for mandibular defects. Anatomical, immunological and surgical basis for vascularized bone transfer in the Gottingen minipig. *Int J Oral Maxillofac. Surg*, 20: 239, 1991
14. Schmelzeisen R, Schon R: Microvascular reanastomosed allogeneous iliac crest transplants for the reconstruction of bony defects of the mandible in miniature pigs. *Int J Oral Maxillofac Surg*, 27: 377, 1998
15. Viljanen VV, Lindholm TC, Gao TJ, Lindholm TS: Low dosage of native allogenic bone morphogenetic protein in repair of sheep calvarial defects. *Int J Oral Maxillofac Surg*, 26: 389, 1997
16. Cornell CN: Initial clinical experience with use of Collagraft™ as a bone graft substitute. *Techniques In Orthopaedics*, 7: 55, 1992
17. Cornell CN, Lane J, Chapman M: Multicenter trial of Collagraft™ as bone graft substitute. *J Orthop Trauma*, 5(1): 1, 1991
18. Black RJ, Zardiackas LD, Teasdall R: The mechanical integrity of healed diaphyseal bone defects grafted with calcium hydroxyapatite/calcium triphosphate ceramic in a new animal model. *Clinical Materials*, 6: 251, 1990
19. Nolan PC, Nicholas RM, Mulholland BJ, Mollan RAB, Wilson DJ: Culture of human osteoblasts on demineralized human bone. *J Bone Joint Surg*, 74-B: 284, 1992
20. Salyer KE, Gendler E, Menendez JL, Simon TR, Kelly KM, Bardach J: Demineralized perforated bone implants in craniofacial surgery. *J Craniofac. Surg*, 3: 55, 1992

Yazışma Adresi: Dr. Ümit Kıymet AKAL
Ankara University, Faculty of Dentistry
Dep of Oral and Maxillofacial Surgery
06500 Beşevler, ANKARA-TURKEY
umakal68@mynet.com

*This study was presented as an oral presentation in 15 th International Conference on Oral and Maxillofacial Surgery, Durban, South Africa, 19-24 May 2001