

A Long Survived Pediatric Patient with Recurrent Anaplastic Ependymoma: A Case Report and Review of the Literature

Uzun Saękalımı Olan Nüks Anaplastik Ependimomalı Çocuk Hasta: Olgu Sunumu ve Literatürün Gözden Geçirilmesi

Yasemin BENDERLİ CİHAN,^a
Kemal DENİZ,^b
Halil DÖNMEZ^c

^aDepartment of Radiation Oncology,
Kayseri Training and Research Hospital,
Departments of

^bPathology,

^cRadiology,
Erciyes University Faculty of Medicine,
Kayseri

Geliş Tarihi/Received: 26.11.2010
Kabul Tarihi/Accepted: 23.03.2011

Yazışma Adresi/Correspondence:
Yasemin BENDERLİ CİHAN
Kayseri Training and Research Hospital,
Department of Radiation Oncology,
Kayseri,
TÜRKİYE/TURKEY
cihany@erciyes.edu.tr

ABSTRACT Ependymoma is the third most common brain tumor in the childhood, following astrocytoma and medulloblastoma. Ependymoma represents 6-10% of all brain tumors in the pediatric age group. Commonly surgery is the first treatment option. Adjuvant radiotherapy and/or chemotherapy are performed according to age and clinical manifestations of the patients. The extent of tumor resection and control of local recurrence are the primary factors affecting the treatment outcome. Researches demonstrated that 80-95% of deaths are attributed to tumor progression at the primary site. A male pediatric patient suffering from multiple recurrences of ependymoma with anaplastic transformation is presented here. We suggest that the combination of surgery, adjuvant radiotherapy and chemotherapy is highly effective for controlling recurrent ependymoma.

Key Words: Ependymoma; brain neoplasms; surgery; chemotherapy, adjuvant; radiotherapy

ÖZET Ependimoma, pediatrik beyin tümörleri içinde medulloblastoma ve astrositomadan sonra üçüncü sırada yer alır. Tüm çocukluk çaęı beyin tümörlerinin %6-10'unu oluşturur. Tedavide ilk tercih sıklıkla cerrahidir. Adjuvan radyoterapi ve/veya kemoterapi hastanın yaşı ve klinik özelliklerine göre değerlendirmeye alınır. Tümör kitlesinin geniş eksizyonu ve lokal nüksün önlenmesi klinik gidişi etkileyen en önemli faktörlerdir. Çalışmalar ölüm nedeninin %80-95 oranında primer tümörün ilerlemesine baęlı olduğunu göstermiştir. Bu yazıda, anaplastik transformasyonla multipl nüks gösteren ependimoma tanılı erkek çocuk hasta sunuldu. Cerrahi, adjuvan radyoterapi ve kemoterapi kombinasyonunun ependimoma nüksünün kontrolünde oldukça etkili olduğu görülmüştür.

Anahtar Kelimeler: Ependimoma; beyin neoplazileri; cerrahi; kemoterapi, adjuvan; radyoterapi

Türkiye Klinikleri J Pediatr 2012;21(2):96-101

Ependymomas are the third most common brain tumors following astrocytomas and medulloblastomas in the childhood, and half of the cases occur before age five. Ependymomas account for approximately 6-10% of childhood brain tumors and 2-5% of all brain tumors.¹⁻⁵ These tumors generally originate from the ventricular floor. They can occur in supratentorial compartment, posterior fossa and spinal cord locations. In approximately 75% of childhood cases, they are situated below the tentorium. Supratentorial ependymomas are mostly resectable and found more often to have high grade compared to infratentorial ependymomas where total resection is more unlikely.⁴⁻⁶

The biologic behavior of ependymomas is highly variable. The classification, prognostic factors and therapeutic modalities of this tumor remain controversial. Since diagnostic procedures and therapies have been changing over time and cases distributed over a long time period, they can not therefore be compared.^{2,4,5,7,8}

Commonly, surgery is the first treatment option for ependymomas and the extent of tumor resection is associated with long-term survival.^{3,6,8,9} Adjuvant therapy such as radiotherapy (RT) and/or chemotherapy is performed according to age and clinical manifestations of the patients.^{6,8-13} The extent of tumor resection and the control of local recurrence are the primary factors affecting the treatment outcome. Researches demonstrated that 80-95% of ependymoma deaths are attributed to tumor progression at the primary site.^{5,6,13-15} We presented here a male pediatric patient with supratentorial ependymoma who suffered from multiple tumor recurrences. He was treated with repeated surgical resections, deferred RT and chemotherapy. In spite of anaplastic transformation of the tumor the patient survived 14 years after disease detection without major neurological deficits.

CASE REPORT

In 1997, a 28 month-old male patient presenting episodes of partial seizures was referred to emergency department. Disequilibrium had started four weeks earlier. His cranial nerves neurological examination was normal. A cranial computed tomogram (CT) demonstrated an enhancing mass in the right region of temporo-parietal lobe. The patient underwent a total excision of intracranial lesion (first operation). The histopathological analysis of the tumor specimen demonstrated ependymoma [World Health Organization (WHO) grade II, Figure 1]. Ten months later, cranial CT showed regrowth of the tumor. The tumor was removed by subtotal resection (second operation). An identical WHO grade II ependymoma was reported. Spinal magnetic resonance imaging (MRI) and cytologic evaluation of the cerebral fluid were normal. Postoperatively, the patient underwent conventional RT with a large field dose of 180 cGy x 25 fractions and a boost dose of 180

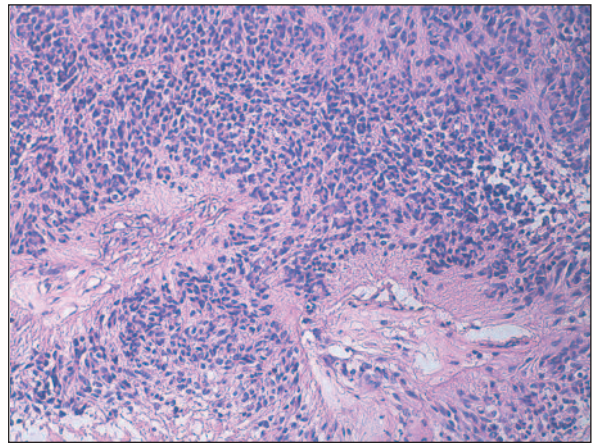


FIGURE 1: Histopathological examination of the first lesion confirmed the diagnosis of ependymoma (WHO grade II; Hematoxylin-eosin, original magnification x200).

(See for colored form <http://pediatri.turkiyeklinikleri.com/>)

cGy x 3 fractions to the residual tumor, the total dose being 5040 cGy according to patient's age. After RT, 8 cycles of chemotherapy consisting of vincristine, lomustine, cyclophosphamide and procarbazine were administered every 4 weeks. After adjuvant therapies, the patient had a complete response on control MRI. The patient had been closely followed with MRI scans.

He stayed symptom-free with no evidence of tumor for 60 months until he developed local recurrence. Then another, subtotal tumor excision was performed (third operation). Histopathological examination of the lesion demonstrated this time a transformation of the tumor to an anaplastic ependymoma (WHO, grade III, Figure 2). By light microscopy, all examined tumors were characterized by perivascular pseudoresette formation, mitosis and massive calcifications. Immunohistochemical examination demonstrated poorly stained areas with glial fibrillary acidic protein (GFAP), focal areas retaining epithelial membrane antigen (EMA) and synaptophysin chromogranin dyes. Ki-67 staining index was 2-3%. Spinal MRI and lumbar puncture did not show any evidence of tumor dissemination. The patient was followed by MRI every 3 months thereafter.

Nine months later, he developed another local recurrence with hydrocephalus, a ventriculoperitoneal (VP) shunt operation with subtotal excision

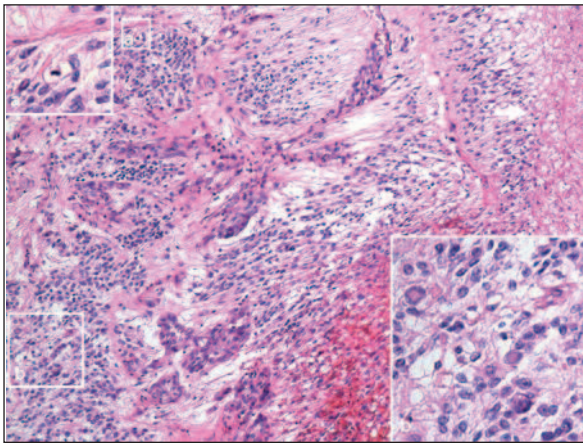


FIGURE 2: Photomicrographs of the recurrent lesion showing perivascular pseudorosette formations, mitoses, and calcifications (WHO grade III, Hematoxylin-eosin, original magnification x200).

(See for colored form <http://pediatri.turkiyeklinikleri.com/>)

of the lesion was performed (fourth operation). Post-operatively, the patient received 4 cycles of Vincristine followed by a second course of conventional RT to residual tumor, with a total dose of 2160 cGy (180 cGyx12 fractions) considering former irradiation. Tumor regrowth was detected in the follow-up images 48 months after the fourth operation. Tumor was dissected totally (fifth operation). Twenty months later, he developed locoregional recurrence with disseminated tumor nodules in the right temporoparietal lobes accompanied by hydrocephalus (Figure 3). Another VP shunt operation with subtotal tumor excision was performed again (sixth operation). The surgical samples showed evidence of tumor recurrence. The BOS cytology revealed normal results. MRI did not

show dissemination in central nervous system out of the right temporoparietal lobes and no metastases was detected to extracranial organs on CT scans. He did not have serious neurological morbidity except behavioral problems at last follow-up. Fourteen years from diagnosis the patient died of primary tumor progression.

DISCUSSION

Ependymomas are found mostly less than 5 years of age and the median age at diagnosis is 3 to 4 years. The tumor is slightly more common in boys. Younger children have less favorable outcome, particularly in posterior fossa and spinal locations.¹⁻³ The World Health Organization (WHO 2000 criteria) classifies ependymomas into 4 groups based on histologic appearance: subependymoma (WHO grade I); myxopapillary ependymoma (WHO grade I); ependymoma with cellular, papillary and clear cell variants (WHO grade II); and anaplastic ependymomas (WHO grade III). Low-grade ependymoma is more common than high-grade ependymoma. Low-grade ependymoma tends to occur in infratentorial regions whereas anaplastic ependymoma arises in the cerebral hemisphere. Low-grade and anaplastic ependymomas are both clinically aggressive tumors in general.^{6,11,15-17}

Low-grade ependymomas are histologically characterized by perivascular pseudorosettes. The anaplastic ependymomas define ependymal tumors which showing increased mitotic activity and cellularity, often accompanied by perivascular pseudorosette formation and massive calcifica-

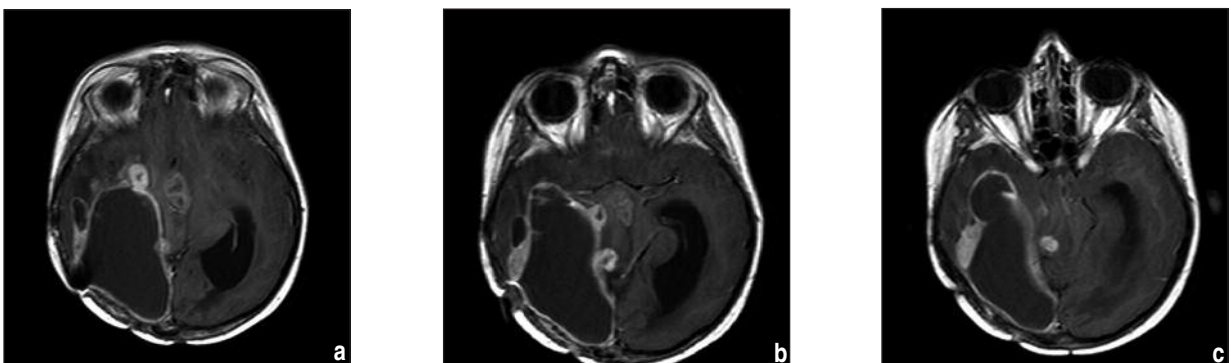


FIGURE 3: Contrast enhanced axial T1 weighted images showing disseminated tumor nodules in the right temporoparietal lobes.

tions.^{6,7,11} In our case, the first and second operations samples showed a grade II ependymoma; whereas samples of subsequent operations demonstrated anaplastic ependymoma. This transformation occurred 60 months following the second operation and adjuvant radio-chemotherapy.

Ependymoma is usually presenting in infancy with clinical symptoms of nonspecific nature including vomiting, irritability, lethargy, macrocephaly, failure to thrive and macrocephaly. Older children may better communicate specific neurologic deficits such as headache and nausea. Vomiting is particularly seen upon awakening in the morning.^{1,2,6} Diagnosis is possible in the most cases if the image findings are carefully examined together with the patient's age and the specific location of the tumor. On CT scan and MRI, the ependymomas appeared as well-defined ventricular masses. The incidence of dissemination of ependymoma is only 11% to 17%. It is important to demonstrate its presence or absence, because disseminated disease is a strong adverse prognostic factor. Accordingly, it is preferable to perform a preliminary staging spinal MRI.^{4,8-10,14}

Complete surgical resection is considered as the most beneficial treatment choice for ependymomas.^{3,6,8-13} Aggressive surgery with the goal of achieving complete resection is one key to long-term survival in children. Complete resection is accomplished in 40-70% of cases at the initial exploration and is more frequently obtained in supratentorial tumors rather than infratentorial tumors. Generally, supratentorial tumors have a more favorable outcome and better long-term results due to their benign biological behavior and complete surgical excision is the treatment of choice.^{1-3,6,9-13} In the retrospective series, the 5-year progression-free survival rate for patients with negative postoperative imaging was 51-100%, and in contrary for patients with residual disease after surgery it was only 30-50%.⁹⁻¹² In the Italian prospective AIEOP study, 5-year overall survival rate for totally resected patients was 81%, and for incompletely resected patients it was 61%.¹³

Intracranial ependymomas are relatively radiosensitive. Craniospinal axis fields are used only

when spinal seeding is radiologically and pathologically evident. In young children (less than 5 years of age) the provision of RT is usually avoided, if possible. Because of the severity of this disease, however, even young children with these tumors usually require chemotherapy and RT.¹⁻¹⁰

Adjuvant RT improves upon the results of surgery alone in low-risk patients i.e. patients greater than 3 years of age at presentation with no preoperative craniospinal metastases, no high-grade pathological features, and no imaging evidence of residual disease. Contrary to this, some researchers have advocated a strategy of deferring adjuvant RT and repeat surgery, if necessary, for recurrences.¹⁶ This strategy can save children who would not recur from RT and also postpone the age of RT for whom recurrent disease would occur.

Currently, postoperative RT is considered to be the standard approach for patients with ependymoma. Radiotherapy is, however, indicated following subtotal resection and has been shown to improve progression-free disease survival and provide long term disease control. Since the use of postoperative RT, the survival rate has improved from 20% to 60%. Adjuvant RT is considered by many authors to be a standard practice, even in patients with no residual disease.^{4,6-9,12,15} The dose of radiation for the treatment of ependymoma has traditionally been in the range of 45 Gy to 54 Gy. Patients after gross total resection of their tumor and local radiotherapy achieve a 60-89% 5-year overall survival, compared with 21-46% 5-year overall survival for patients treated with incomplete resections and RT.³ Verstegen et al. researched patients with anaplastic ependymomas and compared patients with surgery alone and surgery with postoperative RT. They showed that postoperative RT was effective on survival than surgery alone.¹⁷

The role of adjuvant chemotherapy has not been well defined, and has been discussed widely because of the limited number of cases and the relatively short-term follow-up. Chemotherapy indications are usually for recurrent tumors and in younger children (to substitute for or delay RT) or patients in whom surgery and RT have failed to con-

control tumor growth. Additionally, adjuvant chemotherapy does not significantly improve ependymoma clinical outcome.^{2,4,8,10,18} Timmermann et al. evaluated the combined postoperative RT and chemotherapy for anaplastic ependymomas. They showed that chemotherapy has no effect on survival.⁸ However, Needle et al. reported a survival benefit for adjuvant chemotherapy with hyperfractionated RT.¹⁸

There are numerous prognostic factors that can predict the outcome such as age, sex, clinical presentation, tumor location, histological criteria, extent of surgical resection (subtotal or gross total), administration of adjuvant chemotherapy, radiation strategy so on. Location, histological grading and radical excision seem to be the most important factors. As can be expected, high grade anaplastic ependymoma carries poorer prognosis than low-grade. Status of the tumor and some immunohistochemical variables has been intensively examined and some of them have been found to be the strong predictors of ependymoma recurrence.^{2,6,12,14,16}

Unless a complete removal of the tumor can be accomplished, ependymoma almost always progresses. The challenge in ependymoma treatment is local control, since the most common pattern of failure is an isolated local relapse, as seen in our patient. Retrospective series have shown a probability of recurrence after 5 years of 50%, with the majority of treatment failures occurring at the site of the primary disease.^{4,7,9} Ross et al. studied 15 cases of anaplastic ependymomas and found a 58% 5 year survival.¹⁵

For patients who relapse, surgical resectability is usually the first modality to be explored. Although it is very difficult to prove that complete

surgical resection of the relapsed ependymoma can lead to statistically significant overall survival advantage. Although multiple operations are not common for ependymoma, surgery with VP shunt may tend to add a risk for tumor seeding and metastases.^{4,7,9,10,12,15}

Our patient's clinical course confirms the importance of control of local recurrence in patients with ependymoma. Surgical and adjuvant treatments (RT and/or chemotherapy) are imperative for the control of the tumor, even in patients with local recurrence. A long term disease control is seen in our patient with recurrent disease. We had advocated a strategy of deferring adjuvant RT in first surgery. At the first local recurrence, adjuvant chemotherapy and RT were administered. These therapies resulted in 60 months of tumor remission, but then the patient developed local recurrence on more time with a transformation to a higher grade. Each recurrence required surgical removal of the tumor.

CONCLUSION

Our patient disease course suggests that intracranial ependymoma could have locally aggressive and progressive biological behavior in childhood. Ependymoma represents a disease where surgical resection is the most important modality, even for relapsed disease. Adjuvant RT and chemotherapy are currently the best available options to improve local control and have favorable impact on survival.

Acknowledgements

The child's parents gave their written consent to the study.

REFERENCES

1. Reni M, Gatta G, Mazza E, Vecht C. Ependymoma. *Crit Rev Oncol Hematol* 2007;63(1): 81-9.
2. Agaoglu FY, Ayan I, Dizdar Y, Kebudi R, Gorgun O, Darendeliler E. Ependymal tumors in childhood. *Pediatr Blood Cancer* 2005;45(3): 298-303.
3. Zacharoulis S, Moreno L. Ependymoma: an update. *J Child Neurol* 2009;24(11):1431-8.
4. Smyth MD, Horn BN, Russo C, Berger MS. Intracranial ependymomas of childhood: current management strategies. *Pediatr Neurosurg* 2000;33(3):138-50.
5. Afra D, Müller W, Slowik F, Wilcke O, Budka H, Turoczy L. Supratentorial lobar ependymomas: reports on the grading and survival periods in 80 cases, including 46 recurrences. *Acta Neurochir (Wien)* 1983;69(3-4): 243-51.
6. Kinoshita M, Izumoto S, Kagawa N, Hashimoto N, Maruno M, Yoshimine T. Long-term control of recurrent anaplastic ependymoma with extracranial metastasis: importance of multiple surgery and stereotactic radiosurgery procedures--case report. *Neur Med Chir (Tokyo)* 2004;44(12):669-73.

7. Louis DN, Canevee WK, Ohgaki H, Wiestler OD. WHO Classification of Tumors of the Central Nervous System. 4th ed. Lyon: International Agency for Research on Cancer; 2007. p.309.
8. Timmermann B, Kortmann RD, Kühl J, Meisner C, Slavic I, Pietsch T, et al. Combined postoperative irradiation and chemotherapy for anaplastic ependymomas in childhood: results of the German prospective trials HIT 88/89 and HIT 91. *Int J Radiat Oncol Biol Phys* 2000;46(2):287-95.
9. Palma L, Celli P, Mariottini A, Zalaffi A, Schettini G. The importance of surgery in supratentorial ependymomas. Long-term survival in a series of 23 cases. *Childs Nerv Syst* 2000;16(3):170-5.
10. Robertson PL, Zeltzer PM, Boyett JM, Rorke LB, Allen JC, Geyer JR, et al. Survival and prognostic factors following radiation therapy and chemotherapy for ependymomas in children: a report of the Children's Cancer Group. *J Neurosurg* 1998;88(4):695-703.
11. Mansur DB, Perry A, Rajaram V, Michalski JM, Park TS, Leonard JR, et al. Postoperative radiation therapy for grade II and III intracranial ependymoma. *Int J Radiat Oncol Biol Phys* 2005;61(2):387-91.
12. Rousseau P, Habrand JL, Sarrazin D, Kalifa C, Terrier-Lacombe MJ, Rekeciewicz C, et al. Treatment of intracranial ependymomas of children: review of a 15-year experience. *Int J Radiat Oncol Biol Phys* 1994;28(2):381-6.
13. Massimino M, Giangaspero F, Garrè ML, Genitori L, Perilongo G, Collini P, et al.; AIEOP Neuro-Oncology Group. Salvage treatment for childhood ependymoma after surgery only: Pitfalls of omitting "at once" adjuvant treatment. *Int J Radiat Oncol Biol Phys* 2006;65(5):1440-5.
14. Paulino AC, Wen BC, Buatti JM, Hussey DH, Zhen WK, Mayr NA, et al. Intracranial ependymomas: an analysis of prognostic factors and patterns of failure. *Am J Clin Oncol* 2002;25(2):117-22.
15. Ross GW, Rubinstein LJ. Lack of histopathological correlation of malignant ependymomas with postoperative survival. *J Neurosurg* 1989;70(1):31-6.
16. Little AS, Sheehan T, Manoharan R, Darbar A, Teo C. The management of completely resected childhood intracranial ependymoma: the argument for observation only. *Childs Nerv Syst* 2009;25(3):281-4.
17. Versteegen MJ, Leenstra DT, Ijst-Keizers H, Bosch DA. Proliferation- and apoptosis-related proteins in intracranial ependymomas: an immunohistochemical analysis. *J Neurooncol* 2002;56(1):21-8.
18. Needle MN, Goldwein JW, Grass J, Cnaan A, Bergman I, Molloy P, et al. Adjuvant chemotherapy for the treatment of intracranial ependymoma of childhood. *Cancer* 1997;80(2): 341-7.