

Double Tracheal Stenosis: Case Report and Review of Literature

Çift Trakeal Stenoz: Olgu Sunumu ve Literatürün Gözden Geçirilmesi

Hale ASLAN,^a
Mehmet Sinan BAŞOĞLU,^a
Murat SONGU,^a
Sedat ÖZTÜRKAN,^a
Hüseyin KATILMIŞ^a

^aDepartment of Otorhinolaryngology,
İzmir Kâtip Çelebi University
Faculty of Medicine, İzmir

Geliş Tarihi/Received: 25.04.2013
Kabul Tarihi/Accepted: 29.12.2013

*The article was presented in meeting of
"Xth International Ear Nose Throat and Head
Neck Surgery" 1-4 June 2000, Ankara.*

Yazışma Adresi/Correspondence:
Hale ASLAN
İzmir Kâtip Çelebi University
Faculty of Medicine,
Department of Otorhinolaryngology,
İzmir,
TÜRKİYE/TURKEY
drhaleaslan@gmail.com

ABSTRACT The most common cause of laryngotracheal stenosis is long-term intubation in intensive care units. The patients that suffer dyspnea after being discharged from the intensive care unit, are often mistakenly diagnosed with asthma initially and are diagnosed with tracheal stenosis only after further examination. Rarely, some cases are idiopathic. Here, we present a patient who was diagnosed with asthma mistakenly because of progressive dyspnea which lasted for a long time. A detailed examination revealed stenosis in glottis of larynx and thoracic segments of the trachea. Segmental tracheal resection with end-to-end anastomosis was performed on distal tracheal stenosis, followed by a total cricoidectomy, thyrotracheal anastomosis and temporary T-tube insertion on glottic involvement subglottic stenosis. The patient was discharged home and followed as an out-patient.

Key Words: Idiopathic subglottic tracheal stenosis; stents

ÖZET Laringotrakeal stenozların en yaygın nedeni yoğun bakım ünitelerinde uzun süreli entubasyondur. Bu hastalar yoğun bakımdan çıktıktan sonra dispne şikâyeti çekerler ve başlangıçta bunlara yanlışlıkla astım tanısı konur. İleri araştırmalar sonucunda trakeal stenoz tanısı alırlar. Nadiren bazı hastalar idiyopatikdir. Biz makalemizde uzun zamandır devamlı ve artan dispne şikayeti olan ve bu nedenle yanlışlıkla astım tanısı konan hastamızı sunuyoruz. Detaylı araştırma sonunda larenkste subglottik ve glottik bölgede, trakeanın torasik segmentinde stenoz olduğu ortaya çıktı. Distaldeki stenoza segmental trakeal rezeksiyon ve uç uca anastomoz uygulandı. Takiben glottik yayımlı subglottik stenoza ise total krikoidektomi, tirotrakeal anastomoz ve geçici bir süre için T tüp uygulandı. Hasta taburcu edildi ve takibimize alındı.

Anahtar Kelimeler: İdyopatik subglottik trakeal stenozis; stentler

Türkiye Klinikleri J Case Rep 2015;23(1):58-62

Laryngotracheal stenosis is a congenital or acquired narrowing of the airway representing a continuum of disease that may affect the glottis, subglottis, and trachea. Congenital stenosis is generally caused by pathological tracheal rings with an absent, or nearly absent. Acquired lesions are frequently caused by endotracheal intubation, long-term tracheostomies, airway burns, trauma, and some systemic diseases.¹ Rarely, patients are diagnosed with narrowing of the subglottic larynx or trachea owing to fibrous stenosis in the absence of known prior infection, neoplasm, trauma, intubation, vasculitis, or relapsing polychondritis. These cases are

doi: 10.5336/caserep.2013-35888

Copyright © 2015 by Türkiye Klinikleri

classified as idiopathic tracheal stenosis. Idiopathic laryngotracheal stenosis is usually seen in middle-aged women.²

Here, we present a case of double tracheal stenosis involving idiopathic and traumatic components, which was mistakenly treated as asthma for a good number of years.

CASE REPORT

A 50 year old woman visited a hospital complaining of a continues dyspnea that had lasted for three years. She had never suffered intubation or any trauma that could lead to stenosis. Due to misdiagnosis, she had been taking various medication for asthma bronchial. There wasn't any problem for the purposes of systemic disease. From the results of the hematological examinations, sedimentation (60 min) 49 milimeter, antineutrophilic cytoplasmic antibody (ANCA), antinuclear antibody (ANA) and rhomatoid factor are negative and also allergic tests are negative . On recent examination, she didn't have astma bronchial clinically. Consequently she was diagnosed to be idiopathic tracheal stenosis..

On computed tomography image, the rima glottis was closed in the midline, the arytenoids and vocal cords were paralysed bilaterally, and the anteroposterior lengths of the true and false vocal folds were shortened (Figure 1).

Multiplanar reconstructive computed tomography (CT) revealed total destruction of the cricoid cartilage leading to fusion of the anterior and pos-

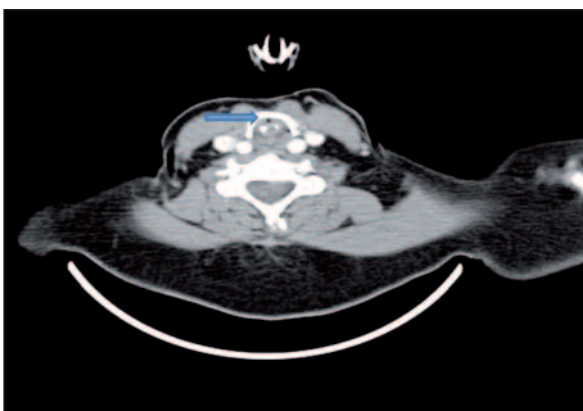


FIGURE 1: Computed tomography image of the rima glottis.

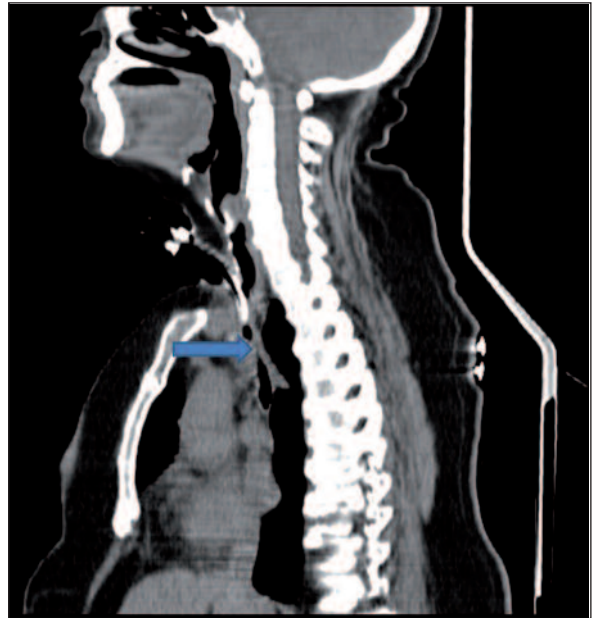

FIGURE 2: Computed tomography image of stenosis located at the front wall of the trachea below the tracheotomy line (blue line).

terior laminae. Tracheal lumen was totally obstructed by the destroyed cricoid laminae (Myer-Cotton grade 4). In addition, there was a 2-cm-long stenotic segment below the tracheotomy line at the anterior wall of the trachea, most probably caused by tracheotomy tube irritation; in this plane, the anteroposterior diameter of the trachea was 5 mm (Myer-Cotton grade 2) (Figure 2).

Two-stage surgery was planned for the patient. For the traumatic acquired stenosis, following a right thoracotomy, the length of 2 cm with stenotic segment was resected and an end-to-end anastomosis was performed. Postoperatively, chylothorax occurred and the patient was treated in the intensive care unit (ICU) for nine days. When her general condition improved, she underwent the second surgery for her idiopathic acquired glottic stenosis six weeks after the first procedure. After making an apron flap incision, the larynx and trachea were explored. A temporal laryngofissure was created after incising the cricothyroid membrane. A vertical incision was made to the destroyed cricoid cartilage. A total cricoidectomy was performed in the subperichondrial plane to preserve the recurrent laryngeal nerve and oesophageal mucosa. The height of the destructed cricoid specimen was 10 mm and the

width was 13 mm. The front and back laminae were irregular as fused with each other, having no lumen between them. To reduce the tension before the anastomosis suprahyoid release was performed. To support the arytenoid cartilages and lumen of the subglottis a Montgomery T-tube was inserted with its upper end 0.5 cm above the arytenoid cartilages and the bottom end containing the former anastomosis line. The first tracheal ring was sutured to the thyroid cartilage and the laryngotracheal anastomosis was completed. In both anastomosis operation, the trachea was released from the back and the front sides but not laterally so as to avoid the disruption of tracheal blood flow. The specimen of all operations were sent to the department of pathology. The pathologist reported the specimens as cartilage tissues showing degenerative process. One month postoperatively, the airway was assessed using multiplanar reconstructive CT (Figure 3).

Two months later, we shortened the external limb of the T-tube and buried it subcutaneously to prevent contamination and to make it easier for the patient to readapt to social life. We decided to support the glottic area in the patient with T tube temporarily for 18 months and at the end of the 18 months, the T tube will be removed. At control examination, six months after her discharge with T-tube, she continues to be free of dyspnea and exercise intolerance.

DISCUSSION

Oral or nasal endotracheal tubes or tracheostomy tubes are most commonly used to deliver mechanical ventilatory support in respiratory failure. De-

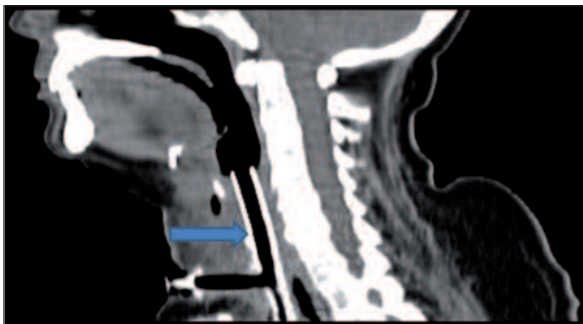


FIGURE 3: Computed tomography image of the patient one month after the T-tube insertion.

spite the improvements of technological conditions in ICUs, acquired tracheal stenosis still constitute an important group of iatrogenic sequelae after intubation and tracheostomy. About 2-3% tracheal stenosis occurs by intubation or tracheotomy.^{3,4} Laryngotracheal stenosis may be due to relapsing polychondritis. These patients also have auricular or nasal chondritis and scleritis.⁵ Also in inflammatory bowel diseases may be respiratory involvement, including upper airway stenosis, bronchitis, and chronic bronchiolitis, interstitial lung disease, necrotic parenchymal nodules and serositis.⁶ Our case has no history of intubation and we did not find any predisposing factor and additional symptoms after systemic examination.

In children chronic persistent virus-bacterial inflammation of respiratory tract mucosa results into hypersensitivity of airways and stenosing laryngotracheitis.⁷ This mechanism may have developed in our patient during childhood. There was no evidence of this. Consequently, she was diagnosed of idiopathic tracheal stenosis.

Laryngotracheal reconstruction plans are dependent on preoperative evaluations which can change significantly during the surgical procedure. Therefore, experienced physicians who can alter the preoperative plan immediately during the procedure and successfully perform an alternative procedure are necessary.⁸ The symptoms include progressive dyspnea, wheezing, and hoarseness. The symptoms progress over an average of two years and the patients are mistakenly treated for chronic obstructive pulmonary disease or asthma.² Our reported case showed also similar symptoms and was treated with medication for asthma for long years but when the medications were insufficient in the last terms it was needful that tracheotomy.

Infrequently, tracheal stenosis may occur both in the subglottic area and below the tracheotomy line; this is called double stenosis. Kara et al. reported double stenosis located at both the tracheotomy level and distally due to the cuff pressure after mechanical ventilation; they treated their patient with tracheal resection and end-to-end anas-

tomosis to the stomal stenosis and placing a stent to the distal stenosis.⁹ Sarper et al. treated 45 tracheal stenosis patients and reported double tracheal stenosis in two. The stenotic segments were located at the tracheotomy level and the front wall of the distal trachea in both patients and were treated with two different anastomoses in the same session.³

End to end anastomosis could be performed in tracheal stenosis having 1cm to 5 cm vertical length and causing total obstruction. After stenotic segment excision the end to end anastomosis should be performed following tracheal and laryngeal release. 3 to 5 cm defects could be reconstructed by end to end anastomosis following laryngotracheal release.⁹ The servical trachea is fed by superior and inferior thyroid arteries and the thoracic trachea is fed by bronchial vessels. The tracheal vessels enters the trachea from lateral wall and forms the longitudinal and transvers intercartilaginous vessels.¹⁰ During the tracheal surgeries, to prevent the feeding, the trachea should be released in anteroposterior sides. Pretracheal release which is performed with preventing the lateral blood supply, increases the mobilization of the airway at a big rate and should be performed in every patients. The lateral dissection should be limited as 1-2 cm above and below the insicion line.¹¹ Stenotic areas in our case were too distant and the arterial blood was coming from two different supplies so we didn't observe any feeding problem due to double anastomosis at the trachea. Total excised stenotic segment length was about 3 cm and tracheaolaryngeal release.

Some reports suggested that tracheal defects of 2 cm or less can be successfully managed by primary anastomosis alone without laryngeal release techniques.^{9,12} Merati et al. reported a 94% success rate in 17 tracheal segmental resections ranging from 1 to 4 cm without adjunctive laryngeal release.¹³

The treatment is difficult if the subglottic stenosis also includes the vocal cords. This is mostly caused by interarytenoidal scar tissue in the posterior glottis and ankylosis in the cricoarytenoid joint occurring after the endotracheal tube damages the cricoid cartilage.¹³ In 1992, Maddaus et al. performed laryngofissure, excised the interarytenoidal

scar tissue, and placed a T-tube to prevent the vocal cords from closing in the patients with subglottic stenosis with glottic involvement.¹⁴ Couraud et al. also performed laryngofissure, and excised destroyed cricoid cartilage. They applied a T-tube to glottis and subglottis for six months to prevent laryngeal collapse.¹⁵ In recent study, Yamamoto et al. suggested that, 6 months of T-tube placement is probably sufficient after total cricoidectomy by glottic involvement subglottic stenosis in the canine model.¹⁶

In reality, tracheal resection and anastomosis is considered the treatment of choice for tracheal stenosis. However, in cases where longer stenosis, cardiac or additional airway problems exist and stenosis involve glottis/subglottis tracheal stents are a plausible means of providing a permanent or temporary airway opening. T-tube removal time varies according to the surgeon's decision, severity of the lesion, and problems relating to control and adaptation of the patient. Gaissert et al. applied T-tubes to 16 patients and left them in place for 20 months.¹⁷ Morshed et al. left T-tubes in place for 3-60 months.¹⁸ In our case the stenosis was showing subglottic extension so we also used Montgomery T-tube to provide the airway and will be removed at the end of the 18 months to support the glottic area. We shortened the external limb of the T-tube and buried it subcutaneously to reduce contamination and enable the patient to readapt to social life within postoperative 2 months. We performed this method on 5 patients in our clinic. In postoperative two days, tracheal secretions were deposited under the skin. This complication was treated with drainage and daily dressings. We didn't observe stent obstruction by crusts and infection. This manoeuvre was first described in 1987 by Keszler. Cooper et al. performed it in 47 patients and reported satisfactory results.¹⁹

Double tracheal stenoses are rarely reported at the literature. Total cricoidectomy because of the total destruction of the cricoid cartilage is also rare. Here we presented a case of idiopathic and acquired laryngotracheal stenosis and our treatment modality with literature.

REFERENCES

1. Bhalla M, Grillo HC, McCloud TC, Shepard JO, Weber AL, Mark EJ. Idiopathic laryngotracheal stenosis: radiologic findings. *AJR Am J Roentgenol* 1993;161(3):515-7.
2. Grillo HC, Mathisen DJ, Wain JC. Laryngotracheal resection and reconstruction for subglottic stenosis. *Ann Thorac Surg* 1992;53(1):54-63.
3. Sarper A, Ayten A, Eser I, Ozbudak O, Demircan A. Tracheal stenosis after tracheostomy or intubation: review with special regard to cause and management. *Tex Heart Inst J* 2005;32(2):154-8.
4. Gaillard J, Haguenaer JP, Guerrier B. [Cervical tracheal surgery]. In: Portman M, Guerrier Y, eds. *Cervicofacial Surgical Techniques in Otorhinolaryngology*. 2nd ed. Paris: Masson; 1987. p.349-72.
5. Chang SJ, Lu CC, Chung YM, Lee SS, Chou CT, Huang DF. Laryngotracheal involvement as the initial manifestation of relapsing polychondritis. *J Chin Med Assoc* 2005;68(6):279-82.
6. Rickli H, Fretz C, Hoffman M, Walsler A, Knoblauch A. Severe inflammatory upper airway stenosis in ulcerative colitis. *Eur Respir J* 1994;7(10):1899-902.
7. Orlova SN, Ryvkin AI, Pobedinskaja NS. [Some mechanisms of a recurrent course of stenosing laryngotracheitis in children]. *Vestn Otorinolaringol* 2007;(2):16-9.
8. Cansiz H, Yener M, Tahamiler R, Pamukcu M, Acar GO, Sekercioglu N. Preoperative detection and management of tracheomalacia in advanced laryngotracheal stenosis. *B-ENT* 2008;4(3):163-7.
9. Kara M, Halezeroğlu S. Double tracheal stenosis. *Eur J Cardiothorac Surg* 2012;41(6):1400-1.
10. Montgomery WW. Suprahyoid release for tracheal anastomosis. *Arch Otolaryngol* 1974;99(4):255-60.
11. Cauldwell EW, Siekert RG, Linninger RE, Anson BJ. The bronchial arteries; an anatomic study of 150 human cadavers. *Surg Gynecol Obstet* 1948;86(4):395-412.
12. Grillo HC. Carinal reconstruction. *Ann Thorac Surg* 1982;34(4):356-73.
13. Merati AL, Rieder AA, Patel N, Park DL, Girod D. Does successful segmental tracheal resection require releasing maneuvers? *Otolaryngol Head Neck Surg* 2005;133(3):372-6.
14. Maddaus MA, Toth JL, Gullane PJ, Pearson FG. Subglottic tracheal resection and synchronous laryngeal reconstruction. *J Thorac Cardiovasc Surg* 1992;104(5):1443-50.
15. Couraud L, Jougon JB, Velly JF. Surgical treatment of nontumoral stenoses of the upper airway. *Ann Thorac Surg* 1995;60(2):250-9; discussion 259-60.
16. Yamamoto K, Honda M, Yamamoto T, Nakamura T. Healing process after total cricoidec-tomy and laryngotracheal reconstruction: endoscopic and histologic evaluation in a canine model. *J Thorac Cardiovasc Surg* 2013;145(3):847-53.
17. Maniglia AJ. Tracheal stenosis: conservative surgery as a primary mode of management. *Otolaryngol Clin North Am* 1979;12(4):877-92.
18. Morshed K, Szymański M, Golabek W. [The use of tracheostomy T-tube in the treatment of tracheal stenosis]. *Otolaryngol Pol* 2005;59(3):361-4.
19. Cooper JD, Pearson FG, Patterson GA, Todd TR, Ginsberg RJ, Goldberg M, et al. Use of silicone stents in the management of airway problems. *Ann Thorac Surg* 1989;47(3):371-8.