

Potential Trapping Lesion of the Parotid Gland (Multi-Nodular Oncocytic Hyperplasia): Case Report

Parotis Bezinin Potansiyel Tuzak Lezyonu (Multi-Nodüler Onkositik Hiperplazi)

Çağlar SARIGÜL,^a
Enver VARDAR,^a
Tulu KEBAT,^a
Birgül ÇİFTÇİ,^a
Tolgahan ÇATLI^b

Clinics of
^aPathology,
^bEar, Nose and Throat,
İzmir Bozyaka Training and
Research Hospital, İzmir

Geliş Tarihi/Received: 13.04.2014
Kabul Tarihi/Accepted: 19.09.2014

Yazışma Adresi/Correspondence:
Enver VARDAR
İzmir Bozyaka Training and
Research Hospital,
Department of Pathology, İzmir,
TÜRKİYE/TURKEY
vardaren@gmail.com

ABSTRACT Oncocytic lesions rarely affect the parotid gland, accounting for less than 1% of all salivary lesions. Oncocytosis is the accumulation and proliferation of oncocytes in salivary glands in nodular or diffuse pattern. Multifocal nodular oncocytic hyperplasia of the salivary gland represents an extremely rare, non-tumorous pathology of the salivary gland. We report a case of multifocal oncocytic hyperplasia of the parotid gland in a 38-year-old man who was referred for a right preauricular mass that had gradually increased in size over the last 2 months. The differential diagnosis in addition to histopathogenesis and treatment options of this rare entity are discussed.

Key Words: Focal nodular hyperplasia; hyperplasia; parotid region; oxyphil cells

ÖZET Onkositik lezyonlar tüm tükürük bezi lezyonlarının %1'inden daha azdır ve parotis bezinde nadiren görülür. WHO sınıflaması onkositik lezyonlar için 3 tip tanımlamıştır: Onkositozis, onkositoma ve onkositik karsinom. Onkositozis, onkositlerin tükürük bezinde nodüler ve diffüz paternde birikimi ve proliferasyonudur. Multifokal nodüler onkositik hiperplazi tükürük bezinin çok nadir görülen non-tümöral patolojisidir ve sıklıkla parotis bölgesinde görülür. Son 2 ay içerisinde giderek büyüyen sağ preaurikuler kitle tarifleyen 38 yaşındaki erkek hastanın parotis bezinde görülen multifokal onkositik hiperplazi olgusu sunuyoruz. Bu nadir lezyonun ayırıcı tanısı, histopatogenezi ve tedavi seçenekleri tartışılmıştır.

Anahtar Kelimeler: Fokal nodüler hiperplazi; hiperplazi; parotis bölgesi; oksifil hücreler

Türkiye Klinikleri J Case Rep 2015;23(3):347-50

Oncocytes are transformed epithelial cells which are characterized by an abundant, intense eosinophilic and granular cytoplasm filled with numerous tightly packed mitochondria showing varied pleomorphism and centrally located nuclei with a condensed chromatin pattern.^{1,2}

Oncocytes are found in many different organs such as kidney, breast, thyroid and lacrimal glands, buccal mucosa, the upper respiratory tract, and also in apparently normal major and minor salivary gland tissue, where they usually occur in small aggregates among the normal acinar and ductal cells.^{2,4}

They appear as the major component in pathological conditions of the salivary glands, including diffuse oncocytosis, multifocal nodular oncocytic hyperplasia (MNOH), oncocytic metaplasia, oncocytomas, and oncocytic

carcinoma.¹⁻⁹ The most frequent oncocytic tumor of salivary glands is Warthin's tumor "papillary cystadenoma lymphomatosum" and oncocytic cells can also appear in pleomorphic adenoma.^{2,3,7,8}

MNOH in the salivary glands is an extremely rare condition representing a multifocal oncocytic proliferation of the duct system. MNOH makes up 0.1% of the parotid gland diseases.^{7,10}

It consists of non-encapsulated nodules of oncocytic cells and the nodules have a lobular distribution. At the periphery of the nodules, normal salivary gland tissue may be included and this may give the false impression that the lesion is an invasive neoplasm. In this case report, we describe clinical and histological features of a case of MNOH in the parotid region, and discuss the differential diagnosis.

CASE REPORT

A 38-year-old man was admitted to our department with a swelling in the right parotid region. This had appeared about two months earlier and gradually increased in volume. There was no pain, dryness of mouth or swelling of the tumor related to meals. No signs of infection or general symptoms were present. Physical examination showed a swelling in the right parotid area, which were not fixed to the underlying structures. Their exact relation to the parotid glands was difficult to determine. There were no features suggestive of facial nerve involvement and no pathological changes were detected clinically in the left parotid gland. Routine blood count and biochemical findings were within normal limits.

Pre-operative sonography revealed multiple cystic structures, measuring 16 mm in greatest diameter in the superficial and deep lobe. Pre-operative MRI revealed multiple masses (maximum: 15x10 mm in size) in and right parotid glands. A total parotidectomy was performed and the surgical specimen consisted of multiple fragment which together measured 7x4,5x2,3 cm and 22 grams. The lobular arrangement of the parotid gland was maintained (Figure 1). The resected specimen appeared slightly indurated salivary gland and serial sections

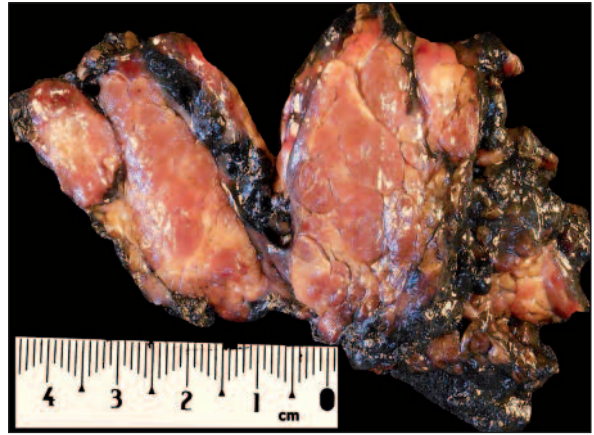

FIGURE 1: Macroscopic appearance of the resected tumor. Multiple mahogany-brown nodules were seen on the background of normal salivary gland.

revealed multiple mahogany-brown colored, focally coalescing nodules that showing various size between 3-10 mm. On microscopic examination the oncocytic cells appeared with abundant eosinophilic cytoplasm forming compact, non-encapsulated complexes and a slight decrease in the number of acinar structures was seen (Figure 2). Multiple cysts were found, with a two-layered epithelial lining of oncocytic cells. There were no hyperchromasia of the nuclei, mitosis, and necrosis in the tumor cells (Figure 3). Phosphotungstic acid hematoxylin (PTAH) stain demonstrated diffuse positivity in the oncocytic cells (Figure 4). Based on these gross and microscopic findings, the diagnosis in this case was MNOH of the right parotid gland. Since this parotid lesion was diagnosed as benign entity (hyperplasia), additional surgery was not done. At the 17-months follow-up, the patient was doing well and reported no complaints.

DISCUSSION

Oncocytes are transformed epithelial cells which are characterized by intense eosinophilic, abundant and granular cytoplasm filled with numerous tightly packed mitochondria showing varied pleomorphism and centrally located nuclei with a condensed chromatin pattern.^{1,2} If there is any doubt concerning the oncocytic nature of the cells, PTAH stain is recommended to demonstrate the characteristic abundance of mitochondria in the cytoplasm. Also, immunohistochemically mito-

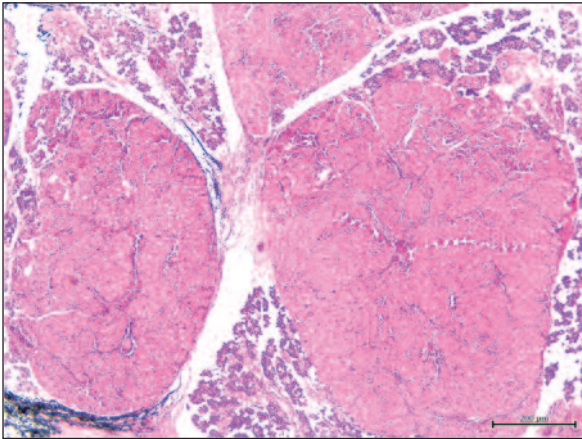


FIGURE 2: Normally structured and mildly compressed salivary gland tissues are seen between the nodules (HE, x20).

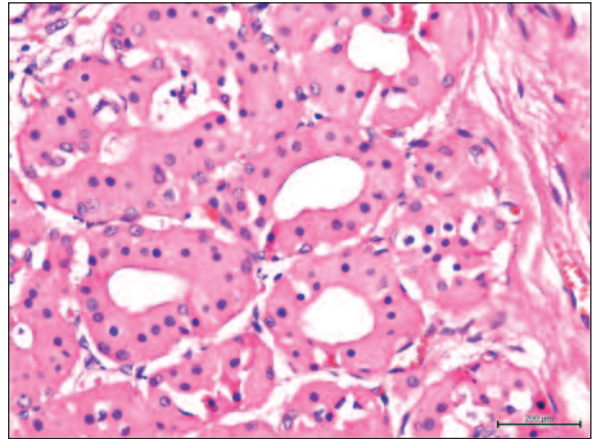


FIGURE 3: The constituent cells display abundant oncocytic features with normal nucleo-cytoplasmic ratio (HE, x600).

chondrial antibody may be used in order to show abundance of mitochondria.¹¹ The most frequent oncocytic tumor of salivary glands is Warthin's tumor and oncocytic cells may also be seen in pleomorphic adenoma.^{2,3,7,8} Oncocytes may also encountered in some pathological conditions of the salivary glands like diffuse oncocytosis, MNOH, oncocytic metaplasia, oncocytoma and oncocytic carcinoma. Lesions composed entirely of oncocytes fall into three categories-oncocytoma, diffuse oncocytosis and multifocal nodular oncocytic hyperplasia.⁵⁻⁹

MNOH is a rare condition that is characterized by the presence of multiple nodules of oncocytic cells and makes up 0.1% of the parotid gland diseases.^{7,10} It is mainly diagnosed in women and in the sixth decade and the clinical features may include swelling and tenderness of the parotid region and duration of the symptoms may be from several months to 25 years duration.^{7,12} The parotid is usually affected and between five and ten nodules are usually seen. MNOH is described as multinodular non-encapsulated oncocytic foci measuring between 0.1 and 1 cm, containing inclusions of salivary gland remnants, occasionally with ductal oncocytic metaplasia.^{5,6,10,13} Clear cells rarely may be present. Nuclear hyperchromasia, mitoses and necrosis are not seen, except mild pleomorphism. The cells are pale eosinophilic, granular and PTAH stain is positive, which may also help in diagnosis.¹¹ The histopathological picture

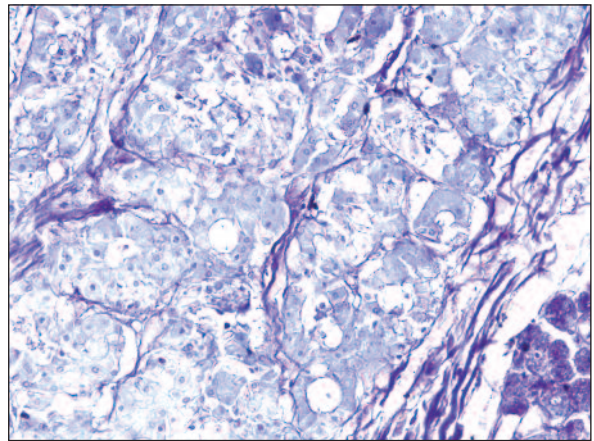


FIGURE 4: Diffuse PTAH positivity were seen in the oncocytic cells (PTAH, x400).

of this case is usual; because of these tumorous nodules consist only oncocytic cells and were diagnosed as oncocytic benign lesion easily. Possibly, the most important histopathological finding in the differential diagnosis of this entity from other oncocytic lesions like diffuse oncocytosis and oncocytic adenoma is multinodular aspect of MNOH. The multinodular growth may suggest malignancy, but smooth contours of the peripheral edges of the oncocytic nodules and association of oncocytic metaplasia in intercalated ducts and ductules in the surroundings strongly supports the benign condition.^{10,14}

Many authors believe that, salivary gland oncocytoma is considered as the neoplastic counterpart of diffuse hyperplastic oncocytosis of salivary

gland, sharing many features with the latter, including the presence of a discrete lesion in which residual salivary gland parenchyma is rarely seen. The pathogenesis of diffuse hyperplastic oncocytosis remains unknown.^{7,15}

MNOH shares the oncocytic epithelium and the formation of cystic spaces with Warthin's tumor. Classical Warthin's tumor is almost always encapsulated and oncocytic epithelium is surrounded by abundant lymphoid tissue, which frequently forms germinal follicles. In the enlightenment of these histological findings, Warthin's tumor can be clearly distinguished from MNOH.^{16,17}

MNOH should be regarded as a benign lesion and treated only by surgery. The lesion is not responsive to irradiation and the possibility of radiation-induced malignant transformation should be considered. In cases of positive surgical margin due to the partial or improper resection, recurrences may be expected.^{10,11,16}

In conclusion, diffuse oncocytosis and MNOH of the salivary glands are benign disorders of salivary gland and many authors believe that this entity has hyperplastic pathogenesis with benign course, distinct from oncocytoma, which can be considered to be a benign epithelial tumor of the salivary glands.

REFERENCES

1. The International Agency for Research on Cancer. WHO histological classification of tumours of the salivary gland. In: Barnes L, Eveson JW, Reichart P, Sidransky D, eds. Pathology and Genetics of Head and Neck Tumours (IARC WHO Classification of Tumours). Lyon: IARC Press; 2005.p.210-36.
2. Tung BK, Li WY, Chu PY. Pathology quiz case 2. Multifocal nodular oncocytic hyperplasia (MNOH). Arch Otolaryngol Head Neck Surg 2012;138(5):523-4.
3. Müller-Höcker J. [Oncocytic metaplasia/neoplasia--morphology, biochemistry, molecular genetics]. Pathologe 1998;19(2):104-14.
4. Schwartz IS, Feldman M. Diffuse multinodular oncocytoma ("oncocytosis") of the parotid gland. Cancer 1969;23(3):636-40.
5. Hyde J, Takashima M, Dodson B, Said S. Bilateral multinodular oncocytomas of the parotid arising in a background of bilateral oncocytic nodular hyperplasia. Ear Nose Throat J 2008;87(1):51-4.
6. Brandwein MS, Huvos AG. Oncocytic tumors of major salivary glands. A study of 68 cases with follow-up of 44 patients. Am J Surg Pathol 1991;15(6):514-28.
7. Becker K, Donath K, Seifert G. [Diffuse oncocytosis of the parotid gland. Definition and differential diagnosis]. Laryngol Rhinol Otol (Stuttg) 1982;61(12):691-701.
8. Nair BJ, Vivek V, Sivakumar TT, Joseph AP, Varun BR, Mony V. Clear cell myoepithelioma of palate with emphasis on clinical and histological differential diagnosis. Clin Pract 2014; 4(1):628.
9. Palmer TJ, Gleeson MJ, Eveson JW, Cawson RA. Oncocytic adenomas and oncocytic hyperplasia of salivary glands: a clinicopathological study of 26 cases. Histopathology 1990;16(5):487-93.
10. Lidang Jensen M. Multifocal adenomatous oncocytic hyperplasia in parotid glands with metastatic deposits or primary malignant transformation? Pathol Res Pract 1989; 185(4):514-21; discussion 521-2.
11. Ellis GL. "Clear cell" oncocytoma of salivary gland. Hum Pathol 1988;19(7):862-7.
12. Strassburger S, Hyckel P, Kosmehl H. Multifocal oncocytic adenomatous hyperplasia of the parotid gland. A case report. Int J Oral Maxillofac Surg 1999;28(6):457-8.
13. Politi M, Toro C, Cian R, Robiony M. Multifocal adenomatous oncocytic hyperplasia of the parotid gland. Oral Oncol Extra 2005;41(8): 183-7.
14. Ghandur-Mnaimneh L. Multinodular oncocytoma of the parotid gland: a benign lesion simulating malignancy. Hum Pathol 1984;15(5): 485-6.
15. Chang A, Harawi SJ. Oncocytes, oncocytosis, and oncocytic tumors. Pathol Annu 1992;27 Pt 1:263-304.
16. Cawson RA, Binnie WH, Speight PM, Barret AW, Wright AW. Lucas's Pathology of Tumours of the Oral Tissues. London, Edinburgh, New York: Churchill Livingstone; 1998. p.374-6.
17. Hartwick RW, Batsakis JG. Non-Warthin's tumor oncocytic lesions. Ann Otol Rhinol Laryngol 1990;99(8):674-7.