

Safety and Efficacy of N-butyl Cyanoacrylate in End-Stage Renal Disease: Case Report

Son Dönem Böbrek Yetmezliğinde N-butil Siyanoakrilatın Güvenilirliği ve Etkinliği

Ahmet KIYKIM, MD,^a
Gültekin GENÇTOY, MD,^a
Mehmet HOROZ, MD,^a
Mehmet ŞENLİ, MD,^a
Ebru GÖK, MD,^a
Caner ÖZER, MD,^b
Altan YILDIZ, MD^b

^aDivision of Nephrology,
^bDepartment of Radiology,
Mersin University Faculty of Medicine,
Mersin

Geliş Tarihi/Received: 21.05.2008
Kabul Tarihi/Accepted: 20.08.2008

This case report has been presented as a poster at the 9th National Congress of Hypertension and Kidney Disease (30 May-3 June 2007, Antalya, Turkey).

Yazışma Adresi/Correspondence:
Mehmet HOROZ, MD
Mersin University Faculty of Medicine,
Division of Nephrology, Mersin,
TÜRKİYE/TURKEY
mehmethoroz@yahoo.com

ABSTRACT The tissue adhesive N-butyl cyanoacrylate (NBCA) has been widely used for more than 20 years as an occluding agent in the treatment of pseudo aneurysm and arterio-venous fistula. However, there is limited experience about its use among end-stage renal disease patients. We described a case of a maintenance hemodialysis patient experienced both a pseudoaneurysm and an arterio-venous fistula after a penetrating buckshot injury treated with percutaneous NBCA injection. We suggest that percutaneous NBCA embolization can be used safely and effectively in the treatment of traumatic peripheral pseudo aneurysm and arterio-venous fistula in patients with end-stage renal disease, and it may be an alternative to either traditional surgical interventions, which may be associated with increased morbidity and mortality and other non-surgical interventions.

Key Words: Embolization, therapeutic; arteriovenous fistula; renal insufficiency, chronic

ÖZET N-butil siyanoakrilat (NBSA), 20 yılı aşkın bir süredir psödoanevrizma ve arteriyovenöz fistüllerin tedavisinde embolizasyon amacı ile yaygın olarak kullanılan bir ajan olmakla birlikte, son dönem böbrek yetmezliği bulunan hastalarda bu ajanın kullanımı ile ilgili deneyimler oldukça sınırlıdır. Bu olgu sunumunda son dönem böbrek yetmezliği bulunan bir hastada ateşli silah yaralanmasına bağlı olarak gelişen bir psödoanevrizma ve arteriyovenöz fistülün, perkütan yolla NBSA embolizasyonu uygulanarak başarılı bir şekilde tedavi edildiğini bildirmeyi amaçladık. Son dönem böbrek yetmezliği bulunan hastalarda travma sonrası gelişen periferik psödoanevrizma ve arteriyovenöz fistüllerin tedavisinde perkütan yolla uygulanan NBSA embolizasyonu hem güvenli hem de etkili bir yöntem olup, morbidite ve mortalitesi yüksek olabilen geleneksel cerrahi girişim yöntemlerine ve cerrahi dışı diğer tedavi seçeneklerine alternatif bir tedavi yaklaşımı olarak kullanılabilir.

Anahtar Kelimeler: Terapötik embolizasyon, arteriyovenöz fistül, kronik böbrek yetmezliği

Türkiye Klinikleri J Med Sci 2009;29(5):1335-8

Peripheral pseudoaneurysms usually develop after surgery, trauma and catheterization and can be treated by either surgical or non-surgical interventions.¹⁻³ Direct percutaneous embolization with embolic agents is one of the popular methods of non-surgical interventions.^{4,5}

The tissue adhesive NBCA is among the most popular occluding agents that can be used in the treatment of pseudo aneurysm and arterio-venous fistula (AVF). Although it has been widely used for more than 20 years, there is limited experience in its use among end-stage renal disease (ESRD)

patients, in whom retention of up to 90 uremic toxins was well documented and vascular injuries are facilitated through chronic inflammation and vascular calcifications.⁵⁻⁸

We report a case of post-traumatic femoral pseudo aneurysm and AVF treated with percutaneous injection of NBCA in a patient with end-stage renal disease undergoing hemodialysis treatment.

CASE REPORT

An 18-year-old male was admitted with progressive pain and swelling on the left knee developed following a buckshot injury 12 days ago.

His medical history revealed that he had end-stage renal disease and underwent regular hemodialysis treatment through AVF thrice weekly since 3 years. Physical examination revealed that the patient was slim with normal blood pressure, pulse frequency and body temperature. On the left thigh and knee, he had an edematous swelling, warmth and redness. A systolic thrill was also observed on the anteromedial region of the left knee.

Laboratory tests were normal except for elevated blood urine nitrogen (95 mg/dL; normal 5 to 20 mg/dL) and serum creatinine level (8 mg/dL; normal <1.2 mg/dL), mild anemia (hemoglobin: 10.02 g/dL), elevated serum phosphate level (10.1 mg/dL; normal 4.5 to 6.7 mg/dL) and mild metabolic acidosis (pH: 7.28 and HCO₃: 16 meq/L). Electrocardiography and chest X-ray was normal. Plain radiogram of the pelvis showed two scarce densities in the pelvic region possibly related to buckshot. Doppler waveforms analysis of the lower extremities revealed the pseudoaneurysm formation with edematous appearance of subcutaneous soft tissue plans surrounding the distal region of left cruris and the left knee and intramuscular hematoma.

Based on abnormal physical examination and Doppler ultrasonography (USG) findings possibly related to a vascular problem, angiography was performed through the femoral artery. Angiography revealed an aneurismal sac arising from the muscular branch of the superficial femoral artery and small muscular branches of the popliteal artery and

an AVF causing early venous filling at the distal region of the left superficial femoral artery (Figure 1). At the same session a 6F introducer was inserted in the left femoral artery followed by a 4F hydrophilic catheter navigated into the descending geniculate branch of the femoral artery. A microcatheter and micro guide-wire was inserted through the 4F catheter and was advanced as far in to the nidus of the fistula as possible. Coil embolization was performed at this localization. Although the muscular branch of the superficial femoral artery and catheterizable small muscular arteries were occluded, the pseudo aneurysm and A-V fistula were seen to be filled via small muscular arteries arising from the popliteal artery on post-embolization control angiography (Figure 2). Therefore, one week later from the angiography, the pseudo aneurysm was directly embolized through percutaneous route using glue (Glubran 2; GEM, Viareggio, Italy) and lipiodol (Lipiodol ultra-fluid, Guerbet, Cedex, France) mixture with the guidance of ultrasonog-

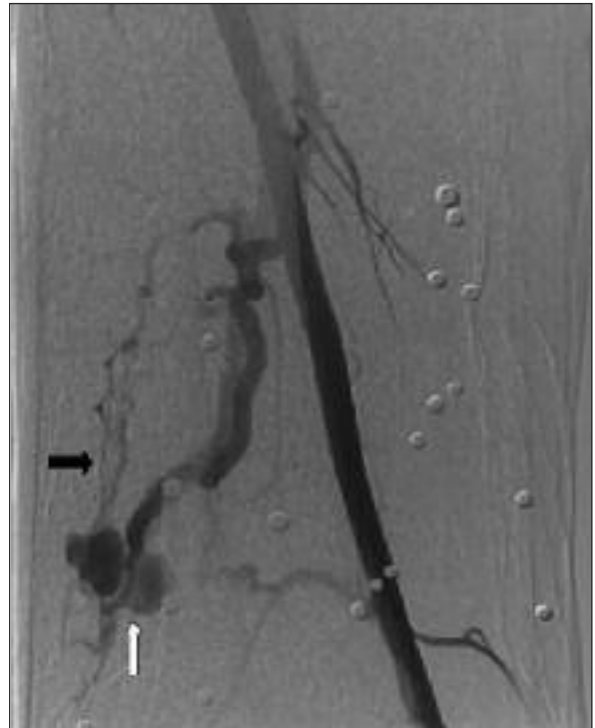


FIGURE 1: Anteroposterior view of the aneurismal sac (white arrow) arising from the muscular branch of the superficial femoral artery and small muscular branches of the popliteal artery, and arteriovenous fistula causing early venous filling (black arrow) at the distal region of the left superficial femoral artery.

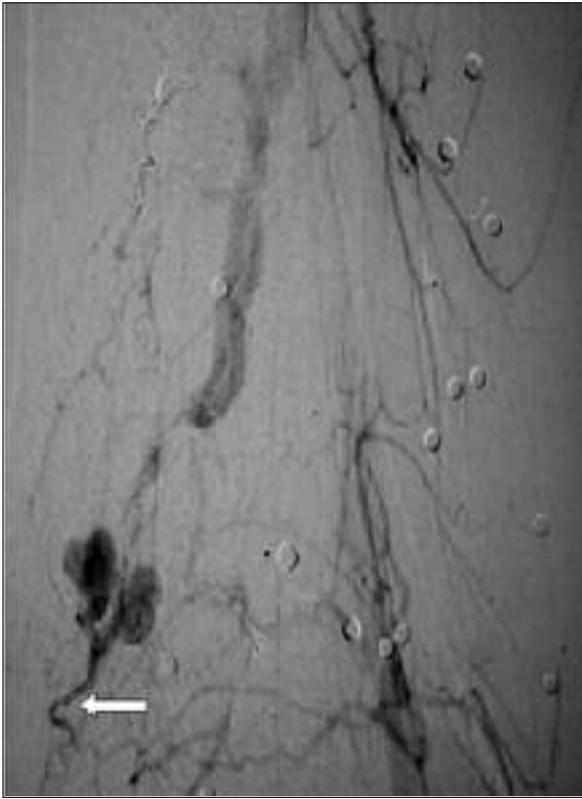


FIGURE 2: Control angiography image obtained after coil embolization. The pseudoaneurysm and A-V fistula were still filled via small muscular arteries arising from the popliteal artery (arrow).

raphy and fluoroscopy (Figure 3). No complication observed during and after the procedure. Written consent was obtained from the patient before each procedure. Doppler USG analysis performed immediately after glue embolization revealed no perfusion of the pseudo aneurysm cavity (Figure 4). A few days after this procedure edematous swelling, warmth, redness and the systolic thrill on the anteromedial region of the left knee completely disappeared.

DISCUSSION

Penetrating trauma leads to fistulous communication of artery and veins as they run close to each other. Injuries to the vessels lead to pseudo aneurysm formation, which later ruptures into the vein and results in high-low pressure fistulas. Underlying developmental defect, inflammatory condition or vascular calcifications may predispose to fistula formation.⁹

It is well known that uremia is characterized by the retention of a host of compounds that in healthy subjects are secreted by the kidneys into normal urine. These compounds disturb many physiologic functions, resulting in toxicity. Many of

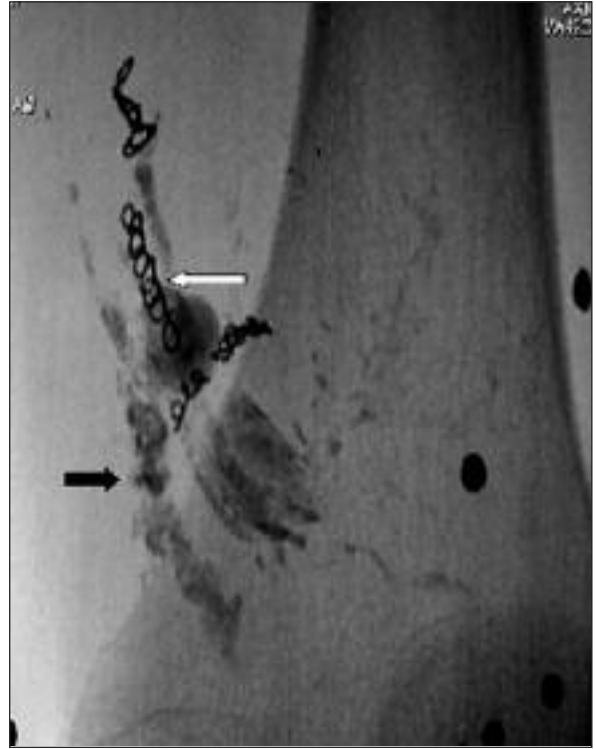


FIGURE 3: Native image of the areas embolized using coil embolization (white arrow) and glue injection (black arrow).

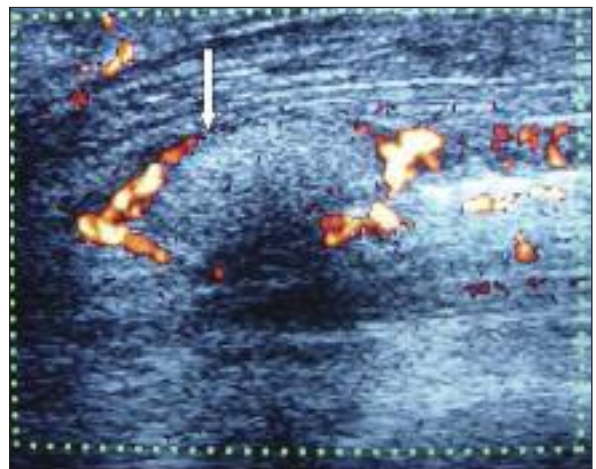


FIGURE 4: Doppler waveforms analysis image obtained immediately after glue embolization demonstrating no perfusion of pseudoaneurysm cavity (arrow).

the responsible compounds remain unknown, however, as well as many patho-physiologic actions of the known retention solutes.¹⁰ Theoretically, any therapeutic agent given into the endovascular space may interfere with accumulated known and unknown uremic compounds and may not sufficiently exert its action in chronic kidney disease subjects. In addition, uremic vascular disorders may also interfere with those therapeutic agents given into the endovascular space and reduce their efficacy.

Here we described a case of a maintenance hemodialysis patient experienced both a pseudo aneurysm arising from the muscular branch of the superficial femoral artery and small muscular branches of the popliteal artery and an AVF causing early venous filling at the distal region of the left superficial femoral artery after a penetrating buckshot injury. Initially, the muscular branch of the superficial femoral artery and catheterizable small muscular arteries were occluded using coil embolization. However, the pseudo aneurysm and AVF were seen to be still filled via small muscular arteries arising from the popliteal artery on post-embolization control angiography; thus we proceeded to the embolization procedure using NBCA injection. The major risk of direct percutaneous

embolization using NBCA injection is distal embolization due to escape of material from aneurismal cavity before it is completely polymerized. To prevent this complication, tourniquet was applied to both proximal and distal side of the pseudo aneurysm during injection and was held in place until polymerization was complete. Thus, this complication was not observed in our case. To our best of knowledge, the information related to the use of NBCA for the treatment of pseudoaneurysm in ESRD patients is limited to the case report by Aytekin et al, in which they reported direct percutaneous injection of NBCA to embolize a peripheral pseudoaneurysm in a hemodialysis patient.⁵ They used an angioplasty balloon to prevent ischemic complication and we applied tourniquet instead. Additionally, in our case, the coexistence of AVF was also treated successfully.

In conclusion, as shown in the present case, percutaneous NBCA embolization may be safely, effectively and practically used in the treatment of peripheral pseudo aneurysms and AVFs in uremic patients. Furthermore, it may be a treatment of choice in various steal syndromes associated with dialysis fistula in appropriate dialysis patients.

REFERENCES

1. Clark ET, Gewertz BL. Pseudo aneurysms. In: Rutherford RB, ed. *Vascular Surgery*. 4th ed. Philadelphia: WB Saunders; 1995. p.1153-61.
2. Kaklıkkaya I, Ozdemir R, Filizlioğlu H, Özcan F. [Traumatic arteriovenous fistulas; treatment and follow up]. *Turkiye Klinikleri J Med Sci* 1996;16(5):387-90.
3. Pezullo JA, Dupuy DE, Cronan JJ. Percutaneous injection of thrombin for the treatment of pseudo aneurysms after catheterization: an alternative to sonographically guided compression. *Am J Roentgenol* 2000;175(4):1035-40.
4. Aytekin C, Fırat A, Yıldırım E, Kırbas I, Boyvat F. Ultrasound-guided glue injection as alternative treatment of femoral pseudo aneurysms. *Cardiovasc Intervent Radiol* 2004; 27(6):612-5.
5. Aytekin C, Boyvat F, Gebedek O, Coskun M. Balloon-assisted ultrasound-guided direct percutaneous embolization of a peripheral pseudoaneurysm with n-butyl cyanoacrylate. *Eur Radiol* 2002;12(Suppl 4):185-8.
6. Debrun G, Vinuela F, Fox A, Drake CG. Embolization of cerebral arteriovenous malformations with bucrylate. *J Neurosurg* 1982; 56(5):615-27.
7. Vanholder R, De Smet R, Glorieux G, Argilés A, Baumeister U, Brunet P, et al; European Uremic Toxin Work Group (EUTox). Review on uremic toxins: classification, concentration, and interindividual variability. *Kidney Int* 2003;63(5):1934-43.
8. İmren Y, Sinci V. [Histopathologic analysis of internal thoracic artery in patients with chronic renal failure]. *Turkiye Klinikleri J Med Sci* 2005;25(6):795-9.
9. Lai JH, Yan HC, Kao SJ, Lee SC, Shen CY. Intercostal arteriovenous fistula due to pleural biopsy. *Thorax* 1990;45(12):976-8.
10. Vanholder R, Glorieux G, Lameire N. New insights in uremic toxicity. *Contrib Nephrol* 2005;149:315-24.