

# Metastatic Myxoid Liposarcoma of the Scalp: Case Report

## Saçlı Deride Metastatik Miksoid Liposarkom

Nejmi KIYMAZ, MD, Assoc.Prof.,<sup>a</sup>  
Nebi YILMAZ, MD, Assis.Prof.,<sup>b</sup>  
Burhan ORAL GÜDÜ, MD,<sup>a</sup>  
İsmail DEMİR, MD, Msc,<sup>a</sup>  
Abdulsemat GÖKALP, MD<sup>a</sup>

<sup>a</sup>Department of Neurosurgery,  
Yüzüncü Yıl University,  
Faculty of Medicine, Van,

<sup>b</sup>Department of Neurosurgery,  
Mustafa Kemal University,  
Faculty of Medicine, Hatay

Geliş Tarihi/Received: 15.03.2010  
Kabul Tarihi/Accepted: 17.12.2010

Yazışma Adresi/Correspondence:  
Burhan ORAL GÜDÜ, MD  
Yüzüncü Yıl University,  
Faculty of Medicine,  
Department of Neurosurgery, Van,  
TÜRKİYE/TURKEY  
drburhanoralgudu@msn.com

**ABSTRACT** Liposarcomas are the second most frequent soft tissue sarcomas occurring in adults after malignant fibrous histiocytomas; however, liposarcomas rarely occur on the scalp. A mass was detected on the hairy skin of a 38-year-old male patient who had undergone surgery for a mass on the posterior aspect of the right thigh and had been diagnosed with a myxoid liposarcoma 3 years earlier. The patient had undergone total bulk excision and the histopathologic examination of the mass lesion revealed liposarcoma metastasis. Chemotherapy was initiated. Relapse or metastasis did not develop during 3 years of follow-up. Here we present a patient with a myxoid liposarcoma, which metastasized from the posterior side of the right thigh to the scalp.

**Key Words:** Liposarcoma, myxoid; scalp; neoplasm metastasis

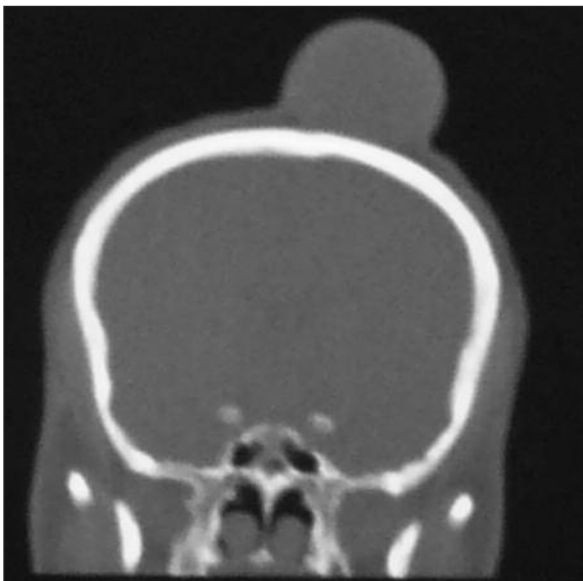
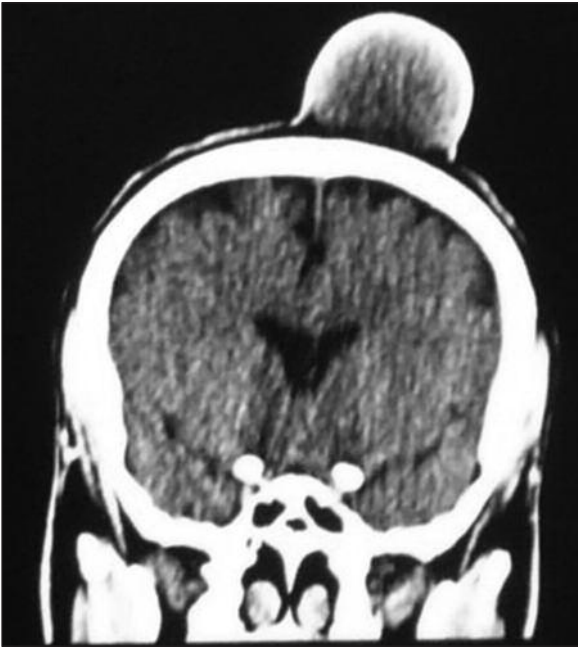**ÖZET** Liposarkomlar malin fibröz histiyositomlardan sonra yetişkinlerde en sık görülen ikinci yumuşak doku sarkomu türüdür; ancak liposarkomlar saçlı deride nadiren görülmektedir. Üç yıl önce sağ uyluk arka yüzünden geçirdiği operasyon ile miksoid liposarkom tanısı alan 38 yaşındaki bir erkek hastanın saçlı derisinde bir kitle tespit edildi. Total kitle eksizyonu yapılan hastanın patolojisi liposarkom metastazı olarak rapor edildi. Hastaya kemoterapi uygulandı. Hastanın 3 yıllık izleminde relaps veya metastaz saptanmadı. Burada sağ uyluk arka yüzünden saçlı deriye metastaz yapan miksoid liposarkomlu bir olgu sunuyoruz.

**Anahtar Kelimeler:** Liposarkom, miksoid; saçlı deri; tümör metastazı

**Türkiye Klinikleri J Med Sci 2012;32(1):260-3**

Soft tissue sarcomas are rare tumors accounting for 0.7% of all adult malignancies.<sup>1</sup> Liposarcomas develop from mature adipose tissue cells (lipoblasts) or more frequently from primitive mesenchymal cells.<sup>2,3</sup>

Liposarcomas are the second most common soft tissue sarcomas in adults (14-18%).<sup>4</sup> Based on pathologic evaluation, liposarcomas are classified as well-differentiated, poorly-differentiated, myxoid, pleomorphic, and mixed types.<sup>5</sup> The most common type of liposarcoma is the myxoid liposarcoma; it involves the lower extremity, thigh or retroperitoneum and is sometimes multifocal.<sup>6</sup> Liposarcomas have five subtypes with prognoses directly related with histopathologic features. Liposarcomas are located on the head and neck regions at a rate of approximately 1%.<sup>7,8</sup> Here we present a patient with a myxoid liposarcoma on the thigh with metastasis to the scalp with a review of the literature.

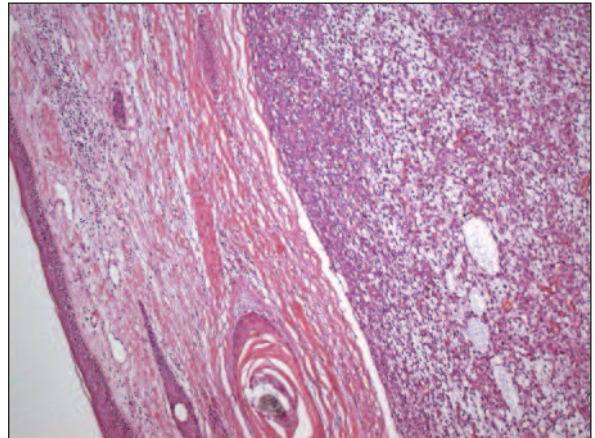


**FIGURE 1,2:** Scalp metastasis of a myxoid liposarcoma to the left frontoparietal area on coronal section brain tomography without contrast.

## CASE REPORT

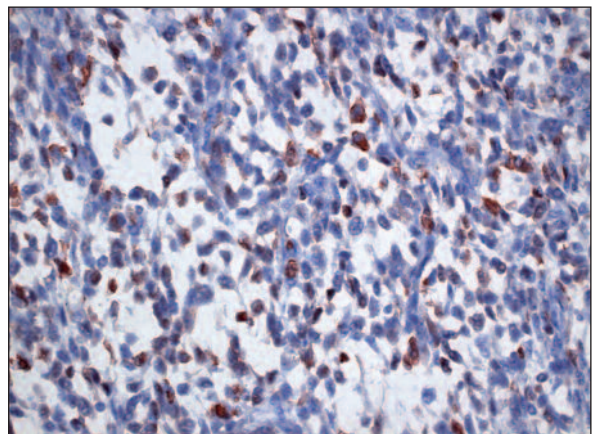
A 38-year-old male patient presented to our outpatient clinic with a painful medium-sized mass on the hairy skin of the upper left part of his head for the last four months. The physical examination revealed a uniformly-bounded, medium-hard, round, mobile mass which was not fixed to the underlying bone on the left frontoparietal hairy skin. The

clinical history revealed that a soft tissue mass had been excised from the distal 1/3 of his posterior right thigh two years ago, which was diagnosed with myxoid liposarcoma according to histopathologic findings. The patient had not received post-operative radiotherapy or chemotherapy. He presented to the medical oncology clinic with a painful mass in the distal 1/3 of the posterior right thigh 3 months after the first surgical procedure. He had a 6 x 3 cm mass on his posterior right thigh. Magnetic resonance imaging (MRI) of the thigh revealed myxoid liposarcoma recurrence. The patient underwent surgery, was shown to have negative surgical margins, and post-operative radiotherapy was administered. No metastases were detected. Four months after radiotherapy, he discovered a



**FIGURE 3:** Fine limited tumor tissue invading deep from the dermis (H&E, x 100).

(See for colored form <http://tipbilimleri.turkiyeklinikleri.com/>)



**FIGURE 4:** Cytoplasmic and nuclear S100 positivity in tumor cells (Avidin-Biotin Peroxidase x 400).

(See for colored form <http://tipbilimleri.turkiyeklinikleri.com/>)

mass on the upper left part of his head and presented to our clinic. Computed tomography (CT) scan revealed a uniformly-bounded, 6,5 x 5,5 x 5 cm hypointense mass involving the left frontoparietal zone with no invasion to the bone (Figure 1, 2).

The patient underwent surgery under general anesthesia and the mass was totally excised. Histopathologic examination revealed tumor tissue starting from the dermis and infiltrating the subcutaneous fatty tissue. The tumor tissue consisted of lipoblasts with round, clear cytoplasmic lipid vacuoles that pushed the nucleus aside between the venous structures in a plexiform pattern on the myxoid floor (Figure 3). The tumor cells immunostained positive for S100 (Figure 4).

The mass on the scalp was shown to be a metastatic myxoid liposarcoma and the patient received six cycles of adriablastin chemotherapy. No recurrence or other metastases were detected on follow-up.

## DISCUSSION

Liposarcomas are the most frequent soft tissue sarcomas.<sup>9,10</sup> The most common sites for liposarcomas are the thigh and the retroperitoneum; liposarcomas are rarely reported on the head and neck.<sup>3,11,12</sup> The myxoid liposarcoma of this patient represents the most common sub-type of liposarcoma.<sup>10</sup> Liposarcomas occur at a rate of 1% in the head and neck regions.<sup>7,8</sup>

Metastasis of a tumor is rare when the primary tumor occurs rarely and it is thus difficult to predict the frequency from the literature. Myxoid liposarcomas carry the risk of local recurrence and in the case of a rare metastasis, myxoid liposarcomas develop most frequently in the retroperitoneum and

the abdomen.<sup>6</sup> Myxoid liposarcomas can be mixed with lipomas on CT; myxoid liposarcomas are separated from the normal tissue by a thin line and MRI may depict necrosis. The diagnosis of liposarcomas can be made by a high-resolution nuclear magnetic resonance spectroscopy. The radiologic appearance of liposarcomas is closely related to the histopathologic type.<sup>13,14</sup> It may be difficult to achieve a diagnosis by a fine needle biopsy. Surgery is the most effective treatment for myxoid liposarcomas and a total excision should be performed. In case there is a question of negative surgical margins due to the closeness to the neurovascular tissues of the head and neck, post-operative radiotherapy should be added to the treatment. The effectiveness of radiotherapy is particularly high in myxoid liposarcomas.<sup>15,16</sup> Including local recurrences the metastasis rate is 40%. The highest rate of metastasis is for retroperitoneal location followed by abdomen, paraspinal area, lungs, and liver in decreasing order.<sup>6</sup> There are only three case reports with metastasis in the literature similar to our case.<sup>14,17</sup> Metastasis and mortality rates for myxoid and well-differentiated types are lower than the rates for round cell and pleomorphic types. In the series by Susanne et al.<sup>6</sup> consisting of 22 cases with myxoid liposarcoma metastases to the extremities, there were no cases of scalp metastasis. Gritli et al., stated that two myxoid liposarcomas out of three in the liposarcoma series located at the head and neck were located on the scalp and that one of them had metastasis starting from the leg and ending at the scalp.<sup>15</sup>

Metastases of myxoid liposarcomas to the head and neck are rare. The most efficient treatment is radical total excision; radiotherapy has a palliative effect and decreases the risk of spread in patients with liposarcomas.

## REFERENCES

1. Cany L, Stoeckle E, Coindre JM, Kantor G, Bonichon F, Bui BN. Prognostic factors in superficial adult soft tissue sarcomas: analysis of a series of 105 patients. *J Surg Oncol* 1999; 71(1):4-9.
2. Mentzel T, Fletcher CD. Lipomatous tumours of soft tissues: an update. *Virchows Arch* 1995;427(4):353-63.
3. Gökçe A, Albayrak L, Kulaçoğlu S. [Lipoblastoma in a 62 years old female: case report]. *Türkiye Klinikleri J Med Sci* 2009;29(3):750-2.
4. Peterson JJ, Kransdorf MJ, Bancroft LW, O'Connor MI. Malignant fatty tumors: classification, clinical course, imaging appearance and treatment. *Skeletal Radiol* 2003;32(9): 493-503.
5. Murphy MD, Arcara LK, Fanburg-Smith J. Imaging of musculoskeletal liposarcoma with radiologic-pathologic correlation. *Radiographics* 2005;25(5):1371-95.
6. Estourgie SH, Nielsen GP, Ott MJ. Metastatic patterns of extremity myxoid liposarcoma and their outcome. *J Surg Oncol* 2002;80(2):89-3.

7. Sharon SW, Goldblum JR, Enzinger FM. Liposarcoma. In: Enzinger FM, eds. *Enzinger's and Weiss's Soft Tissue Tumors*. 4<sup>th</sup> ed. Vol. 6. St. Louis, MO: Mosby; 2001. p. 641-93.
8. Gollledge J, Fisher C, Rhys-Evans PH. Head and neck liposarcoma. *Cancer* 1995;76(6): 1051-8.
9. Newlands SD, Divi V, Stewart CM. Mixed myxoid/round cell liposarcoma of the scalp. *Am J Otolaryngol* 2003;24(2):121-7.
10. Enzinger FM, Weiss SW. *Soft Tissue Tumors*. 3<sup>rd</sup> ed. St. Louis: C.V. Mosby; 1995. p.436.
11. Smith TA, Easley KA, Goldblum JR. Myxoid/round cell liposarcoma of the extremities: a clinicopathologic study of 29 cases with particular attention to extent of round cell liposarcoma. *Am J Surg Pathol* 1996;20(2): 171-80.
12. Fiore M, Grosso F, Lo Vullo S, Pennacchioli E, Stacchiotti S, Ferrari A, et al. Myxoid/round cell and pleomorphic liposarcomas: prognostic factors and survival in a series of patients treated at a single institution. *Cancer* 2007; 109(12):2522-31.
13. Sheah K, Ouellette HA, Torriani M, Nielsen GP, Kattapuram S, Bredella MA. Metastatic myxoid liposarcomas: imaging and histopathologic findings. *Skeletal Radiol* 2008;37 (3): 251-8.
14. Kessler A, Berenholz L, Eviatar E, Segal S. Liposarcoma of the scalp: a case report and review of the literature. *Otolaryngol Head Neck Surg* 1997;117(4):412-4.
15. Grilli S, Khamassi K, Lachkhem A, Touati S, Chorfa A, Ben Makhlof T, et al. Head and neck liposarcomas: a 32 years experience. *Auris Nasus Larynx* 2010;37(3):347-51.
16. Zagars GK, Goswitz MS, Pollack A. Liposarcoma: outcome and prognostic factors following conservation surgery and radiation therapy. *Int J Radiat Oncol Biol Phys* 1996; 36(2):311-9.
17. Peison B, Benisch B, Williams MC. Retroperitoneal liposarcoma metastatic to scalp. *Arch Dermatol* 1978;114(9):1358-9.