

Recurrent Anaphylaxis and Atypical Chest Pain Due to Non-Ruptured Mediastinal Hydatid Cysts: Case Report

Rüptüre Olmamış Mediastinal Hidatid Kistlere Bağlı Tekrarlayan Anafilaksi ve Atipik Göğüs Ağrısı

Hüseyin DURSUN,^a
Cenk EKMEKÇİ,^a
Dilek ÖNCEL,^b
Barış KILIÇASLAN,^a
Cengiz SERT^c

Clinics of

^aCardiology,

^bRadiology,

^cCardiovascular Surgery,

Tepecik Training and Research Hospital,
İzmir

Geliş Tarihi/Received: 12.07.2013

Kabul Tarihi/Accepted: 28.09.2013

Yazışma Adresi/Correspondence:

Hüseyin DURSUN

Tepecik Training and Research Hospital,

Clinic of Cardiology, İzmir,

TÜRKİYE/TURKEY

husamdursun@hotmail.com

ABSTRACT Hydatid cyst disease is a zoonotic infection of humans, and is endemic to many parts of the world, particularly the Mediterranean region. Although lung and liver are the most common sites of the hydatidosis, mediastinal location of the disease has been demonstrated rarely. The cysts usually cause no symptoms, but in few cases anaphylactic reactions can occur with cyst rupture due to trauma. In extremely few cases, anaphylactic shock has been reported with non-ruptured hydatid cysts of liver. Our patient had recurrent episodes of anaphylaxis and atypical chest pain without any trauma, and the underlying pathology could not be diagnosed even though he was living in a region endemic for hydatid disease. To our knowledge this is the first case report in the literature with mediastinal unruptured hydatid cysts, and anaphylaxis attacks. We recommend that physicians, especially in endemic regions should be highly suspicious about hydatid cyst disease as a possible cause of recurrent anaphylactic reactions and atypical chest pain.

Key Words: Echinococcosis; anaphylaxis; chest pain

ÖZET Kist hidatid hastalığı dünyanın birçok yerinde özellikle de Akdeniz ülkelerinde endemik olarak görülen, hayvanlardan insana bulaş gösteren bir hastalıktır. Akciğer ve karaciğer en çok etkilenen organlar olsalar da, hastalık nadiren mediastende de gösterilmiştir. Kistler genellikle asemptomatiktir, ancak anafilaktik reaksiyonlar travmaya bağlı kist rüptürünün görüldüğü az sayıda vakada ortaya çıkmaktadır. Çok ender birkaç olguda ise karaciğerde rüptüre olmamış hidatik kistlere bağlı anafilaktik şok bildirilmiştir. Burada kist hidatik için endemik olan bir bölgede yaşamasına karşın tanısı konulamamış, travmanın eşlik etmediği, tekrarlayan anafilaksi atakları ve atipik göğüs ağrısı olan bir hastayı bildiriyoruz. Şu ana kadarki bilgilerimize göre olgumuz mediastende rüptüre olmamış kist hidatiğe bağlı anafilaksi atakları görülen ilk olgu sunumudur. Sonuçta, özellikle hastalığın endemik olduğu bölgelerdeki hekimlerin tekrarlayan anafilaksi atakları ve atipik göğüs ağrısı nedeni olarak kist hidatiği aklı getirmelerini önermekteyiz.

Anahtar Kelimeler: Ekinokokkozis; anafilaksi; göğüs ağrısı

For the video/videos of the article:



Türkiye Klinikleri J Case Rep 2014;22(4):277-80

H ydatid disease or Echinococcosis is caused by the larval form of *Echinococcus granulosus*. It is endemic to many parts of the world, particularly the Mediterranean region including Turkey, the Middle East, South America, Africa, New Zealand, and Australia.^{1,2} Although lung and liver are the most common sites of the hydatidosis, extrapulmonary location of the disease in the thorax is rarely seen. Intrathoracic extrapulmonary locations are generally the mediastinum, pleura, pericardium and chest wall.³ Cystic lesions cause symptoms via compressing ad-

Copyright © 2014 by Türkiye Klinikleri

adjacent organs or may be totally silent. Anaphylactic shock is a rare complication of hydatid cyst, which usually occurs after minor or major trauma.^{4,5} In extremely few cases, anaphylactic shock has been reported in patients without macroscopic rupture of the hydatid cysts.⁶⁻⁸ We present a patient with mediastinal hydatid cysts who developed recurrent anaphylaxis and chest pain without known trauma. To our knowledge this is the first case report in the literature with a rare location of unruptured hydatid cysts, and extremely rare anaphylaxis attacks.

CASE REPORT

A 36-year-old man was admitted to our clinic with a complaint of atypical chest pain, and exertional dyspnea for the last 6 months. There was no history of any chronic disease or any trauma. A detailed medical history revealed that the patient had 3 episodes of anaphylaxis in last year. The first anaphylactic episode was in October 2011, the second one in January 2012, and the last one occurred in October 2012. The episodes were beginning with a generalized pruritus, flushing, and shortness of breath. The second episode resolved with symptomatic antihistaminics in a public hospital, but the first and the third episodes were much more severe than the second episode with hypotension, tachycardia, cyanosis and required emergency treatment. After these attacks he admitted an internal medicine clinic. Complete blood count, routine blood chemistry, thyroid function tests, and chest X ray were within normal limits. Skin prick tests with common aeroallergens, and food allergens evaluating his atopic status were also normal. The etiologies of these attacks were not determined.

On physical examination he was not in acute cardiac distress with a regular pulse rate of 90 beats/min, and blood pressure of 130/70 mmHg. Auscultation of heart and lung fields were normal. There was no abnormality in electrocardiogram. But transthoracic echocardiography revealed multiple cystic lesions adjacent to right and left ventricles (Figure 1, Movie 1, 2). One of the cystic lesions had a compressive effect on right ventricle. So a computed tomography (CT) of the chest and upper

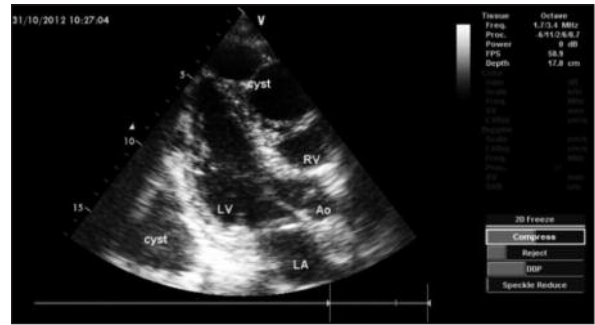


FIGURE 1: Transthoracic echocardiography of the patient reveals cystic lesions located posteriorly to left ventricle, and adjacent to apical portion of right ventricle. LV: Left ventricle; LA: Left atrium; Ao: Aorta; RV: Right ventricle.

abdomen was planned. The CT showed multiple cystic lesions (largest one 5,5 cm in diameter) at anterior mediastinum, beginning from paratracheal level down to subcarinal level and surrounding pericardium (Figure 2). There was no cyst in liver, spleen and lung parenchyma. Subsequently, a magnetic resonance imaging (MRI) was performed to show involvement of the pericardium. Both in T1 and T2-weighted sequences there was no involvement of pericardium. *E. granulosus* indirect hemagglutination assay, and total serum IgE were markedly positive in the patient.

A preoperative diagnosis of mediastinal multiple hydatid cysts was made and a median sternotomy was performed. In sternotomy, multiple macroscopically nonruptured cystic lesions located at the anterior mediastinum were removed (Figure 3). The diagnosis of hydatid cyst was confirmed by the pathologic examination of the resected material. There were no complications in the postoperative period and he was discharged 6 days after the operation. The antihelminthic therapy (10 mg/kg albendazole) was administered daily for a month postoperatively. There was no recurrence of the disease during a follow-up of one month.

DISCUSSION

Echinococcosis is a zoonotic infection caused by *Echinococcus* species. The disease is endemic to our country. Hydatid cysts have a predilection to locate in liver, and lungs. The disease rarely presents extrapulmonary in the thorax, and among the hydatid

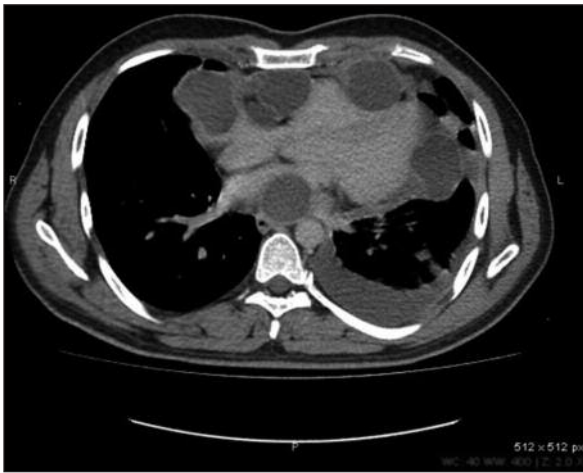


FIGURE 2: Computed tomography (CT) of the thorax demonstrates multiple cysts surrounding pericardium.

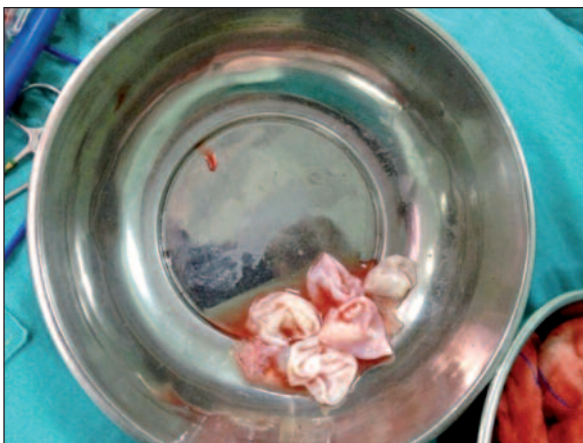

FIGURE 3: The photograph shows multiple hydatid cysts removed in the operation.

cyst series it has been reported between 5 to 6.2%. Intrathoracic extrapulmonary hydatid cyst may be found in chest wall, mediastinum, lobar fissure, diaphragm, and pleura.^{9,10}

Symptoms and complications of cyst depend on size, location and involvement of neighboring structures. Symptoms range from retrosternal and parasternal pain, cough, dysphagia to dyspnea or severe compression of the trachea and superior vena cava.¹¹ Hydatid cysts can rupture as a result of trauma or sometimes spontaneously, and after the macroscopic rupture of cyst an allergic reaction is evoked because of the spillage of the allergic contents of the cyst into the surrounding tissues. The response can be from a mild hyper-

sensitivity reaction to a fatal anaphylactic shock.^{5,12} However, there are few case reports in the literature indicating that anaphylactic episodes can also occur without macroscopic rupture of hydatid cyst.⁶⁻⁸

These episodes were recurrent in two of the reports. Giulekas et al. reported a patient with recurrent anaphylaxis. The diagnosis was hydatid cyst of liver, and in the operation small hydatid cysts with incomplete ruptures were observed.⁶ On the other side Gelincik et al. reported a 48 year old woman with 3 episodes of anaphylaxis. The patient was operated for hydatid cysts of liver, but five years after the first operation she had an anaphylactic episode again. The diagnosis was relapsing hydatid disease of liver, and in the second operation nonruptured two hepatic cysts were removed.⁸ Also at the autopsies of 2 patients who had died suddenly from severe anaphylaxis, it was concluded that non-ruptured cysts were suspected to be the cause of anaphylaxis.^{13,14}

Our patient had 3 episodes of anaphylaxis from mild to severe degree. Although some routine blood, and allergy tests were performed, hydatid cyst disease for the etiology of recurrent anaphylaxis was not taken into consideration. The patient admitted to our clinic for the compression effect of cysts on right ventricle of heart, and echocardiography revealed cystic lesions. In spite of the relatively low diagnostic value of indirect hemagglutinin test in pulmonary hydatid disease cases, it was markedly positive in our patient. Both CT, and MRI have valuable role in the diagnosis of the disease, and demonstrate the relation of the cysts to adjacent structures. Although hydatid cysts mostly locate in the liver and lungs, CT and MRI demonstrated multiple cysts in mediastinum, but interestingly there was no cyst in liver and lungs. In operation all of the cysts observed were intact, there was no apparent macroscopic rupture in any of them. So we concluded that the recurrent anaphylaxis were due to microscopic spillage of allergic contents into the circulation from cysts with high intracystic pressure.

To our knowledge this is the first case report in the literature of a patient with multiple medi-

astinal non-ruptured hydatid cysts with recurrent anaphylactic episodes. We recommend that physicians, especially in endemic regions should be highly suspicious about hydatid cyst disease as a possible cause of recurrent anaphylactic reactions

and atypical chest pain. Therefore, beside routine tests for allergens, echinococcosis serology, abdominal ultrasonography, chest X-ray, and if required transthoracic echocardiography should be done.

REFERENCES

1. Harlaftis NN, Aletras HA, Symbas PN. Hydatid disease of the lung. In: Shields TW, LoCicero J III, Ponn RB, Rusch VW, eds. *General Thoracic Surgery*. 7th ed. Philadelphia: Lippincott Williams&Wilkins; 2005.p.1298-308.
2. Burgos R, Varela A, Castedo E, Roda J, Montero CG, Serrano S, et al. Pulmonary hydatidosis: surgical treatment and follow-up of 240 cases. *Eur J Cardiothorac Surg* 1999;16(6): 628-34; discussion 634-5.
3. Oğuzkaya F, Akçali Y, Kahraman C, Emiroğullari N, Bilgin M, Sahin A. Unusually located hydatid cysts: intrathoracic but extrapulmonary. *Ann Thorac Surg* 1997;64(2):334-7.
4. Derici H, Tansug T, Reyhan E, Bozdağ AD, Nazlı O. Acute intraperitoneal rupture of hydatid cysts. *World J Surg* 2006;30(10):1879-83; discussion 1884-5.
5. Mooraki A, Rahbar MH, Bastani B. Spontaneous systemic anaphylaxis as an unusual presentation of hydatid cyst: report of two cases. *Am J Trop Med Hyg* 1996;55(3):302-3.
6. Giulekas D, Papacosta D, Papaconstantinou C, Barbarousis D, Angel J. Recurrent anaphylactic shock as a manifestation of echinococcosis. Report of a case. *Scand J Thorac Cardiovasc Surg* 1986;20(2):175-7.
7. Sanei B, Hashemi SM, Mahmoudieh M. Anaphylactic shock caused by nonruptured hydatid cyst of the liver. *J Gastrointest Surg* 2008;12(12):2243-5.
8. Gelincik A, Ozşeker F, Büyükoztürk S, Colakoğlu B, Dal M, Alper A. Recurrent anaphylaxis due to non-ruptured hepatic hydatid cysts. *Int Arch Allergy Immunol* 2007;143(4): 296-8.
9. Dakak M, Yücel O, Kavaklı K, Çaylak H, Gözübüyük A, Sapmaz E, et al. Intrathoracic extrapulmonary hydatid cysts: Review of 33 cases. *Trakya Univ Tıp Fak Derg* 2009;26(2): 125-9.
10. Isitmangil T, Sebit S, Tunc H, Gorur R, Erdik O, Kunter E, et al. Clinical experience of surgical therapy in 207 patients with thoracic hydatidosis over a 12-year-period. *Swiss Med Wkly* 2002;132(37-38):548-52.
11. Thameur H, Chenik S, Abdelmoulah S, Bey M, Hachicha S, Chemingui M, et al. [Thoracic hydatidosis. A review of 1619 cases]. *Rev Pneumol Clin* 2000;56(1):7-15.
12. Pedrosa I, Saiz A, Arrazola J, Ferreirós J, Pedrosa CS. Hydatid disease: radiologic and pathologic features and complications. *Radiographics* 2000;20(3):795-817.
13. Chadly A, Krimi S, Mghirbi T. Cardiac hydatid cyst rupture as cause of death. *Am J Forensic Med Pathol* 2004;25(3):262-4.
14. Büyük Y, Turan AA, Uzün I, Aybar Y, Cin O, Kurnaz G. Non-ruptured hydatid cyst can lead to death by spread of cyst content into bloodstream: an autopsy case. *Eur J Gastroenterol Hepatol* 2005;17(6):671-3.