

Beneficial Effect of Doxazosin on Renal Apoptosis After Partial Bladder Outlet Obstruction

Doksazosinin Kısmi Mesane Çıkışı Obstrüksiyonu Sonrasında Renal Apoptozis Üzerine Yararlı Etkisi

Ömer KUTLU,^a
 Mehmet YALÇINKAYA,^a
 Gülsüm Özlem ELPEK, MD,^b
 İsmail Türker KÖKSAL, MD,^a
 Erdal KUKUL, MD^a

Departments of ^aUrology,
^bPathology,
 Akdeniz University Faculty of Medicine,
 Antalya

Geliş Tarihi/Received: 09.06.2009
 Kabul Tarihi/Accepted: 05.10.2009

Yazışma Adresi/Correspondence:
 İsmail Türker KÖKSAL, MD
 Akdeniz University Faculty of Medicine,
 Department of Urology, Antalya,
 TÜRKİYE/TURKEY
 tkoksal@akdeniz.edu.tr

ABSTRACT Objective: It is not known whether inhibition of $\alpha 1$ -adrenoreceptor in a rat model of partial bladder outlet obstruction (BOO) causes decrease in tubular and glomerular cell death by apoptosis and prevention of subsequent inflammation and fibrosis. The aim of this study was to demonstrate the relationship between apoptosis and doxazosin ($\alpha 1$ -adrenoreceptor antagonist) in rat kidneys damaged by partial BOO. **Material and Methods:** A total of 45 adult female Wistar rats, with a mean weight of 250 g were randomly allocated to four experimental groups as: sham-operated rats (10 rats), sham-operated rats treated with doxazosin (10 rats), partial BOO group (14 rats), and partial BOO group treated with doxazosin (11 rats). Partial BOO was surgically induced. Detection of cell apoptosis was done by TUNEL assay. **Results:** This investigation revealed increased apoptosis in both tubular and glomerular cells of rats with partial BOO. Furthermore, the results of this study demonstrated that doxazosin treatment of rats reduced apoptosis in tubular and glomerular cells in both the controls and the rats with partial BOO. **Conclusion:** We believe that our observation of decreased apoptosis in both tubular and glomerular cells of rats with partial BOO might be useful to gain new insight into the therapeutic effect of doxazosin.

Key Words: Apoptosis; kidney; doxazosin

ÖZET Amaç: Mesane çıkışı obstrüksiyonu (MÇO) oluşturulan sıçan modelinde $\alpha 1$ adrenoreseptör inhibisyonunun apoptozis ile tübüler ve glomerüler hücre ölümüne yol açıp açmadığı ve sonrasında gelişen inflamasyon ve fibrozişi engelleyip engellemediği bilinmemektedir. Dolayısıyla, bu çalışmanın amacı kısmi MÇO ile hasarlandırılmış sıçan böbreklerinde apoptozis ile doksazosin (alfa 1 reseptör antagonisti) arasındaki ilişkiyi göstermektir. **Gereç ve Yöntemler:** Ortalama 250 gram ağırlığındaki toplam 45 adet dişi Wistar sıçanları 4 deneysel gruba randomize edildi: sham operasyonlu sıçanlar (10 sıçan), doksazosin ile tedavi edilen sham operasyonlu sıçanlar (14 sıçan), kısmi MÇO grubu (14 sıçan), ve doksazosin ile tedavi edilen kısmi MÇO grubu. Sıçanlardaki kısmi MÇO cerrahi olarak indüklendi. Hücre apoptozisi TUNEL analizi tespit edildi. **Bulgular:** Bu araştırma kısmi MÇO'lu sıçanlarda hem tübüler hem de glomerüler hücrelerde artmış apoptozisi göstermiştir. Ayrıca, bu çalışmanın sonuçları doksazosinin kısmi MÇO'lu sıçanlarda ve kontrol grubunu oluşturan sıçanlarda tübüler ve glomerüler hücrelerde apoptozisi azalttığını göstermektedir. **Sonuç:** Kısmi MÇO'lu sıçanların hem tübüler hem de glomerüler hücrelerinde gözlemlediğimiz azalmış apoptozisin doksazosinin tedavi edici etkisine yeni bir görüş kazandırması açısından faydalı olabileceğine inanıyoruz.

Anahtar Kelimeler: Apoptoz; böbrek; doksazosin

Türkiye Klinikleri J Med Sci 2010;30(5):1575-80

Lower urinary tract symptoms (LUTS) include urinary frequency, hesitancy, weak urinary stream, urgency and nocturia. They are common in older men and are usually associated with benign prostate hyperplasia (BPH), benign prostate enlargement, benign prostatic obstruction (BPO) or bladder outlet obstruction (BOO). BPH and BOO may lead to increased post-

void residual volume, upper urinary tract dilatation and ultimately renal failure. Of patients undergoing prostatectomy, 15% to 30% present with impaired renal function.¹⁻³ Upper tract dilatation or hydronephrosis is consistent with chronic renal failure (CRF) from obstructive uropathy due to chronic urinary retention. Kidneys with urinary obstruction in both humans and experimental animals develop progressive tubulointerstitial injury.⁴⁻⁶ Tubular cell apoptosis has recently emerged as a crucial lesion that may be pathogenetically related to other tubular changes and be responsible for the profound renal tissue loss seen in obstructed kidneys.^{5,6} Interstitial changes, including fibrosis, inflammatory cell infiltrate, and vascular remodeling, develop in kidneys with urinary obstruction as well, have been shown to correlate with interstitial cell apoptosis.⁵ These observations strongly imply a disturbance of tubular and interstitial cell cycles, including an increased apoptosis of these cells in the pathogenesis of obstructive uropathy.

In the management of BPH symptoms, targeting the predominant $\alpha 1$ -adrenoceptors within the prostatic stroma with $\alpha 1$ -adrenoceptor antagonists such as doxazosin to induce relaxation of smooth muscle tone in the prostate and lower urinary tract has proven to be an effective treatment strategy, providing long-term relief of LUTS.^{7,8} In recent years, rapidly evolving evidence has implicated doxazosin-induced prostate smooth muscle cell apoptosis as a potential mechanism underlying the long-term therapeutic responses to doxazosin in patients with BPH.⁹⁻¹¹ To our knowledge, the relationship between apoptosis and $\alpha 1$ -adrenoceptor antagonists in the kidney has not yet been reported. The aim of this study was to demonstrate the relationship between apoptosis and doxazosin ($\alpha 1$ -adrenoceptor antagonist) in rat kidneys damaged by partial BOO, and to gain new insight into the therapeutic effect of doxazosin.

MATERIAL AND METHODS

ANIMALS

A total of 45 adult female (mean 250 g) Wistar rats were used in this study. The experimental protocol was approved by the Animal Ethics Committee of

Akdeniz University, Turkey. The animals were handled according to internationally accepted principles for the care of laboratory animals. The rats were maintained under standard laboratory conditions with a 12:12 hr light:dark cycle, with free access to food pellets and tap water. They were separated into four groups as follows: Group 1: sham (control) group (10 rats); Group 2: a sham with that received an $\alpha 1$ -adrenoceptor antagonist (doxazosin, 10 mg/kg) (10 rats); Group 3: partial BOO group (14 rats); Group 4: a group with partial BOO that received an $\alpha 1$ -adrenoceptor antagonist (doxazosin, 10 mg/kg, 11 rats).

SURGICAL PROCEDURE

Rats were anesthetized with intramuscular ketamine hydrochloride 50 mg/kg and xylazine 15 mg/kg. The bladder was approached and the proximal urethra exposed through a lower midline incision. A 2/0 silk ligature was placed around the urethra and tied snugly in the presence of an intraluminal indwelling 3Fr urethral catheter. After tying the knot, the catheter was removed and the bladder was repositioned. After catheter removal, the abdominal wall was closed with 2/0 chromic catgut sutures. Similarly, a sham operation was performed consisting of surgically exposing the bladder and proximal urethra. A sterile silk ligature was passed beneath the proximal urethra and removed without placing knots. The abdomen was closed subsequently. All rats were treated postoperatively with a single-dose of antibiotics (gentamicin, 5 mg/kg) and analgesics (tramadol hydrochloride, 20 mg/kg). In groups 2 and 4, an $\alpha 1$ -adrenoceptor antagonist (doxazosin, 10 mg/kg) was administered orally every day via a 6Fr feeding tube, starting immediately after recovery from surgery for a period of 15 days.¹² At the end of this period, the rats were anesthetized their right kidneys were removed for evaluation of apoptosis and then they were sacrificed by cervical dislocation.

EVALUATION OF APOPTOSIS

Detection of cell apoptosis was detected by TUNEL assay (Roche, Germany), according to the manufacturer's protocol. Negative controls were performed by substituting distilled water for the TdT enzyme.

To quantify the incidence of apoptosis in each group, the number of TUNEL-positive cell nuclei was calculated. Ten randomly selected areas (at x 400) in each preparation were counted separately, and the mean of these 10 counts was taken as the final result. Separate apoptotic index values for glomerular cells and tubular cells were calculated in each kidney.

Statistical analysis

Statistical analyses between groups were performed by the one-way ANOVA and Newman-Keuls Multiple Comparison Test (Prism 3.0, Graphpad Software Inc.), and probability values less than 0.05 were considered significant. The values are presented as the mean \pm standard deviation and median.

RESULTS

All specimens from all four groups showed TUNEL staining (Figure 1). Apoptotic indices of the kidney in glomerular and tubular components of group 3 (54.4 ± 19.9 , median:54.93 and 65.3 ± 16.6 , median:65.84, respectively) were significantly higher than those of group 1 (32.8 ± 6.3 , median:33.40 and 40.1 ± 5.9 , median:40.92, respectively), ($p < 0.001$, $p < 0.001$, Figure 2 and 3). After 15 days of doxazosin treatment in partial BOO (group 4), apoptotic indices of the kidney in glomerular and tubular components (36.9 ± 5.7 median:37.86 and 51.2 ± 13.9 , median:51.28 respectively) were significantly higher than those of group 2 (19.7 ± 4.2 median:19.15 and 28.7 ± 7.4 , median:31.88 respectively) ($p < 0.01$ and $p < 0.001$ respectively, Figures 2 and 3). Apoptotic indices of the kidney in glomerular and tubular components of group 4 (36.9 ± 5.7 , median:37.86 and 51.2 ± 13.9 , median: 51.28 respectively) were significantly lower than those of group 3 (54.4 ± 19.9 , median: 54.93 and 65.3 ± 16.6 , median:65.84, respectively) ($p < 0.01$, $p < 0.01$ respectively, Figures 2 and 3). In samples taken after 15 days of doxazosin treatment in addition to sham, apoptotic indices of the kidney in glomerular and tubular components (19.78 ± 4.2 , median: 19.35 and 28.7 ± 7.4 , median: 28.14, respectively) were significantly lower than those of sham (32.81 ± 6.3 , median: 34.42 and 40.17 ± 5.9 , median: 39.00, respectively) ($p < 0.05$, $p < 0.05$, respectively, Figure 2 and 3).

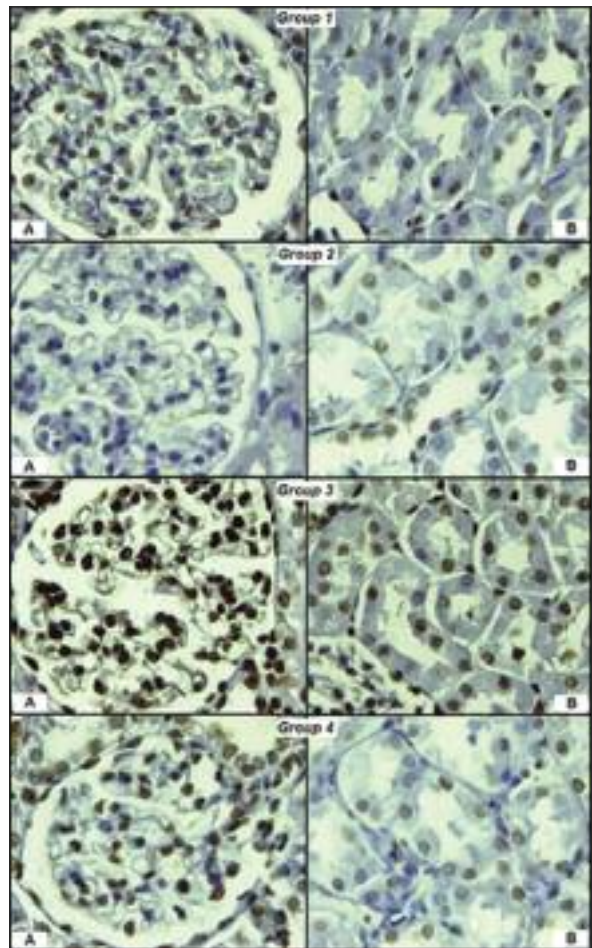


FIGURE 1: Detection of apoptotic cells in groups 1 - 4 (A. TUNEL-stained apoptotic glomerular cells, B. TUNEL-stained apoptotic tubular cells).

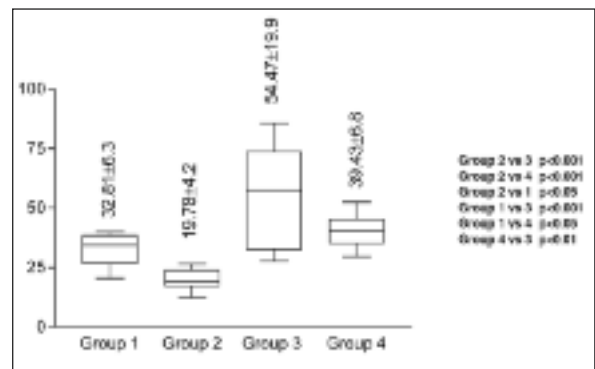


FIGURE 2: Apoptotic index (AI) according to groups for glomerular component of the kidney.

DISCUSSION

The broader term “obstructive uropathy” can be used to indicate any obstruction to urinary flow occurring between the renal pelvis and the urethra

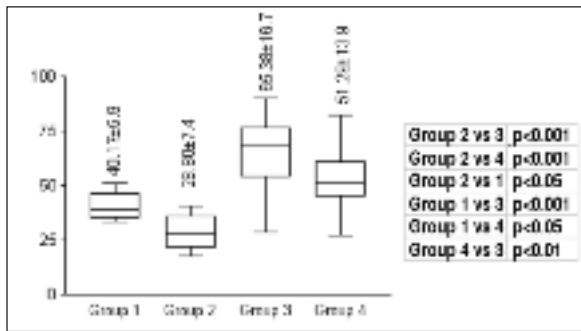


FIGURE 2: Apoptotic index (AI) according to groups for tubular component of the kidney.

that causes a development of hydronephrosis and associated renal impairment. Obstruction of urine outflow results in a constellation of renal parenchymal changes, collectively called chronic obstructive uropathy (COU). These changes include tubular atrophy, interstitial fibrosis, and interstitial inflammation, all of which are associated with progressive renal tissue loss.^{5,13} CRF is a well-described complication of obstructive BPH. Although multiple mechanisms have been proposed to explain an association between BPH and CRF,³ chronic urinary retention is considered as the dominant mechanism by which BPH can cause CRF. Mounting experimental data suggest that apoptosis contributes to the development of renal injury through cellular deletion mechanism.¹⁴ Truong et al. demonstrated that renal tubular and interstitial cells undergo pronounced apoptosis during the course of COU. Our findings have also indicated that partial BOO increased apoptosis not only in tubules but also in glomeruli in the rat kidney. How the general mechanism of apoptosis, gleaned mostly from *in vitro* studies, is relevant to that of renal cell apoptosis in COU has not been evaluated. A large number of environmental factors known to cause apoptosis, such as hypoxia, stretching, ischemia, cytokines, growth factors, angiotensin II, and reactive oxygen species, are all activated during the course of COU, but it remains unclear whether they are, indeed, the initiators of apoptosis in this condition.^{5,15,16} Understanding the molecular control of renal cell apoptosis in COU should not only help elucidate its pathogenesis, but might also be pertinent to the pathogenesis of chronic renal tubulointerstitial injury in

general. Although the mechanism and the essential components of apoptosis remain to be elucidated, it is generally accepted that apoptosis is initiated by a direct physical interaction between a variety of death signals in the extracellular environment and their death receptors, including Fas, tumor necrosis factor receptor-1 (TNFR-1), and TNF-related apoptosis inducing ligand (TRAIL) receptor, which are strategically situated on the cell membrane. Apoptosis is initiated when these receptors are engaged by their ligands, that is, Fas ligand, TNF, and TRAIL, respectively, which are either free in the circulation or bound to the membrane of cytotoxic effector cells.¹⁷⁻²⁰ Nuclear factor-kappa B (NF- κ B) activation, in addition to an increase in the mRNA levels of TNF- α , TNFR1, caspase 8, and caspase 3, has been documented in rat models of renal obstruction.^{6,13,21} TNF- α has recently emerged as an important mediator of both obstruction-induced renal fibrosis and cellular apoptosis.^{22,23} Stretching of human tubular cells increases their susceptibility to TNF- α -induced apoptosis, which is caspase-dependent.²⁴ Angiotensin II upregulates TNF- in the rat kidney with unilateral ureteral obstruction (UUO).²² Many studies have demonstrated that obstructive nephropathy leads to activation of the intrarenal renin-angiotensin system. Angiotensin II has a central role in the initiation and progression of obstructive nephropathy both directly and indirectly by stimulating production of molecules that contribute to renal injury.²⁵ The increased production of angiotensin II in the obstructed kidney is thought to contribute to tubular cell death via the induction of transforming growth factor (TGF- β 1) and the production increases in oxidative stress.²⁶ TGF- β 1 is known to promote apoptosis following renal injury in both *in vivo* and *in vitro* models.^{25,27} Mechanical stretching of rat tubular cells stimulates expression of TGF- β 1, which in turn promotes tubular apoptosis by a p38 MAP kinase-dependent mechanism.²⁷ As well as promoting apoptosis, angiotensin II is also documented to have a role in fibrosis, especially in the kidney, where it is believed to promote the fibrotic response principally via the activation of TGF- β 1.²⁸ It is well known that there are multiple interactions between the renin-angiotensin system and the sympathetic nervous system.

Stimulation of the sympathetic nervous system leads to renin secretion and angiotensin II generation.²⁹ The effects of the pressor substances of these two systems, angiotensin II and norepinephrine, are triggered by their interaction with specific receptors on the vascular wall. It has been demonstrated that α 1-adrenergic receptors mediate sympathetic vasoconstriction of the blood vessel, however most vascular angiotensin II receptors in all species studied to date are mainly type 1 angiotensin II receptors (AT₁) that mediate contractile and growth effects of angiotensin II in vascular smooth muscle.³⁰⁻³² It has been demonstrated that AT₁ is the predominant receptor in the rat and human kidney and seems to account for all the known physiological consequences of angiotensin II binding.³³

α 1-adrenoreceptor antagonists are clinically effective in the relief of BPH symptoms via their ability to selectively antagonize the α 1a-adrenoreceptors.³⁴ Induction of apoptosis in response to doxazosin is well documented in benign and malignant prostate epithelial cells and human prostate clinical specimens at intracellular concentrations comparable with the therapeutic doses.⁹ Male SCID mice were inoculated with malignant, androgen-independent PC-3 prostate cells. A week later they were administered various oral doses of doxazosin (0, 3, 10 or 100 mg/kg) and were sacrificed after 14 days. Doxazosin administration in tumor-bearing hosts (via oral gavage; at a dose of 3 mg/kg) resulted in a notable decrease in the tumor volume of prostate tumor xenografts when compared to the vehicle control-treated animals. Administration of doxazosin at higher concentrations (10-100 mg/kg) did not have any further effect on tumor suppres-

sion.³⁵ Suppression of prostate growth proceeds via an α 1-adrenoceptor-independent mechanism by activation of latent apoptotic machinery by effector (Smad) activation of TGF- β 1 signaling and I κ B α .³⁶ Doxazosin treatment of benign and malignant prostate epithelial cells leads to a significant increase in death-inducing signaling complex (DISC) formation and subsequent apoptosis via caspase-3 activation.³⁷ More recent evidence established the ability of doxazosin to induce anoikis in prostate epithelial and endothelial cells.³⁸ The apoptotic effect of doxazosin provides a molecular basis for therapeutic targeting of prostate cancer, as well as benign disease, potentially via anoikis. Interestingly, benign prostate cells seem to be more sensitive to the apoptotic effect of doxazosin than tumor cells.³⁸ We also found in this study that treatment with doxazosin in the sham group significantly decreased apoptosis in glomerular and tubular cells.

In the literature, it is not known whether inhibition of α 1-adrenoreceptor in a rat model of partial BOO causes a decrease in tubular and glomerular cell death by apoptosis and a prevents of subsequent inflammation and fibrosis. The results of this study demonstrated that doxazosin treatment of rats reduced apoptosis in tubular and glomerular cells both in the controls and the partial BOO rats. This is the first study that showed α 1-adrenoreceptor antagonist (doxazosin) decreased apoptosis in tubular and glomerular cells in rat kidneys with partial BOO. We believe that this observation of decreased apoptosis in tubular and glomerular cells of rats with partial BOO may be useful in order to gain new insight into the therapeutic effect of doxazosin.

REFERENCES

- Madersbacher S, Alivizatos G, Nordling J, Sanz CR, Emberton M, de la Rosette JJ. EAU 2004 guidelines on assessment, therapy and follow-up of men with lower urinary tract symptoms suggestive of benign prostatic obstruction (BPH guidelines). *Eur Urol* 2004;46(5): 547-54.
- Ponholzer A, Temml C, Obermayr RP, Rauchenwald M, Madersbacher S. The association between lower urinary tract symptoms and renal function in men: a cross-sectional and 5-year longitudinal analysis. *J Urol* 2006;175 (4):1398-402.
- Rule AD, Lieber MM, Jacobsen SJ. Is benign prostatic hyperplasia a risk factor for chronic renal failure? *J Urol* 2005;173(3): 691-6.
- Truong LD, Petrusavska G, Yang G, Gurpinar T, Shappell S, Lechago J, et al. Cell apoptosis and proliferation in experimental chronic obstructive uropathy. *Kidney Int* 1996; 50(1):200-7.
- Truong LD, Sheikh-Hamad D, Chakraborty S, Suki WN. Cell apoptosis and proliferation in obstructive uropathy. *Semin Nephrol* 1998;18 (6):641-51.
- Truong LD, Choi YJ, Tsao CC, Ayala G, Sheikh-Hamad D, Nassar G, et al. Renal cell apoptosis in chronic obstructive uropathy: the roles of caspases. *Kidney Int* 2001;60(3):924-34.

7. Chapple CR. Alpha adrenoceptor antagonists in the year 2000: is there anything new? *Curr Opin Urol* 2001;11(1):9-16.
8. Djavan B, Marberger M. A meta-analysis on the efficacy and tolerability of alpha1-adrenoceptor antagonists in patients with lower urinary tract symptoms suggestive of benign prostatic obstruction. *Eur Urol* 1999;36(1):1-13.
9. Kyprianou N. Doxazosin and terazosin suppress prostate growth by inducing apoptosis: clinical significance. *J Urol* 2003;169(4):1520-5.
10. Kyprianou N, Litvak JP, Borkowski A, Alexander R, Jacobs SC. Induction of prostate apoptosis by doxazosin in benign prostatic hyperplasia. *J Urol* 1998;159(6):1810-5.
11. Alberti C. Apoptosis induction by quinazoline-derived alpha1-blockers in prostate cancer cells: biomolecular implications and clinical relevance. *Eur Rev Med Pharmacol Sci* 2007;11(1):59-64.
12. de la Chica-Rodríguez S, Cortés-Denia P, Ramírez-Expósito MJ, de Saavedra JM, Sánchez-Agosta R, Pérez Mdel C, et al. Doxazosin blockade of alpha 1-adrenergic receptors increases rat serum progesterone levels: a putative role of ovarian angiotensin III in steroidogenesis. *Fertil Steril* 2007;88(4 Suppl): 1071-5.
13. Choi YJ, Baranowska-Daca E, Nguyen V, Koji T, Ballantyne CM, Sheikh-Hamad D, et al. Mechanism of chronic obstructive uropathy: increased expression of apoptosis-promoting molecules. *Kidney Int* 2000;58(4):1481-91.
14. Ortiz A, Lorz C, Justo P, Catalan MP, Egido J. Contribution of apoptotic cell death to renal injury. *J Cell Mol. Med* 2001;5(1):18-32.
15. Wyllie AH. Apoptosis: an overview. *Br Med Bull* 1997;53(3):451-65.
16. Peter ME, Heufelder AE, Hengartner MO. Advances in apoptosis research. *Proc Natl Acad Sci USA* 1997;94(24):12736-7.
17. Koksai IT, Sanlioglu AD, Karacay B, Griffith TS, Sanlioglu S. Tumor necrosis factor-related apoptosis inducing ligand-R4 decoy receptor expression is correlated with high Gleason scores, prostate-specific antigen recurrence, and decreased survival in patients with prostate carcinoma. *Urol Oncol* 2008;26(2): 158-65.
18. Sanlioglu AD, Koksai IT, Karacay B, Baykara M, Luleci G, Sanlioglu S. Adenovirus-mediated IKKbetaKA expression sensitizes prostate carcinoma cells to TRAIL-induced apoptosis. *Cancer Gene Ther* 2006;13(1):21-31.
19. Sanlioglu AD, Koksai IT, Ciftcioglu A, Baykara M, Luleci G, Sanlioglu S. Differential expression of TRAIL and its receptors in benign and malignant prostate tissues. *J Urol* 2007;177(1):359-64.
20. Sanlioglu AD, Karacay B, Koksai IT, Griffith TS, Sanlioglu S. DcR2 (TRAIL-R4) siRNA and adenovirus delivery of TRAIL (Ad5hTRAIL) break down in vitro tumorigenic potential of prostate carcinoma cells. *Cancer Gene Ther* 2007;14(12):976-84.
21. Morrissey JJ, Klahr S. Rapid communication. Enalapril decreases nuclear factor kappa B activation in the kidney with ureteral obstruction. *Kidney Int* 1997;52(4):926-33.
22. Guo G, Morrissey J, McCracken R, Tolley T, Liapis H, Klahr S. Contributions of angiotensin II and tumor necrosis factor-alpha to the development of renal fibrosis. *Am J Physiol Renal Physiol* 2001;280(5): F777-85.
23. Misseri R, Meldrum DR, Dinarello CA, Dagher P, Hile KL, Rink RC, et al. TNF-alpha mediates obstruction-induced renal tubular cell apoptosis and proapoptotic signaling. *Am J Physiol Renal Physiol* 2005;288(2): F406-11.
24. Power RE, Doyle BT, Higgins D, Brady HR, Fitzpatrick JM, Watson RW. Mechanical deformation induced apoptosis in human proximal renal tubular epithelial cells is caspase dependent. *J Urol* 2004;171(1):457-61.
25. Docherty NG, O'Sullivan OE, Healy DA, Fitzpatrick JM, Watson RW. Evidence that inhibition of tubular cell apoptosis protects against renal damage and development of fibrosis following ureteric obstruction. *Am J Physiol Renal Physiol* 2006;290(1):F4-13.
26. Bhaskaran M, Reddy K, Radhakrishnan N, Franki N, Ding G, Singhal PC. Angiotensin II induces apoptosis in renal proximal tubular cells. *Am J Physiol Renal Physiol* 2003;284(5):F955-65.
27. Dai C, Yang J, Liu Y. Transforming growth factor-beta1 potentiates renal tubular epithelial cell death by a mechanism independent of Smad signaling. *J Biol Chem* 2003;278(14): 12537-45.
28. Wu LL, Cox A, Roe CJ, Dziadek M, Cooper ME, Gilbert RE. Transforming growth factor beta 1 and renal injury following subtotal nephrectomy in the rat: role of the renin-angiotensin system. *Kidney Int* 1997;51(5):1553-67.
29. DiBona GF. Sympathetic nervous system influences on the kidney. Role in hypertension. *Am J Hypertens* 1989;2(3 Pt 2):119S-24S.
30. Chang RS, Lotti VJ. Angiotensin receptor subtypes in rat, rabbit and monkey tissues: relative distribution and species dependency. *Life Sci* 1991;49(20):1485-90.
31. Wong PC, Price WA, Chiu AT, Duncia JV, Carini DJ, Wexler RR, et al. Nonpeptide angiotensin II receptor antagonists. VIII. Characterization of functional antagonism displayed by DuP 753, an orally active antihypertensive agent. *J Pharmacol Exp Ther* 1990;252(2): 719-25.
32. Drew GM, Whiting SB. Evidence for two distinct types of postsynaptic alpha-adrenoceptor in vascular smooth muscle in vivo. *Br J Pharmacol* 1979;67(2):207-15.
33. Sechi LA, Grady EF, Griffin CA, Kalinyak JE, Schambelan M. Distribution of angiotensin II receptor subtypes in rat and human kidney. *Am J Physiol* 1992;262(2 Pt 2): F236-40.
34. Kirby RS, Pool JL. Alpha adrenoceptor blockade in the treatment of benign prostatic hyperplasia: past, present and future. *Br J Urol* 1997;80(4):521-32.
35. Kyprianou N, Benning CM. Suppression of human prostate cancer cell growth by alpha1-adrenoceptor antagonists doxazosin and terazosin via induction of apoptosis. *Cancer Res* 2000;60(16):4550-5.
36. Partin JV, Anglin IE, Kyprianou N. Quinazoline-based alpha 1-adrenoceptor antagonists induce prostate cancer cell apoptosis via TGF-beta signalling and I kappa B alpha induction. *Br J Cancer* 2003;88(10):1615-21.
37. Garrison JB, Kyprianou N. Doxazosin induces apoptosis of benign and malignant prostate cells via a death receptor-mediated pathway. *Cancer Res* 2006;66(1):464-72.
38. Keledjian K, Kyprianou N. Anoikis induction by quinazoline based alpha 1-adrenoceptor antagonists in prostate cancer cells: antagonistic effect of bcl-2. *J Urol* 2003;169(3):1150-6.