

A Case of Extensive Allergic Fungal Sinusitis Mimicking Malignancy in a Pediatric Patient Caused by a *Bipolaris* Species: Differential Diagnosis

Çocuk Hastada Bir *Bipolaris* Türünün Neden Olduğu Maligniteyi Taklit Eden Yaygın Alerjik Fungal Sinüzit Olgusu

Ramazan GÜMRAL, MD,^a
Fuat TOSUN, MD,^b
Mehmet Ali SARAÇLI, MD,^c
Ayhan ÖZCAN, MD,^d
Şinasi Taner YILDIRAN, MD^c

Departments of ^aMicrobiology and Clinical Microbiology,
^bOtorhinolaryngology,
^cMedical Mycology and
^dPathology,
Gülhane Military Medical Academy,
Ankara

Geliş Tarihi/Received: 30.07.2008
Kabul Tarihi/Accepted: 24.11.2008

This report was presented in
5th National Congress on Fungal Diseases
and Clinical Mycology, 2007, Çanakkale,
Turkey.

Yazışma Adresi/Correspondence:
Mehmet Ali SARAÇLI, MD
Gülhane Military Medical Academy,
Department of Medical Mycology,
Ankara,
TÜRKİYE/TURKEY
masaracli@gata.edu.tr

ÖZET Alerjik fungal sinüzit atopik bireylerde aşırı duyarlılık reaksiyonundan kaynaklanan invaziv olmayan bir mantar hastalığı şeklindedir. Etiyolojik etkenleri öncelikle esmer mantarlar olup, kronik sinüzit nedenlerinden biri olarak giderek artan oranda tanımlanmaktadır. Bu makalede Iraklı bir hastada, Türkiye’de tanı konmuş ve belgelenmiş, bir *Bipolaris* türünün neden olduğu ilk alerjik fungal sinüzit olgusu sunulmuştur. Hasta 13 yaşında ve sağlıklı bir erkek çocuktu. Tanı, paranazal sinüslerin bilgisayarlı tomografi (BT) taraması ve cerrahi materyalin histolojik ve kültür yöntemleri ile incelenmesi ile kondu. BT incelemesinde, sağ etmoid ve sfenoid sinüs duvarlarında maligniteyi taklit eden yaygın kemik doku erozyonu gözlemlendi. Örneklerin kültüründe saptanan küf üremesi tanısal mikroskopik görünümüne göre bir *Bipolaris* türü olarak tanımlandı. Cerrahi girişim ve topikal kortikosteroid tedavisi sonrasında hastanın postoperatif dördüncü ay kontrollerinde tam olarak iyileşmiş olduğu görüldü.

Anahtar Kelimeler: Sinüzit, aşırı duyarlılık, mantarlar, endoskopi

ABSTRACT Allergic fungal sinusitis is a form of non-invasive fungal disease resulting from hypersensitivity reaction in atopic individuals. It is increasingly recognized as a cause of chronic sinusitis, with the primary etiologic agents being members of the dematiaceous fungi. Here, we present the first documented case of allergic fungal sinusitis due to a *Bipolaris* species, diagnosed in Turkey, in an Iraqi patient. The patient was a 13-year-old male otherwise healthy. Diagnosis was made by computerized tomography (CT) scanning images of the paranasal sinuses, histological examination and culture of the surgical material. CT revealed extensive bone erosion of the right ethmoid and sphenoid sinus walls, resembling malignancy. Culture of the specimen yielded a mold growth which was identified as a *Bipolaris* species with diagnostic microscopic appearance. After surgical intervention and topical corticosteroid therapy, the patient recovered completely at postoperative month four.

Key Words: Sinusitis, hypersensitivity, fungi, endoscopy

Türkiye Klinikleri J Med Sci 2009;29(2):558-61

Allergic fungal sinusitis (AFS) is the most common form of fungal rhinosinusitis, accompanied with copious extramucosal mucin, with abundant eosinophils. *Aspergillus* species account for only about 15% of AFS cases. Additionally, Dematiaceous fungi from the family of *Pleosporaceae*, especially species of the genera *Bipolaris* (*Drechslera*), *Alternaria*, *Curvularia* and *Exserohilum*, are more common etiologic agents of AFS than *Aspergillus* spp.¹

Here, we present the first documented case of AFS caused by a *Bipolaris* species in Turkey, in a immunocompetent male Iraqi patient presenting with extensive bone erosion mimicking malignancy.

CASE REPORT

In December 2006, a 13-year-old male patient who has been suffering from nasal obstruction and headache for more than 5 years was admitted to the department of otorhinolaryngology head and neck surgery. On physical examination, exophthalmus was detected on the right side. His face had asymmetric appearance due to expansion of the right maxilla and right side of the nasal vault. Anterior rhinoscopy revealed septal deviation to the left side and the right nasal passage was filled with soft tissue. He was otherwise healthy. Computerized tomography (CT) of the paranasal sinuses showed soft tissue density, occupying the right ethmoid, maxillary and sphenoid sinuses with bone erosion of the sinus walls and hyperdense areas within (Figure 1). Punch biopsy from the intranasal mass revealed inflammatory polyposis. The patient underwent endoscopic sinus surgery after informed consent was obtained. Total sphenoidectomy was performed on the right side. After nasal polypectomy, mud like, sticky material, filling the en-

tire ethmoid and sphenoid sinuses on the right side was removed. A part of the surgical material taken from the sinuses was sent to the departments of microbiology and pathology. Histopathologic and histochemical (Grocott's Methenamine Silver stained) examination of the biopsy specimens revealed irregular septate fungal hyphae in mucoid substance (Figure 2A-D), and clusters of eosinophils in the stroma of inflammatory polyps. The patient was discharged with topical corticosteroid therapy for three months. His symptoms disappeared completely and intranasal endoscopy revealed healthy mucosa in month four of postoperative follow-up.

MYCOLOGICAL STUDY

Clinical material obtained during surgical intervention was submitted for microbiologic and histopathologic examinations. Microscopic examination of the clinical material prepared by 10% potassium hydroxide revealed irregular septate hyphae (Figure 3). A part of the specimen was inoculated on Sabouraud's dextrose agar plates supplemented with chloramphenicol (50 mg/L). The plates incubated at 25°C for 7 days yielded a mould with a velvety to woolly texture. The surface of the colony was initially white to grayish brown and then became olive green to black with a raised grayish periphery as it matured. The reverse was also darkly

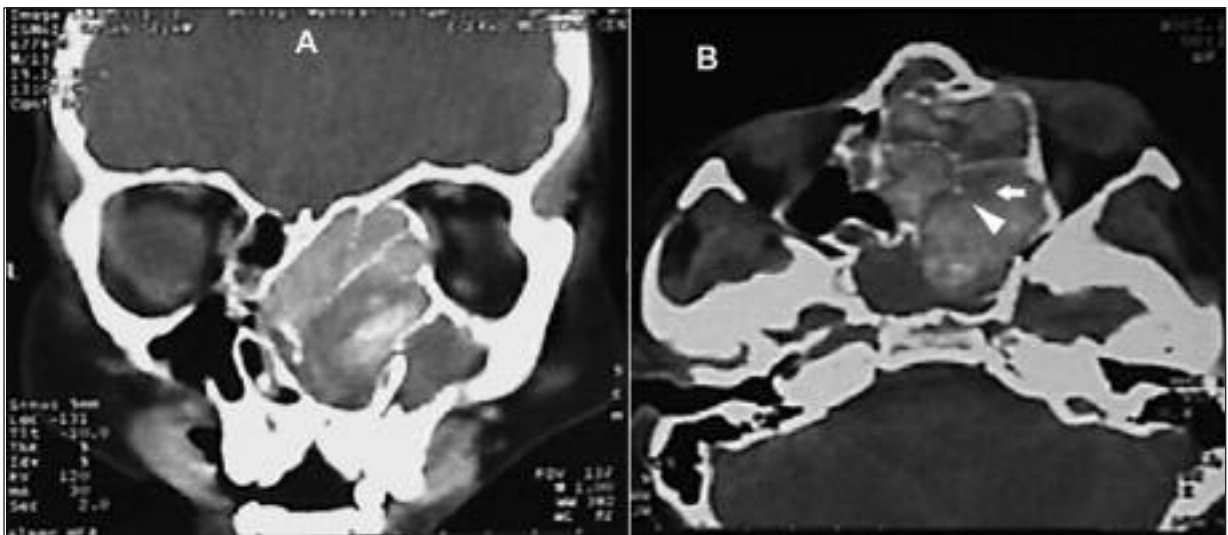


FIGURE 1: (A) Coronal CT shows complete erosion of bony septates of the anterior and posterior ethmoid cells. (B) Axial CT of the paranasal sinuses shows point erosion of anterior bony wall of the right sphenoid sinus.

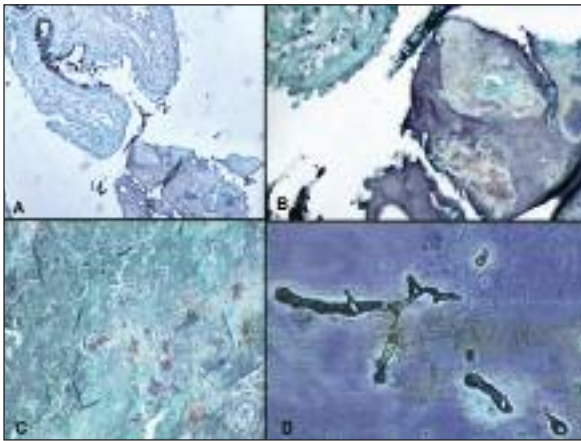


FIGURE 2 (A-D): Irregular septate fungal hyphae in mucoid substance next to sinus tissue fragment in different magnifications (Grocott's Methenamine Silver stain, x5, x20, x10 and x40 magnifications, respectively).

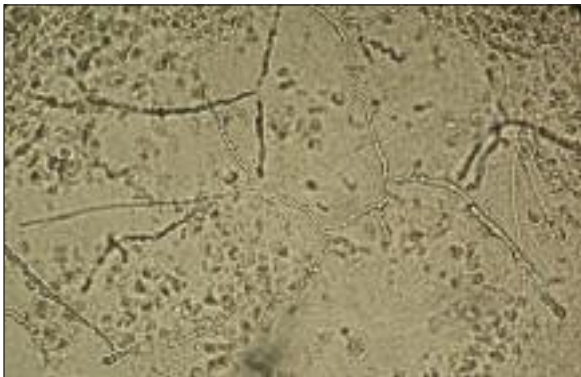


FIGURE 3: Potassium hydroxide preparation of the surgical specimen showing irregularly septate hyphae (Magnification x40).

pigmented and olive to black in color. Microscopic examination of the growth by lactophenol cotton blue staining showed septate and brown hyphae and brown, erect, branched and septate conidiophores. Some conidiophores had zigzag appearance in the apical part, with flat, dark brown scars on the edges due to bending of the conidiophores at the points where each conidium originated from. The conidia were fusoid to cylindrical in shape, light to dark brown in color, and had consistently 3 transvers distosepta (Figure 4).² Due to the aforementioned characteristics, the fungus was identified as a *Bipolaris* species. Further identification of the strain at species level could not be performed

since the isolate lost viability during maintenance culture.

DISCUSSION

The exact etiopathogenesis of AFS is not yet clearly clarified. Although there is some contradictory findings, hypersensitivity seems to play a major role in the development of AFS. Fungi, entrapped in the mucus of the nasal passages and in the sinuses result in eosinophilic accumulation and degranulation which destroys fungi but also damage normal mucosa and cause chronic inflammation. The disease occurs mostly among adolescents and young immunocompetent atopic adults. The presented case in this study was an immunocompetent 13-year-old boy.

AFS has typically a slow, nonaggressive course and does not invade the tissue. Bone necrosis and erosion of the sinus walls occur as a result of pressure or due to the effect of inflammatory mediators. Adjacent structures may then become involved in the disease process and the clinical and radiographic features of these cases can mimic a neoplastic process.³ In our case, the disease resulted in erosion of the right ethmoid, maxillary and sphenoid sinus walls which simulated a tumoral mass.

Buzina W et al, and many other authors suggested that the incidence of AFS seemed to be influenced by geographic factors and warm humid

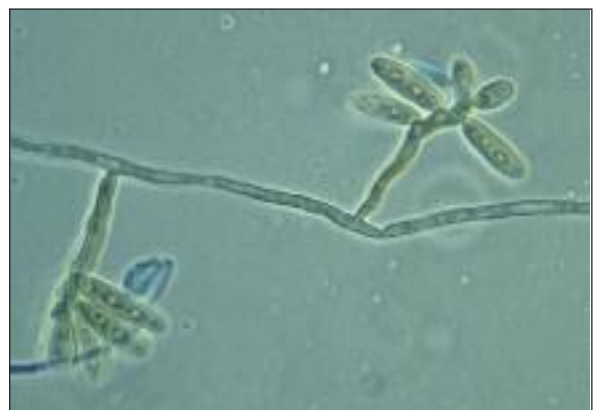

FIGURE 4: Note the septate and brown hyphae; brown, erect, branched and septate conidiophores of *Bipolaris* species. Some conidiophores appeared zigzagged in the apical part. The conidia were fusoid to cylindrical in shape, light to dark brown in color, and had consistently 3 transvers distosepta (Lactophenol cottonblue preparation from the culture. Magnification x100).

climates appeared to facilitate fungal proliferation.⁴ Our patient was also from a region with hot climate, Northern part of Iraq. *Bipolaris* species are the most common fungi cultured among AFS patients and is found in nature, in plant debris and soil.

Major diagnostic criteria for AFS proposed by Bent and Kuhn include:

- 1) nasal polyposis;
- 2) allergic mucus;
- 3) CT findings consistent with chronic rhinosinusitis;
- 4) positive fungal histology or culture; and
- 5) type I hypersensitivity (atopy) diagnosis based on history, positive skin test or serology.⁵

Allergic mucus is yellow-green, white-tan, grey, brown or black, with a consistency of peanut butter. Histology shows eosinophils and eosinophil degradation products known as Charcot-Leyden crystals. Lack of tissue (mucosal/bony) invasion and granulomatous reaction distinguishes this condition from the invasive variety of fungal sinusitis. Scattered fungi may be distinguished on hematoxylin eosin stain but are better visualized with special stains like Gomori's methenamine or Fontana-Masson. Fungal cultures may or may not be positive. Based upon these criteria, our patient had four major criteria (nasal polyposis, character-

istic CT findings, eosinophilic mucus without fungal invasion into sinus tissue, and positive fungal culture).

The management of AFS requires surgical debridement of fungal debris and restoration of sinus aeration. However, surgery alone is not enough for the treatment of patients with AFS. Oral corticosteroids have been recognized as an effective treatment of AFS. Optimal dose and duration of steroid therapy are still unclear. As the pathogenesis of AFS is suggested to be immunologic and not infectious, antimycotic therapy is controversial. It is only indicated when a histological evidence of tissue invasion by fungi is present.³ In our case, right total sphenoidectomy and nasal polyectomy was performed by endoscopic surgery. After surgical extirpation of mud-like, sticky material filling the ethmoid and sphenoid sinuses, the patient was put on topical corticosteroid treatment. After four months the patient had fully recovered.

In conclusion, due to significant overlaps between the clinical, radiological, and immunological features of AFS, invasive fungal disease, ethmoidal polyposis, and paranasal sinus tumors, a definitive preoperative differentiation of these entities is needed because it influences the choice of surgical procedure and the perioperative adjunctive medical treatments.

REFERENCES

1. Cody DT 2nd, Neel HB 3rd, Ferreiro JA, Roberts GD. Allergic fungal sinusitis: the Mayo Clinic experience. *Laryngoscope* 1994;104(9):1074-9.
2. Sutton DA, Fothergill AW, Rinaldi MG. *Bipolaris spicifera*. Guide to Clinically Significant Fungi. 1st ed. Baltimore, Maryland: Williams and Wilkins; 1998. p.82-3.
3. Kinsella JB, Rassekh CH, Bradfield JL, Chaljub G, McNees SW, Gourley WK, et al. Allergic fungal sinusitis with cranial base erosion. *Head Neck* 1996;18(3):211-7.
4. Buzina W, Braun H, Schimpl K, Stammberger H. *Bipolaris spicifera* causes fungus balls of the sinuses and triggers polypoid chronic rhinosinusitis in an immunocompetent patient. *J Clin Microbiol* 2003;41(10):4885-7.
5. Bent JP 3rd, Kuhn FA. Diagnosis of allergic fungal sinusitis. *Otolaryngol Head Neck Surg* 1994;111(5):580-8.