

# Fabrication of Implant Retained Metal-Ceramic-Composite Hybrid Dentures: Case Report

## İmplant Destekli Sabit Metal-Seramik-Kompozit Hibrid Protez Yapımı

Orhun EKREN,<sup>a</sup>  
M. Emre BENLİDAYI<sup>b</sup>

Departments of  
<sup>a</sup>Prosthodontics,  
<sup>b</sup>Oral and Maxillofacial Surgery,  
Çukurova University Faculty of Dentistry,  
Adana

Geliş Tarihi/Received: 02.12.2015  
Kabul Tarihi/Accepted: 12.02.2016

Yazışma Adresi/Correspondence:  
Orhun EKREN  
Çukurova University Faculty of Dentistry,  
Department of Prosthodontics, Adana,  
TÜRKİYE/TURKEY  
oekren@cu.edu.tr

**ABSTRACT** Rehabilitation of edentulous patients with excessively resorbed alveolar ridges with implant retained fixed partial dentures is clinically a challenging situation. Vertical and horizontal bone resorption creates malaligned jaw relations which mandates vertical and horizontal block bone grafting for proper soft tissue support and occlusion. Grafting implant site have some disadvantages in term of patient discomfort, treatment time, treatment cost and above all high risk of graft failure. The following case report presents an alternative method for the treatment of excessively resorbed maxilla with implant retained metalceramic composite dentures without any bone grafting procedure.

**Key Words:** Dental implantation; alveolar ridge augmentation

**ÖZET** İleri derecede alveolar rezorpsiyona uğramış dişsiz hastaların implant üstü sabit protezler ile rehabilitasyonu klinik olarak sıkıntılıdır. Vertikal ve horizontal kemik rezorpsiyonu uygun olmayan çene ilişkilerine neden olur. Kabul edilebilir yumuşak doku desteği ve okluzyon için kemik ögumentasyonları kaçınılmazdır. Kemik ögumentasyonlarının tedavi zamanının uzaması, postoperatif hasta konforunun azalması, tedavi giderlerinin artması ve hepsinden önemlisi greft başarısızlığı gibi bazı dezavantajları vardır. Bu olgu sunumunda ileri derecede alveolar kemik rezorpsiyonu gösteren bir hastanın herhangi bir greftleme işlemine ihtiyaç duyulmadan implant destekli sabit metal seramik kompozit hibrid protezler ile tedavisi sunulmuştur.

**Anahtar Kelimeler:** Diş implantasyonu; alveolar bombe ögumentasyonu

**Türkiye Klinikleri J Dental Sci Cases 2016;2(1):16-21**

**R**ehabilitation of edentulous patients with implant retained fixed partial dentures (IRFPD) who have used conventional full dentures for many years could be very challenging for the clinicians. It might not possible to regain lip and buccal support as well as proper occlusal relationship with conventional IRFPD in most of the cases due to excessive alveolar ridge resorption. Thus, vertical and horizontal onlay bone augmentations become inevitable. In order to eliminate bone grafting, alternative prosthetic options like implant retained hybrid dentures (IRHD) may be preferred.<sup>1</sup>

IRHD are a type of fixed dentures screwed on several dental implants and replace not only the missing teeth but also the lost soft tissues. There are mainly two kind of IRHD in terms of materials used: An acrylic resin

doi: 10.5336/dentalcase.2015-48836

Copyright © 2016 by Türkiye Klinikleri

and denture teeth superstructure supported by metal alloy (Co-Cr, Ni-Cr, Ti alloy) substructure screwed on dental implants or metal alloy substructure supporting dental porcelain. Both treatment options have some disadvantages. IRHD with acrylic has limited clinical lifetime and needs more maintenance than IRHD with dental porcelain superstructure.<sup>2</sup> On the other hand IRHD with dental porcelain superstructure has questionable passive fit due to multiple firings during manufacturing process of denture.<sup>3</sup>

In this clinical report, an alternative way to construct IRHD with metal substructure supporting cemented porcelain fused to metal (PFM) superstructures for eliminating aforementioned disadvantages were described. The patient presented was rehabilitated in Çukurova University, Faculty of Dentistry Prosthodontics clinic and followed up for 2 years.

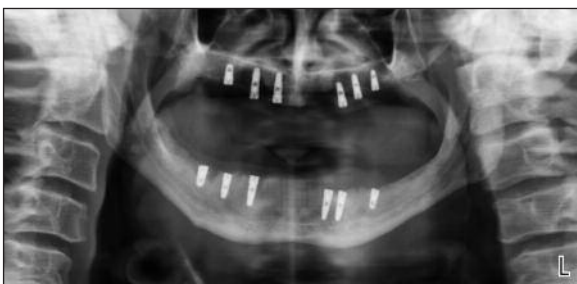## CASE REPORT

A 70 years old male suffering from loose dentures applied to prosthodontics clinic of Çukurova University Faculty of Dentistry. The patient had been using a conventional complete denture for many years and demanding implant retained fixed dentures. Clinical evaluation and cone beam computed tomography (CBCT) examination revealed severe alveolar bone resorption almost up to the basal bone in the maxilla and in the mandible. The patient had no systemic diseases and was a non-smoker who strictly refused bone grafting prior to dental implant surgery to avoid further extended treatment period. After receiving the informed consent form, based on the patient's demands and

requirement, consideration of remaining bone, soft tissue support and occlusion, IRHD for maxilla and mandible was planned on study models. Dental implants (Nucleoss, Şanlılar Tıbbi Cihazlar, İzmir, Türkiye) 6 in the maxilla and 6 in the mandible were placed submerged and waited for 4 months of osseointegration period (Figure 1). Following the second stage surgery and healing of soft tissue, patient was ready for impression procedures. Abutment level implant impressions using an additional type silicone (Panasil, Kettenbach GmbH, Ca, USA) were taken using open tray technique after splinting impression posts with an acrylic resin (Pattern Resin LS, GC America Inc. USA).

A wax rim was prepared on upper and lower master cast for try-in appointment in a manner similar to the construction of conventional full dentures for adjusting vertical dimension of occlusion, lip and buccal support, smile line and centric relation. After mounting the models to the articulator, the artificial denture teeth were aligned and tried in the mouth for esthetic appearance and occlusion (Figure 2a-d).

Silicone indexes were prepared as the upper and lower rims were in place. The burn out plastics were screwed on implant analogues and splinted with castable acrylic. With the help of the silicone index the upper rim was duplicated with modeling wax while splinted burn-out plastics were in place. The wax model was reduced with the help of a parallellometer. Guiding grooves were prepared for cut-back. The wax teeth were carved in order to be shaped as prepared teeth. The reduced wax model was sprued, invested and cast with a Co-Cr base metal alloy (Figure 3a-d). During the metal substructure try-in appointment vertical dimension of occlusion, centric relation records were verified (Figure 4). Face-bow (UTS 3D, Ivoclar- Vivadent, Liechtenstein) and lateral condylary pathway inclination were recorded during the same appointment. Metal-Ceramic restorations were fabricated on prepared teeth shaped metal substructure with each two crowns splinted together (Figure 5). Small notch between each splinted veneers were carved for housing the tip of the crown remover



**FIGURE 1:** Implants placed in maxilla and mandible.

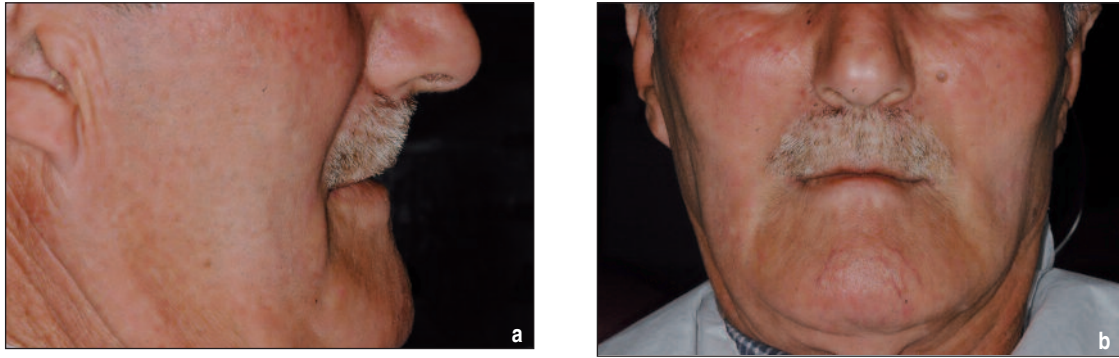


FIGURE 2a,b: Patient's profile and frontal view at baseline.

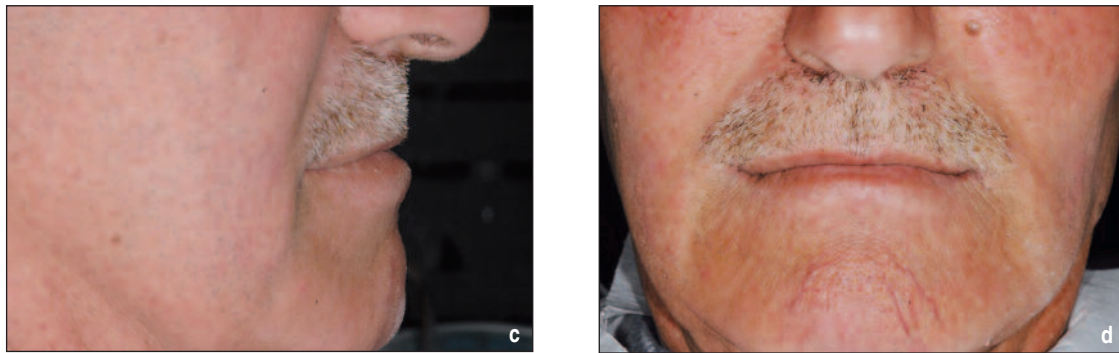

FIGURE 2c,d: Improved lip and cheek support and optimal occlusal vertical dimensions (OVD) from profile and frontal view.

for easy removal of metal-ceramic crown in case if needed (Figure 6). Occlusion was adjusted to mutually protected occlusion. The buccal of the metal substructure was covered with a pink composite resin (Gradia, Gc, Alsip, IL, USA) to mimic soft tissue (Figure 7).

During esthetic try-in appointment, vertical dimension of occlusion and centric relation were verified, minor occlusal adjustments were performed, lip and buccal soft tissue support were controlled. After glazing, metal-ceramic crowns were cemented (Figure 8). The screw access holes and notches were closed with a composite (Essentia, Gc, Alsip, IL, USA) and polished. The patient was informed about the maintenance of the dentures and hygiene procedures and called for follow up every 3 months for first year and then annually.

## DISCUSSION

The patients demanding fixed dentures with severely resorbed alveolar ridges need vertical and

horizontal onlay bone augmentations for proper aesthetics and occlusion. However bone augmentations cannot be performed on some cases due to various reasons like systemic condition, patient reluctance for extended treatment period, economic reasons. Moreover, bone augmentation procedures have higher risk of complications during implant treatment especially in cases of vertical bone height deficiencies.<sup>4,5</sup>

Screw retained implant supported hybrid dentures are very helpful for rehabilitation of patient with severely resorbed alveolar ridges. It eliminates augmentation procedures and decreases treatment period. The missing soft tissue and bone appearance can be replaced by hybrid dentures. Proper occlusion, lip and buccal support can be achieved in addition to the high aesthetic outcome. The patient in the current clinical report did not have any systemic disease. However, he strictly refused bone augmentation procedures for economic concerns and extended treatment period.

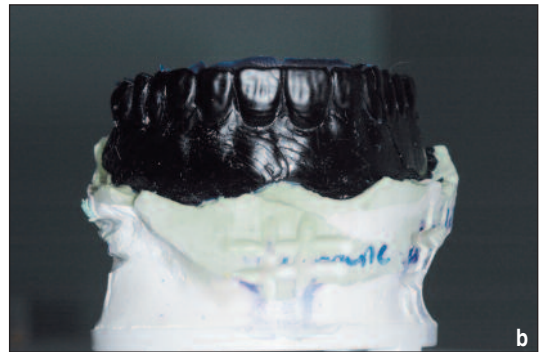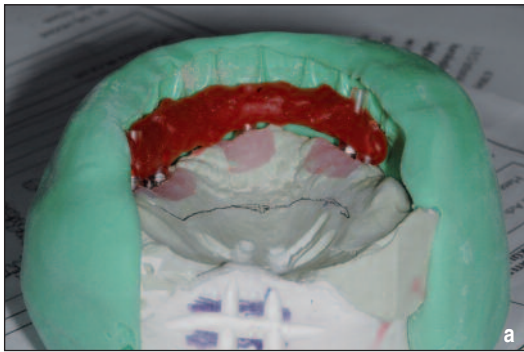


FIGURE 3a,b: Duplication of upper rim with modeling wax.



FIGURE 3c,d: Reduction of wax model and spruing.

The soft tissue support, proper occlusion and aesthetics could be achieved in cases of extensive resorption with implant retained removable dentures. Despite economical disadvantages and difficulties in encountering hygiene, hybrid fixed dentures are superior compared to the implant retained removable dentures in term of chewing efficacy and comfort.<sup>6</sup> In the current report the patient had been using removable dentures for many years and demanded fixed dentures.

Connection precision of superstructure to the implants is mandatory for the long term clinical success of the treatment.<sup>7</sup> This precise connection is called “passive fit”. Passive fit is defined as a level of fit which will not produce or cause any static load and strains within the prosthesis, implant and surrounding bone.<sup>7</sup> Ill-fitting superstructures create stress concentrations in the prosthesis framework and components. This stress concentration increases the risk of stress development around implants and surrounding bone which may negatively affect implant and denture survival.<sup>7</sup> To achieve passive fit between screw-retained prostheses and

implants could be very difficult. Some recommendations are high-lighted in the literature for having passively fitting dentures such as using a custom tray with an additional type of silicone impression material especially in cases of angulated implants, taking abutment level impressions, splinting impression copings with a rigid material and making impression with a direct open tray technique.<sup>8</sup> Therefore in the current clinical report the impressions were taken on abutment level, using a custom tray and an additional type silicone. Impression copings were rigidly splinted and impressions were taken with a direct open tray technique.

Several methods have been described to evaluate the clinical passive fit clinically. Besides more sophisticated techniques like 3D Quantifying System, using “Sheffield test” with combination of direct vision and tactile sensation with the help of an explorer is the most commonly used technique in determining passive fit. In performing Sheffield test, the most distal screw is tightened and then the discrepancies are observed on the other abutments and framework.<sup>9</sup> The Sheffield test was conducted



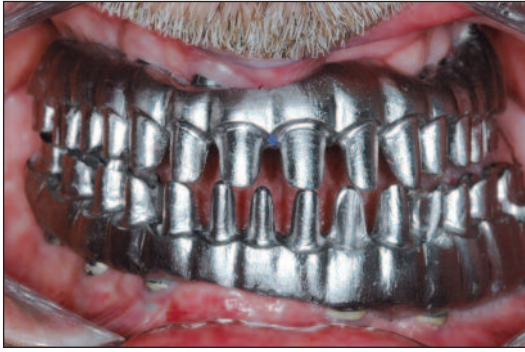

FIGURE 4: Intra-oral metal substructure try-in.

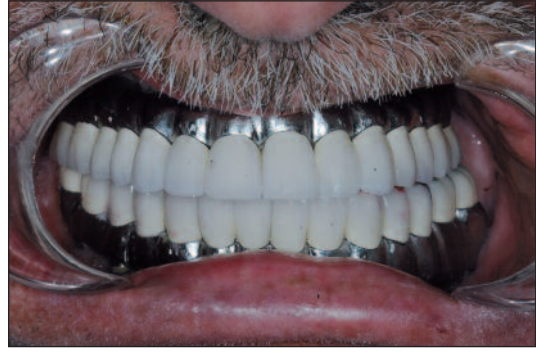

FIGURE 5: Fabrication of metal-ceramic restoration over metal substructure.

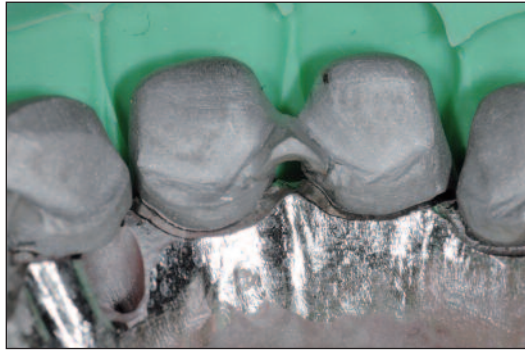


FIGURE 6: Small notches for housing of the tip of crown remover.

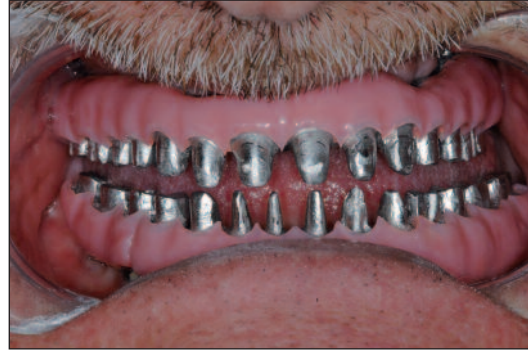

FIGURE 7: Pink composite resin application for mimicking soft tissues.

in the current study with a brand new explorer used for controlling the misfit between the abutments and the superstructure.

Achieving passive fit in metal try-in appointment does not guaranty the passive fit of the final restoration when conventional dental porcelain hybrid denture is preferred. Repeated firing of substructure for dental porcelain build-up and glazing procedures may deteriorate the passive fit.<sup>10</sup> Thus, fabricating an IRHD in multiple fragments to preserve passive fit might be more favorable. Although there exist reports explaining the benefits of IRHD; they fail to emphasize this important issue. In most of the clinical reports, pink porcelain has been used to mimic the soft tissue which has high risk of deteriorating the passive fit due to additional porcelain firing cycle. In the current report soft tissue was mimicked by using a light polymerized pink composite resin. After metal try-in, the framework was not subjected to any firing process.

The use of IRHD with multiple fragments and composite for mimicking soft tissue may be a good treatment of choice for cases with severe alveolar bone resorption. The presented technique offers a promising and predictable clinical outcome. However, long term follow-up with higher number of patients is needed for making further statements.

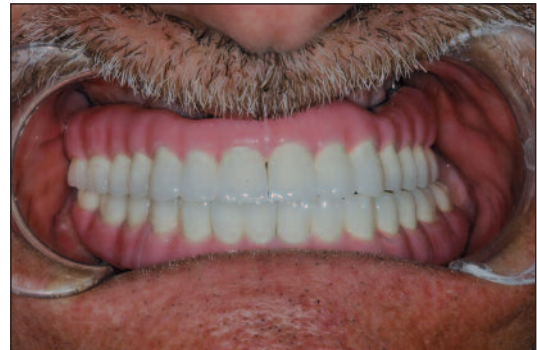

FIGURE 8: Final restoration in situ.

## REFERENCES

1. Montero J, Macedo de Paula C, Albaladejo A. The "Toronto prosthesis", an appealing method for restoring patients candidates for hybrid overdentures: a case report. *J Clin Exp Dent* 2012;4(5):309-12.
2. Lopez VJ. Laboratory considerations. In: Lopez VJ, Keogh TP, Keogh III TP, eds. *Immediate Loading in Implant Dentistry, Surgical, Prosthetic, Occlusal and Laboratory Aspect*. 1st ed. Barcelona: Quintessence; 2005. p.213-49.
3. Parel SM. The single-piece milled titanium implant bridge. *Dent Today* 2003;22(2):96-9.
4. Esposito M, Grusovin MG, Felice P, Karatzopoulos G, Worthington HV, Coulthard P. The efficacy of horizontal and vertical bone augmentation procedures for dental implants- a Cochrane systematic review. *Eur J Oral Implantol* 2009;2(3):167-84.
5. Aloy-Prósper A, Peñarrocha-Oltra D, Peñarrocha-Diago M, Peñarrocha-Diago M. The outcome of intraoral onlay block bone grafts on alveolar ridge augmentations: a systematic review. *Med Oral Patol Oral Cir Bucal* 2015;20(2):251-8.
6. Misch CE. Mandibular full-arch implant fixed prosthetic options. *Dental Implant Prosthetics*. 1st ed. St. Louis Missouri; Elseviere Mosby; 2005. p.252-64.
7. Kan JY, Rungcharassaeng K, Bohsali K, Goodacre CJ, Lang BR. Clinical methods for evaluating implant framework fit. *J Prosthet Dent* 1999;81(1):7-13.
8. Buzayan MM, Yunus NB. Passive fit in screw retained multi unit implant prosthesis understanding and achieving: a review of the literature. *J Indian Prosthodont Soc* 2014;14(1):16-23.
9. Shafie H, Eisenmann E, Rübelling G. Spark Erosion. In: Shafie HR, ed. *Clinical and Laboratory Manual of Implant Overdentures*. 1st ed. Berlin; Blackwell Publishing Company; 2007. p.85-108.
10. Wee AG, Aquilino SA, Schenaider RL. Strategies to achieve fit in implant prosthodontics: a review of the literature. *Int J Prosthodont* 1999;12(2):167-78.