

Clinical and Pathological Aspects of Anhidrosis (A Case Report)

KLİNİK VE PATOLOJİK YÖNLERİYLE ANHİDROZ (OLGU SUNUMU)

Bülent Oğuz GENÇ*, Mustafa Cihat AVUNDUK**, Emine GENÇ*, Arzu ATÇI*, İnci MEVLİTOĞLU***

* Dept. of Neurology, Medical School of Selçuk University,

** Dept. of Pathology, Medical School of Selçuk University,

***Dept. of Dermatology, Medical School of Selçuk University, KONYA

Summary

A 28-year-old man was reported because of lack of sweating. This complaint had been present since his childhood. His medical history otherwise was not remarkable. No similar complaint was reported by the other family members or relatives. His physical, neurological and pathological findings are discussed in view of the literature knowledge.

Key Words: Anhidrosis, Ectodermal dysplasia, Sweat gland dysplasia

T Klin J Dermatol 2000, 10:192-194

Özet

28 yaşındaki erkek hasta çocukluğundan beri terleyememe yakınması ile başvurdu. Belirgin başka patolojik bulgusu olmayan hastanın aile öyküsünde de bir özellik bulunmaktaydı. Hastanın fizik muayene, nörolojik ve patolojik bulguları literatür bilgisi eşliğinde tartışıldı.

Anahtar Kelimeler: Anhidroz, Ektodermal displazi, Ter bezi displazisi

T Klin Dermatoloji 2000, 10:192-194

Anhidrosis is defined as an abnormal perspiration from the surface of the skin upon appropriate stimulation that usually induces sweat under the same conditions (1). The differential diagnoses of both hypohidrosis and anhidrosis are extensive. Both entities are usually associated with dermatological or neurological lesions. Disturbances in the sweating mechanism may be due to congenital or acquired lesions of the skin or nerves (1,2). The majority of the cases are in the category of an acquired disease which usually appears in one individual whereas the congenital forms are usually familial as a manifestation of ectodermal dysplasia (1,3,4). In this report, a case diagnosed as generalized anhidrosis that occurred due to total absence of sweat glands without any other characteristics of

ectodermal dysplasia or familial history was presented.

Case Report

A 28-year-old man referred because of lack of sweating. He reported that this symptom had been present since his childhood. He also complained of a generalized malaise especially when ambient temperature was high. His medical history otherwise was not remarkable. No similar complaint was reported by the other family members or relatives. The physical and neurological examinations of the patient did not reveal any pathological finding except that his skin appeared dry. The facial appearance, teeth, nails, palmar ridges and hair of the patient were normal. Since the patient was admitted to the neurology clinic of our hospital, he was firstly examined for the neurological causes of anhidrosis. His hematological and biochemical profile, hormonal levels and thyroid function tests were also within the normal ranges. Blood pressures from

Geliş Tarihi: 27.02.1999

Yazışma Adresi: Dr.Mustafa Cihat AVUNDUK
Selçuk Üniversitesi Tıp Fakültesi
Patoloji AD, 42080, KONYA

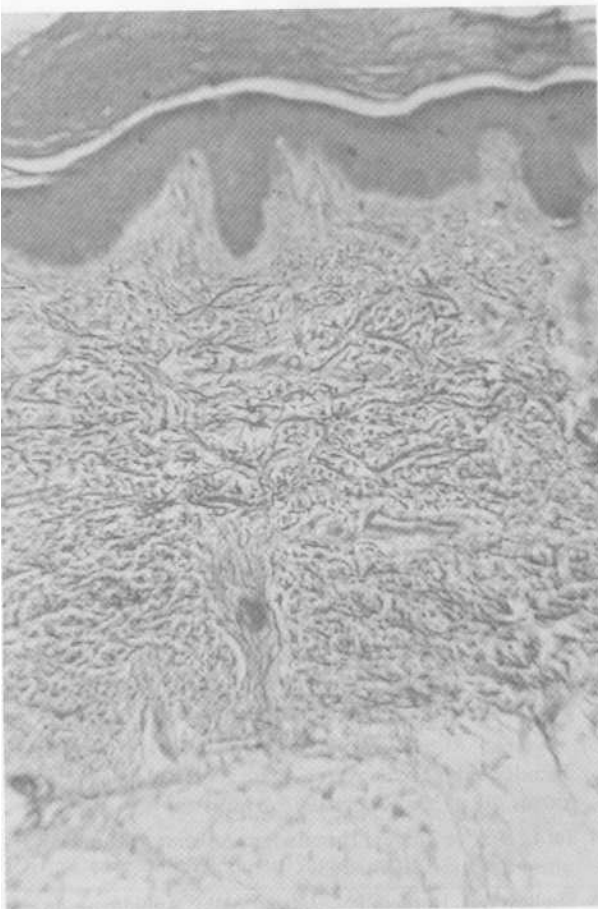


Figure 1. There is no sweat gland seen in the dermis (Masson' Trichroma; x20).

both arms were recorded to be normal and he had no orthostatic hypotension. Electromyography, evoked potentials and R-R interval variations showed no abnormality but his skin sympathetic response (SSR) could not be elicited. Cold pressor test confirmed the integrity of sympathetic reflex arc. In sitting position, immersing the hands in ice water for 60 seconds raised the systolic pressure by 20 mmHg and diastolic pressure by 10 mmHg. A starch iodine test and skin biopsy were also performed. Starch iodine test revealed minimal hidrosis in a very restricted area of axillary regions only. The skin biopsy from palmar region revealed absence of sweat glands in the deep dermis (Figure 1).

Discussion

Anhidrosis was reviewed extensively by Shelley et al. and more than 100 variants have been

recognized. Shelley classified anhidrosis into four main groups: induced by a defect in the nervous system, due to sweat glands and/or sweat duct deficiency (also known as simple anhidrosis), caused by a defect in the intermediate site, and idiopathic anhidrosis (5). Most cases of anhidrosis are acquired. However when familial anhidrosis is encountered, it is usually a manifestation of ectodermal dysplasia (3).

Generalized sudomotor failure may occur in the peripheral autonomic neuropathies and in system degenerations such as the Shy Drager syndrome and idiopathic orthostatic hypotension. Destructive lesions that interrupt sympathetic pathways in the brain or spinal cord also cause widespread anhidrosis. In all of these conditions, symptoms of thermoregulatory failure are overshadowed by more disabling autonomic symptoms such as orthostatic hypotension and disturbances of bowel or bladder dysfunction, by disabling somatic motor and sensory failure or by symptoms caused by interruption of important pathways in the brain or spinal cord. A relatively poor defined variant of thermoregulatory sudomotor failure without other evidence of notable dysautonomia or somatic involvement was reported by Low et al. for which they suggested the term "chronic idiopathic anhidrosis"(6). Another example to the rare neurological causes of anhidrosis is the unique case of familial generalized anhidrosis reported by Dann et al. The authors suggested a postganglionic defect that might be genetic (7).

Ectodermal dysplasias are a heterogenous group of hereditary disorders characterized by abnormal skin and skin appendages. The various conditions differ in the mode of inheritance and in the extent of involvement of teeth, hair, nails and sweat glands as well as the presence of other systemic manifestations (3). The classic triad of this group of disorders consists of hypotrichosis, anodontia and anhidrosis (8). Endodermal defects were also reported to occur in ectodermal dysplasia syndromes. Occasionally neurologic abnormalities such as sensorineural hearing loss may accompany ectodermal dysplasia. Sweat glands have found to be absent in many skin biopsies but some workers have demonstrated sweat glands in the deeper layers of the

cutis. The glands thus may be totally absent or may be decreased in number (9).

Total absence of sweat glands is the obvious explanation for the complete anhidrosis in our patient. The absence of SSR in the presence of intact sympathetic reflex arc as shown by the cold pressor test and a negative orthostatic reaction also confirmed a disorder of sweat glands themselves. A negative SSR response by surface electrodes in our patient was not surprising because this test requires an intact sudomotor activity (10). Murakami et al. recorded skin sympathetic nerve activity microneurographically in a patient with acquired idiopathic generalized anhidrosis (AIGA) with degenerated eccrine glands and they showed that sudomotor sympathetic outflow did not decrease or even increased in AIGA (11).

Familial generalized anhidrosis which is not related to ectodermal dysplasia and does not present with all of its manifestations is extremely rare (1). However Mahloudji and Livingston gave account of an Iranian family with severe simple anhidrosis without any other characteristics of ectodermal dysplasia (12). Ingber cited that Passage and Fries had also observed a similar case (1). The case reported by Mahloudji and Livingston is similar to our case except that it is familial. These two reports were the only examples of anhidrosis due to sweat gland aplasia without any other defects of ectodermal origin in the literature we have reviewed. Frydman et al. described a brother and sister with familial simple anhidrosis but they had also abnormal palmar dermal ridges (3).

Ingber classified ectodermal dysplasias of anhidrotic type into three groups: a) ectodermal dysplasia with generalized anhidrosis and hair, sweat gland and dental anomalies with or without additional congenital defects, b) ectodermal dysplasia with generalized anhidrosis without any other defect and without morphological sweat gland anomalies, c) ectodermal dysplasia with generalized anhidrosis without any other defect and with morphological and functional abnormalities of sweat

glands (1). Our case might be inserted into the latter category but whether or not this patient could be considered in the category of ectodermal dysplasia is controversial. Although clinical spectrum of ectodermal dysplasias is very large, total absence of sweat glands is one but not only pathology seen in anhidrotic ectodermal dysplasia. Reed et al. suggested that these conditions do not possibly represent the same disease and therefore simple anhidrosis should be included in the list of differential diagnoses of anhidrotic ectodermal dysplasia (9). We suggest that sweat gland dysplasia or aplasia is likely to be a better term for such cases without any other defect of ectodermal origin.

REFERENCES

1. Ingber A. Familial generalized anhidrosis. *Isr J Med Sci* 1990; 26:457-8.
2. Nemlioğlu F. Deri Hastalıkları. İstanbul: İstanbul Üniversitesi Cerrahpaşa Tıp Fakültesi Yayınları 1979; 452.
3. Frydman M, Cohen HA, Kauschansky A, Matoth Y. Familial simple hypohydrosis with abnormal palmar dermal ridges. *Am J Med Genet* 1988; 31:591-6.
4. Tat L. Deri ve Zührevi Hastalıkları. Ankara: Ankara Üniversitesi Basımevi, 1974: 263.
5. Shelley WB, Horvath PN, Pillsbury DM. Anhidrosis: an etiologic interpretation. *Medicine* 1950; 29: 195-224.
6. Low PA, Fealey RD, Sheps SG, Su WPD, Trautmann JC, Kuntz NL. Chronic idiopathic anhidrosis. *Ann Neurol* 1985; 18:344-8.
7. Dann EJ, Epstein Y, Sohar E. Familial generalized anhidrosis. *Isr J Med Sci* 1990; 26:451-3.
8. Arnold HL, Odom RB, James WD eds. *Andrews' diseases of the skin, clinical dermatology*. Philadelphia: WB Saunders Company, 1990: 675.
9. Reed WB, Lopez DA, Landing B. Clinical spectrum of ectodermal dysplasia. *Arch Derm* 1970; 102:134-43.
10. Shahani BT, Halperin JJ, Boulu P, Cohen J. Sympathetic skin response. A method of assessing unmyelinated axon dysfunction in peripheral neuropathies. *J Neurol Neurosurg Psychiatry* 1984; 47:536-42.
11. Murakami K, Sobue G, Iwase S, Mitsuma T, Mano T. Skin sympathetic nerve activity in acquired idiopathic generalized anhidrosis. *Neurology* 1993; 43:1137-40.
12. Mahloudji M, Livingston KE. Familial and congenital simple anhidrosis. *Amer J Dis Child* 1967; 113:477-9.