

Mediastinal Hamartoma Presented As A Thymic Malignancy: Case Report

Timik Malignite İzlenimi Veren Mediastinal Hamartom

Kuthan KAVAKLI,^a
Ali Fuat ÇİÇEK,^b
Okan KARATAŞ,^a
Alper GÖZÜBÜYÜK^a

Departments of
^aThoracic Surgery,
^bPathology,
Gulhane Military Medical Academy,
Ankara

Geliş Tarihi/Received: 01.02.2016
Kabul Tarihi/Accepted: 02.05.2016

Yazışma Adresi/Correspondence:
Kuthan KAVAKLI
Gulhane Military Medical Academy,
Department of Thoracic Surgery, Ankara,
TURKİYE/TURKEY
kavaklikuthan@gmail.com

ABSTRACT Mediastinum is an extremely rare location for hamartoma and according to our knowledge a few case reported in the literature until now. When the imaging modalities demonstrate a mass located in the antero-superior mediastinum compatible with thymoma, the surgical resection remains the mainstay for the treatment. Although, many approaches exist for the resection of these tumors, robotic assisted thoracoscopic surgery is gaining popularity with different surgical components include right versus left side approach, number of incisions and extent of resection. Its technical superiority with excellent exposure and high quality instruments and minimally invasive manner make this approach first option. Herein, we presented a patient who underwent robotic-assisted mediastinal mass resection. After resection, interestingly the final pathology was reported as chondroid hamartoma and it was infiltrated with prostatic carcinoma.

Key Words: Robotics; mediastinum; hamartoma

ÖZET Mediasten, hamartom için oldukça nadir görülen bir lokalizasyondur ve bildiğimiz kadarıyla şimdiye dek literatürde birkaç vaka bildirilmiştir. Üst anterior mediastende yerleşmiş timoma ile uyumlu bir kitle görüntüleme yöntemleri ile ortaya konduğunda, temel tedavi kitlenin cerrahi olarak rezeksiyonudur. Bu tümörlerin rezeksiyonu için birçok yöntem olmasına rağmen, robot yardımlı torakoskopik cerrahi sağ veya sol taraflı yaklaşımıyla, insizyon sayısı ve rezeksiyon genişliğiyle popülerlik kazanmaktadır. Minimal invaziv oluşu, mükemmel görüş alanı ve yüksek kaliteye sahip enstrümanları ile kazandığı teknik üstünlük bu yaklaşımı ilk seçenek yapmaktadır. Biz de robot yardımıyla mediastinal kitle rezeksiyonu uyguladığımız bir hastayı sunduk. Rezeksiyon sonrası patolojisi ilginç bir şekilde prostat karsinomu ile infiltre bir kondroid hamartoma olarak raporlandı.

Anahtar Kelimeler: Robotik; mediasten; hamartom

Türkiye Klinikleri Arch Lung 2016;17(2):27-30

Pulmonary hamartoma is the most common benign tumour of the lung. It is usually presented as an asymptomatic solitary pulmonary nodule and discovered incidentally. Mediastinum is an extremely rare location for hamartoma which was presented only once in the literature up-till now.¹ Its clinical importance is to discriminate this lesion from malignant nodule located in the lung or mediastinum. Although hamartomas have some benign characteristics such as popcorn pattern calcification and definitive pattern of fat and cartilage content, this is not rule and when these features do not exist, these lesions can mimic malignant lesions.

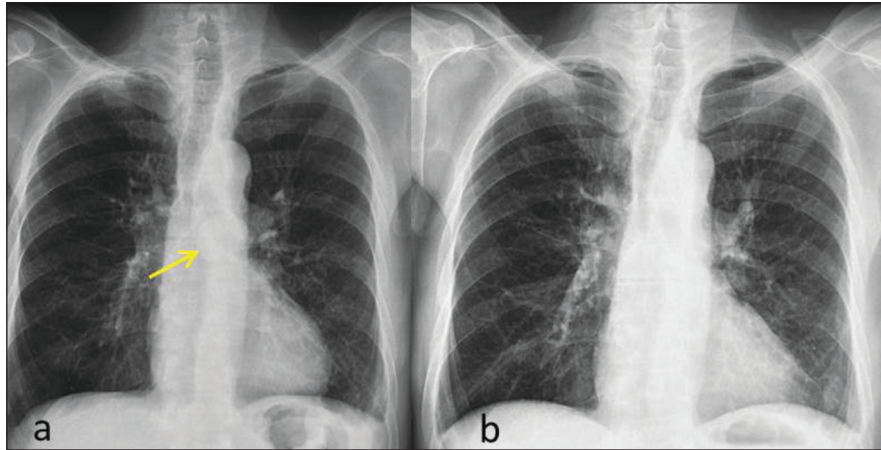


FIGURE 1: Preoperative chest X-ray revealed a mass superpoze to the mediastinum (white arrow) (a). Normal chest X-ray findings on 11th postoperative day (b).

Surgical resection is the mainstay of the treatment for mediastinal mass such as thymoma. En bloc resection includes lesion and surrounding mediastinal fat is the recommended for the surgical treatment.² The question is in which approach is the optimal way for complete resection. Thoracoscopic thymectomy has less impairment and faster recovery of pulmonary function when compared with sternotomy without any compromise on surgical outcomes for thymectomies.³ Currently, robotic assisted thoracoscopic surgery (RATS) for mediastinal lesions is a technically sound and safe procedure with a very low complication rate and short hospitalization when compared with sternotomy approach. Herein, we presented a patient who underwent robotic assisted mediastinal hamartoma resection.

CASE REPORT

A 76-year-old man presented with an asymptomatic mediastinal mass which was discovered at his prostatic carcinoma surveillance. His chest X-ray revealed a mass that was located in the mediastinum (Figure 1a). The chest CT scan demonstrated a 5 cm diameter round-mass in the antero-superior mediastinum that probably had pericardial invasion and/or great vascular invasion which gave an impression a mass originating from the thymic tissue at first sight (Figure 2). The transthoracic fine needle aspiration biopsy was per-

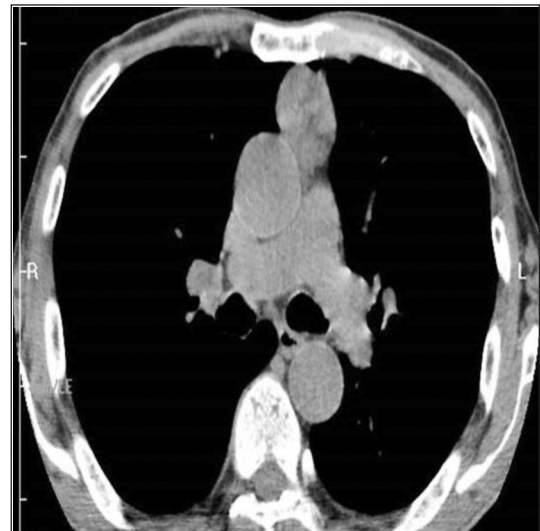


FIGURE 2: Chest CT of the patient revealed a mass located in the antero-superior mediastinum and it was compatible with thymic lesion.

formed and it has confirmed a suspicious disease for thymic malignancy. Due to the long-term survival expectation for patient with his prostatic carcinoma, robotic-assisted mediastinal mass resection was recommended and performed. The patient was placed in supine position with 30° left side-up. We approached from the left side with three arms and an additional assistant port. The 12-mm trocar for binocular camera was placed in the fifth intercostal space at the anterior of the left anterior axillary line. A thoracoscopic 10-mm 30° camera was introduced to evaluate the operation field and deter-

mine the location of the other two 8-mm trocars. The superior trocar was introduced in the third intercostal space at the anterior of the middle axillary line and the lower trocar was introduced in the fifth intercostal space at the midclavicular line. Thus, all three trocars were placed in the submammary fold. An additional 12-mm trocar was placed between the camera trocar and lower trocar as an assistant port. We preferred to access from the left side because he had a history of pleurisy from the right that can be resulted in severe pleural adhesions and it is safer to control the phrenic nerve from the left side. When dissecting the lesion from pericardium and great vessels, no invasion was determined opposite to our opinion. But it had severe adhesions to the right lung. And also the right lung had severe adhesions to the chest wall. This situation can be thought as a preventive effect for right-sided pneumothorax. And robotic-assisted mediastinal mass resection was completed uneventfully. The final histopathological examination revealed chondroid hamartoma and it was interestingly infiltrated with prostatic carcinoma which was stained with PSA

by immunohistochemically. By considering his previous medical history for prostatic adenocarcinoma, the diagnosis of prostatic adenocarcinoma metastasis was performed (Figure 3). The patient was discharged without any complications on 5th postoperative day. The chest X-ray was normal on 11th postoperative day (Figure 1b).

DISCUSSION

Pulmonary hamartoma is the most common benign tumor of the lung and it is also one of the etiologies of solitary pulmonary nodule. When it is located in the lung parenchyma, classic 'popcorn' calcification pattern, fat and cartilage pattern and PET/CT findings can be distinctive. However, diagnosis of mediastinal hamartoma is challenging because it is really uncommon presentation of hamartoma. The diagnosis before any intervention is difficult because the imaging modalities are not diagnostic and they are usually designed for common tumors of the anterior mediastinum. In our case, the imaging methods were not true guide and the diagnosis was only obtained after resection of the tumor.

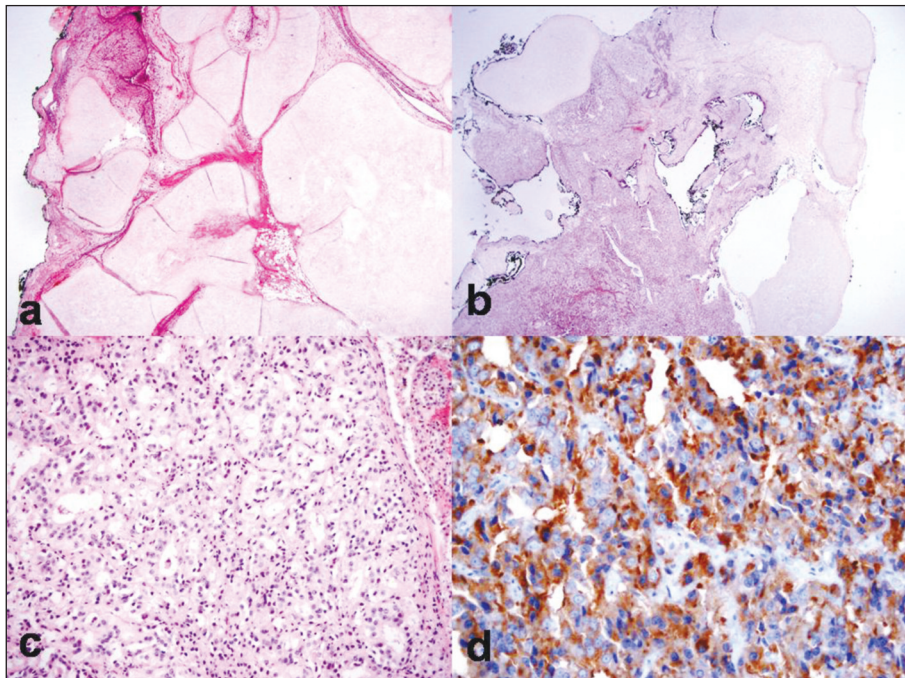


FIGURE 3: Hamartomatous lesion composed of large chondroid islands and adipose tissue between the chondroid islands, slit-like structures lining with respiratory epithelium can be seen (20x H&E) (a). In another area adjacent to the chondroid islands, an epithelial malignant tumor is seen. (20x H&E) (b). The tumor composed of glandular structures arranged with back to back pattern. The neoplastic cells have prominent nucleoli (200x H&E) (c). Immunohistochemically PSA positivity in the cytoplasm of the tumor cells (200x PSA immunostaining) (d).

In our case, we preferred to approach from the left side because he had pleurisy from the right side twenty years ago. And also the advantages of left side approach include preservation of left phrenic nerve, easier and safer dissection of thymic tissue which has a long left horn and complete dissection of the aorto-pulmonary window.⁴ An anatomical study demonstrated that left-sided approach for thymus had better visualization except the aorto-caval groove⁵. Right-sided approach has a larger room in the thymic area according to left side. However, this can be useful when performing thymectomy via Video-Assisted Thoracoscopic Surgery (VATS). The instruments of the VATS are more rigid and they have very limited movement. In robotic surgery, carbon dioxide (CO₂) insufflation and the ex-

tended movement of the robotic arms make the thymectomy safer and easier from the left side. Nevertheless, Cerfolio and colleagues suggested that early in a surgeon's learning curve, a right-sided approach may be easier and safer.⁶ The safety of right-sided approach is due to easier control and exposure of the venous structures.

The metastasis to the mediastinal located hamartoma is also very interesting findings for our patient. It was presented in Figure 1 clearly.

As a conclusion, we presented a case of mediastinal hamartoma that was resected with RATS. It is difficult to consider a mediastinal mass as a mediastinal hamartoma for pre-diagnosis therefore the diagnosis can only be achieved with resection of the lesion.

REFERENCES

1. Saad R Jr, de Próspero JD, Gonçalves R, Rivaben JH, Squeff FA. [A rare mediastinum tumor: hamartoma]. *Rev Col Bras Cir* 2013; 40(2):169-71.
2. Ruffini E, Venuta F. Management of thymic tumors: a European perspective. *J Thorac Dis* 2014;6(Suppl 2):S228-37.
3. Rückert JC, Walter M, Müller JM. Pulmonary function after thoracoscopic thymectomy versus median sternotomy for myasthenia gravis. *Ann Thorac Surg* 2000;70(5):1656-61.
4. Ismail M, Swierzy M, Rückert RI, Rückert JC. Robotic thymectomy for myasthenia gravis. *Thorac Surg Clin* 2014;24(2):189-95.
5. Rückert JC, Czyzewski D, Pest S, Müller JM. Radicality of thoracoscopic thymectomy--an anatomical study. *Eur J Cardiothorac Surg* 2000;18(6):735-6.
6. Cerfolio RJ, Bryant AS, Minnich DJ. Starting a robotic program in general thoracic surgery: why, how, and lessons learned. *Ann Thorac Surg* 2011;91(6):1729-36.