

Application of fascia lata heterograft (En experimental work on rats)*

Tayfun AKÖZ¹, Bülent ERDOĞAN¹, Metin GÖRGÜ¹, Nur CABAR², Ferhan DAĞ¹

Depts. of Plastic and Reconstructive Surgery¹ and Pathology²,
Ankara Numune Hospital, Ankara, TURKEY

In Plastic and Reconstructive surgery, the tissue to be used for various purposes is obtained primarily from the patient himself. Homografts of various tissues are used like bone, skin, tendon, fascia, nerve, and cartilage to decrease the time of surgery and donor site morbidity.

In our clinic, commercially available fascia homografts were applied on rats by placement of the graft in the head and in the abdominal wall before use in humans. In early and late periods, the rats had been examined both macroscopically and microscopically. It is concluded that this homograft has the required properties of a fascia graft and can be used like a frame in places which have tissue deficiency. [Turk J Med Res 1994; 12(3) 103-107]

Key Words: Heterograft, Fascia lata, Rats

One of the most interesting subjects of the medical history is the use of tissues and organs from different species, when necessary. With the development of transplantation immunology, the tissue and organ transplantations became routine procedures.

For immediate use, some tissue grafts are processed to become commercially available. The materials taken from cadavers are treated to lower their antigenity and presented for usage in sterilized condition.

In this experiment on rats, we investigated the applicability of fascia lata heterograft that was prepared in this manner.

MATERIALS AND METHODS

Fascia lata heterograft was implanted in the vertex of head and abdominal wall of rats. Experiment was made in the Laboratory of Surgical Research at Hacettepe University, by using Sprague-Dawley rats each 6 weeks old and, weighing 250 grams.

Received: Jan. 11, 1994

Accepted: April 26, 1994

Correspondence: Tayfun AKOZ

Mediha Eldem Sok. No: 60/2
Kizilay/Ankara, TURKEY

Presented at the 14th National Congress of Plastic Surgery in Ankara.

Turk J Med Res 1994; 12(3)

An experimental model was designed to investigate the tissue reaction against fascia lata heterograft and to observe if a layer of mainly connective tissue had been formed in the area where it is placed. If absorption or rejection had occurred we would accept that the material was not useful for our purpose and it had more antigenity than expected. If the fascia maintained its structure unchanged after transplantation, we could use it as supporting tissue graft on the place that there was tissue deficiency.

Animals

Group 1: There were 30 rats in this experimental group. Fascia lata heterograft was implanted in the heads and in the anterior abdominal walls of the rats (Fig 1). Each 3 group that had 10 rats, were followed 3 days, 3 weeks, 3 months postoperatively.

Group 2: Control group. There were 10 rats in this group. Similarly, top of the heads and anterior abdominal walls were opened. Flaps were dissected from these areas and were sutured back. No biologic material was implanted, we just examined that connective tissue occurred or not in normal wound healing.

Evaluation

Macroscopical and microscopical examinations were made on the 3rd day, 3rd week and on the 3rd month. Fascia lata graft was found through the previous incision. First macroscopic examination was made. Subsequently cutis, subcutis, fascia lata

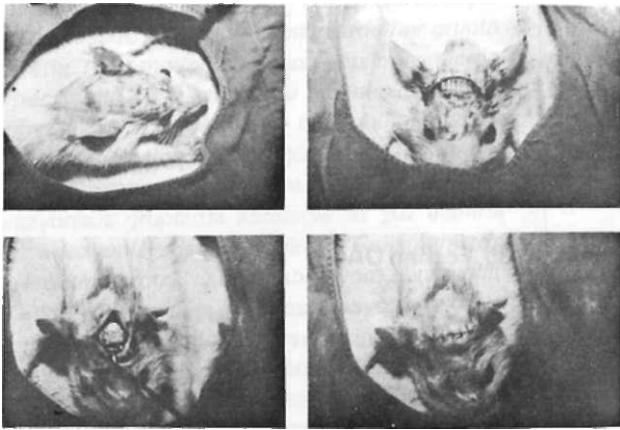


Figure 1. Implantation of fascia lata heterograft on the top of the head.

heterograft and cranium was excised together as one layer, for histopathological examination.

On the abdominal wall, an excision including "Panniculus Carnosus", was performed.

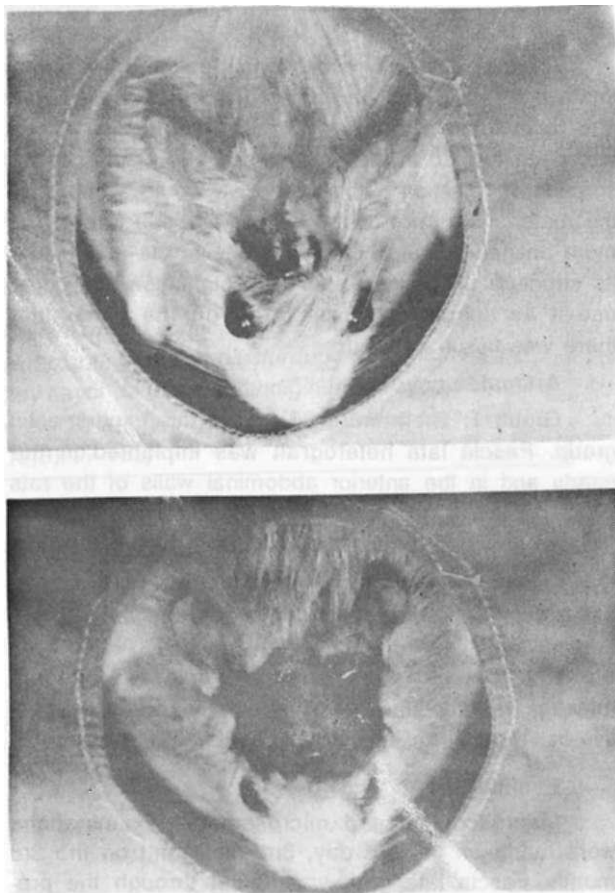


Figure 2. Macroscopic appearance on the third o.-. nostoperatively.

3rd day: 8 living rats were examined. Macroscopically there was not any sign of infection on both operation sites. Incisions healed without a problem. Externally, swelling that was caused by the graft was observable. By entry through previous incision, yellowish-white colored fascia lata was discovered. A fibrin like layer was observed both on and around the graft (Fig 2).

Microscopically, infiltration of polymorphonuclear leukocytes and hyperemia were noticed around fibrohyalinized connective tissue (fascia) (Fig 3).

3rd week: 8 living rats were examined. In the macroscopical evaluation, it was found that previous incisions were without problem and the fascia graft underlying gave a white reflection, externally. When soft tissue opened it was observed that the neighboring soft tissue had moved on the fascia and, particularly the graft was covered by a ivory colored fibrin layer (Fig 4).

In the microscopical investigation, it was observed that, surrounding the fibrohyalinized connective tissue, there was an inflammatory granulation tissue, having inflammatory cells with high quantity of plasma cells, multinuclear macrophages and proliferated blood vessels and fibroblasts (Fig 5).

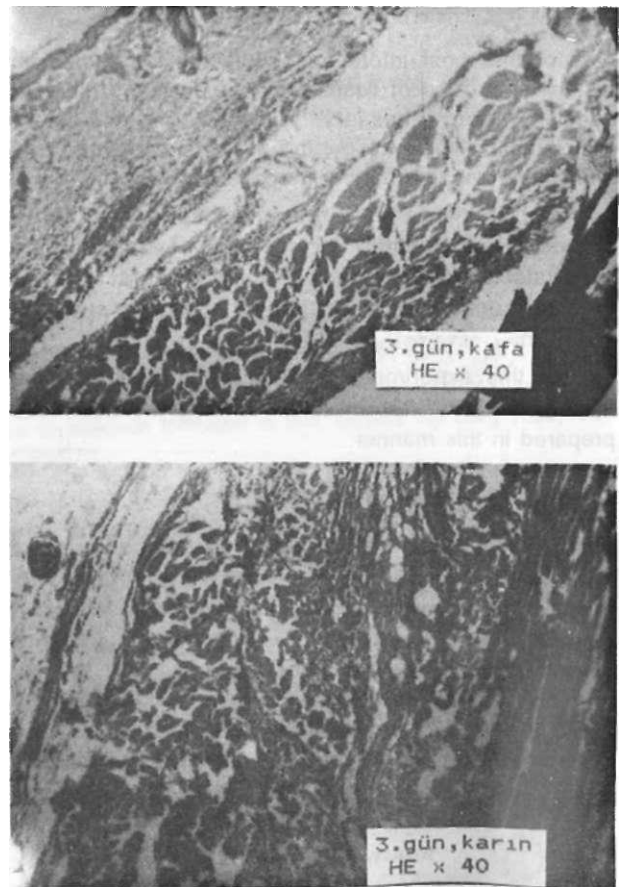


Figure 3. Microscopic appearance of the specimen from the head and abdominal wall on the third day. HEx40.

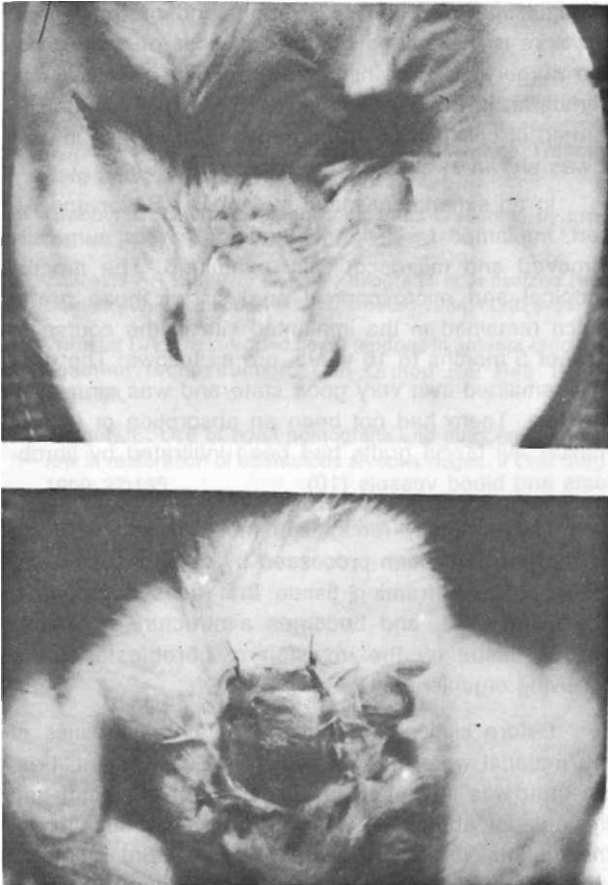


Figure 4. Macroscopic appearance on the third week, postoperatively.

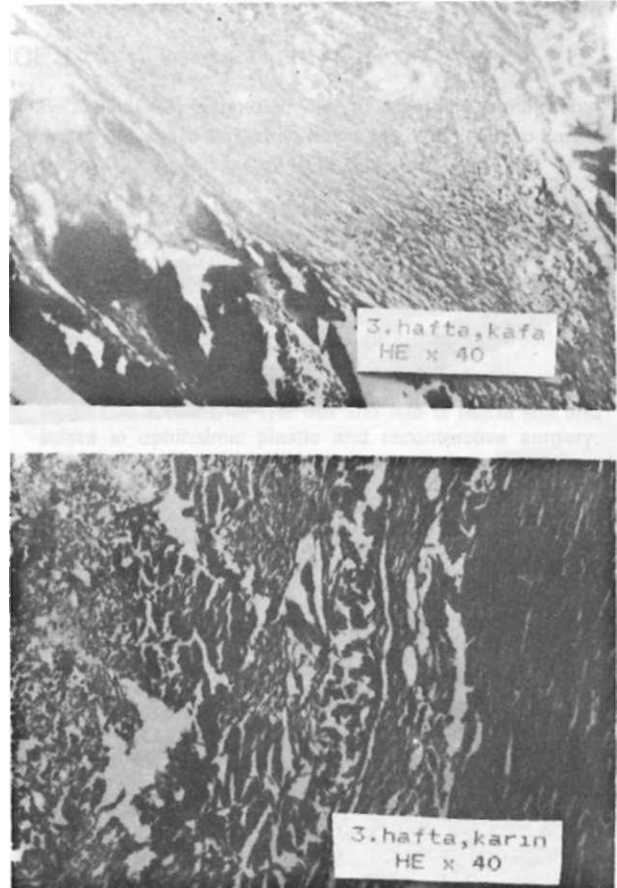


Figure 5. Microscopic appearance of the specimen from the head and abdominal wall on the third week. HEx40.

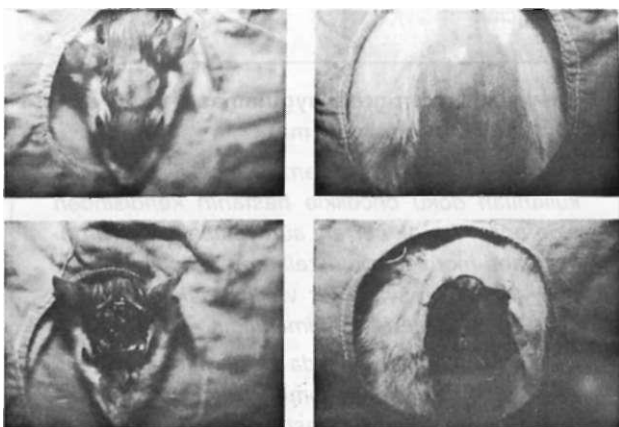


Figure 6. Macroscopic appearance from the head and abdominal wall on the third month, postoperatively.

3rd month: 5 living rats were evaluated. Macroscopically, on the head skin and anterior abdominal wall, the incision was seen as a thin scar. When the

Turk J Med Res 1994; 12 (3)

incision opened, it was observed that fascia was integrated with the surrounding soft tissues, and there was a thin and shiny layer on top of it (Fig 6).

On the other hand, microscopically, it was observed that inflammatory reaction of mostly polynuclear macrophages had been completely over and fascia was integrated with the surrounding fibrous connective tissue (Fig 7).

RESULTS

After the application of fascia graft on rats, we have concluded that this biological material remains intact, it supports the tissues where it is implanted, performs the function of a frame, forms a layer of mainly connective tissue. In the control group, no material was implanted, because we tried to find out what differences of fascia lata homograft made in wound healing from natural wound healing in this study.

Fascia lata homograft can be used in reconstructive procedures in which particularly there is a need for a supportive tissue.



Figure 7. Microscopic appearance of the specimen from the head and abdominal wall on the third month. HEx40.

DISCUSSION

Autogenic and homogeneous biological material are often used in reconstructive surgery. On this matter, the important point is the characteristics of the material. Material is needed that is complementary for the neighboring tissues in the area implanted, acceptable by the receiving site (and suitable for the proposed function). The tissue to be used could be obtained from biological resources other than the patient himself. In our day, for the purpose of avoiding donor site morbidity and decreasing the duration of surgery, various tissue homografts are used like bone, skin, tendon, fascia, nerve, and cartilage (1-6). The complications, like rejection of foreign tissue, host tissue reaction, and infectious diseases that could be caused by homografts, are overcome by various chemical and physical treatments (2,7).

Consequences of the fascia homograft utility as a biological material had been investigated. Freeze-dried fascia lata homograft had been used in orthopaedic interventions and it was reported that this graft

remains intact, its tensile strength and morphological structure is maintained (8). The success of reconstructive surgery became higher by the use of fascia lata homograft in head and neck surgery (7). This graft is formed of collagen fibers and antigenicity is quite low as it was shown in experiments on animals (9).

In an experiment made in 1981 by Beyer and Albert, implanted fascia lata homografts were surgically removed and microscopically examined. The macroscopical and microscopical analysis of these grafts which remained in the implanted site in the course of time of 5 months to 16 years, are as follows: The graft had remained in a very good state and was structurally intact. There had not been an absorption or inflammation. All fascia grafts had been infiltrated by fibroblasts and blood vessels (10).

The generally recognized fact is that the fascia graft which had been processed by certain treatments, functions as a framing tissue that does not contain any living cells, and becomes a structure of mainly fibrous tissue by the invasion of fibroblasts of the receiving organism (11).

Before clinical application, the characteristics of the material were investigated by an experiment. Fascia graft was implanted in the vertex of the head and the anterior abdominal wall and in the investigation of the material removed on post operative 3rd month, it was observed that it formed a fibrotic layer. The fact that it is neither rejected nor absorbed, gave the assurance about applicability of the graft. On account of the positive consequences of the use of fascia heterograft on rats, it was planned to use this graft in human as well in reconstructive cases where it would be beneficial.

Fasya lata heterogrefti uygulaması (Raflarda deneysel çalışma)

Plastik ve Rekonstrüktif cerrahide çeşitli amaçlarla kullanılan doku öncelikle hastanın kendisinden elde edilir. Ancak cerrahi süreyi kısaltmak ve donör saha morbiditesini azaltmak amacıyla kemik, deri, tendon, fasya, sinir ve kırıkta gibi çeşitli doku homogreftleri kullanılmaktadır.

Kliniğimizde hastalarımızda kullanmadan önce, ticari olarak hazır fasya homogreftleri, rafların kafa ve karın ön duvarına yerleştirilmiştir. Erken ve geç dönemde uygulanan alanlar alınarak makroskopik ve mikroskopik olarak incelenmiştir. Sonuçta bu homogreftin fasya greftinin ihtiyaç duyulan özelliklerine sahip olduğu belirlenmiş ve çeşitli doku defektli alanlarında çati oluşturacak şekilde kullanılabileceği anlaşılmıştır. [Türk J Med Res 1994; 12(3): 103-107]

REFERENCES

1. Kabayashi S. Reconstruction of the four major ligaments in unstable knee joint after dislocation by solvent-preserved human fascia lata transplantation. *Arch Orthop Trauma Surg* 1989; 108:246-9.
2. Grabb WC. Costal cartilage homografts preserved by irradiation. *Plast Reconstr Surg* 1961; 28:562.
3. Zalewski AA. Survival of nerve allografts in sensitized rats treated with Cyclosporin-A. *J Neurosurg* 1984; 60:828-34.
4. Webster DA. Freeze-dried flexor tendons in anterior cruciate ligament reconstruction. *Clin Orthop Rel Res* 1973; 181:238.
5. Yeager JE. Use of bone homografts and autogenous marrow in restoration of edentulous alveolar ridges. *J Oral Surg* 1969; 27:185.
6. Burwell RG. The fate of freeze-dried bone allografts. *Transplant Proc* 1976; 8:95.
7. Behbehani AA, Eichner E. Clinical experiences with dehydrated solvent-dried human fascia lata in Oto-Rhino-Laryngology. *Laryng Rhino Otol* 1983; 62:548-51.
8. Bright RW, Green WT. Freeze-dried fascia lata allografts: A review of 47 cases. *J Pediatr Orthop* 1981; 1:13.
9. Pesh HL. Solvent-preserved grafts of dura mater and fascia lata (membranous collagen graft) in animals. In: Portman M, ed. *Facial Nerve*. New York: Masson, 1985:506-11.
10. Beyer CK, Albert DM. The use and fate of fascia lata and sclera in ophthalmic plastic and reconstructive surgery. *Ophthalmology* 1981; 88:869-86.
11. Snyderman KR. Transplantation of fascia. In: Converse JM, ed. *Reconstructive Plastic Surgery*. Philadelphia: WB Saunders, 1977:262.