

# A Cylinder Aneurysm of the Inflatable Penile Prosthesis: An Unusual Case of Mechanical Dysfunction

## Şişirilebilir Penil Protezin Silindir Anevrizması: Sıradışı Bir Mekanik Disfonksiyon Olgusu

Mustafa KIRAÇ,<sup>a</sup>  
Çağrı GÜNERİ,<sup>a</sup>  
Murat DAYANÇ<sup>a</sup>

<sup>a</sup>Clinic of Urology,  
Koru Hospital, Ankara

Geliş Tarihi/Received: 22.06.2013  
Kabul Tarihi/Accepted: 31.10.2013

Yazışma Adresi/Correspondence:  
Mustafa KIRAÇ  
Koru Hospital,  
Clinic of Urology, Ankara,  
TÜRKİYE/TURKEY  
mkirac@gmail.com

**ABSTRACT** The inflatable penile prosthesis have high patient satisfaction, good mechanical reliability rates and are accepted as a third-line therapy for the treatment of erectile dysfunction for many years. The complications related with implantation of inflatable penile prosthesis are rare. These complications include; infection, mechanical function disorders (such as cylinder aneurysm, tube leakage, reservoir leakage, linkage breakage), erosion, crus perforation and penile necrosis. The most common complication of implantation of penile prosthesis is infections. The mechanical dysfunction including cylinder aneurysm is extremely rare. In this case report, we aimed to present an inflatable penile prosthesis aneurysm, in patients with a 36 years old male, 8 years after implantation which is a rare complication.

**Key Words:** Complications; erectile dysfunction; penile prosthesis

**ÖZET** Erektile disfonksiyonun düzeltilmesi için üçüncü basamak tedavide uzun zamandır kullanılan şişirilebilir penis protezleri yüksek hasta memnuniyeti ve iyi bir mekanik uyuma sahiptir. Penil protez implantasyonu ile ilişkili komplikasyonlar nadiren ortaya çıkmaktadır. Bu komplikasyonlar; enfeksiyonları, mekanik fonksiyon bozukluklarını (silindir anevrizması, tüp kaçağı, rezervuar kaçağı, bağlantı kopması), erozyonları, krus perforasyonlarını ve penis nekrozunu içerir. Penil protez implantasyonunun en yaygın görülen komplikasyonu enfeksiyonlardır. Silindir anevrizmasını içeren mekanik fonksiyon bozukluğu ise oldukça nadir görülen bir komplikasyondur. Biz bu vaka takdimi ile 36 yaşında bir erkek hastada implantasyondan 8 yıl sonra gelişen ve oldukça nadir görülen şişirilebilir bir penil protezin silindir anevrizmasını içeren komplikasyonu sunmayı amaçladık.

**Anahtar Kelimeler:** Komplikasyonlar; sertleşme bozukluğu; penis protezi

**Türkiye Klinikleri J Urology 2013;4(3):144-6**

Penile prosthesis implantation is accepted as a third-line therapy for the treatment of erectile dysfunction (ED) if treatment including intracorporeal injection and intraurethral agent fail. Currently, patient-activated penile prostheses are successfully used to treatment of ED.<sup>1</sup> The complications related with implantation of inflatable penile prosthesis are very rare. These complications include; infection, mechanical function disorders (such as cylinder aneurysm, tube leakage, reservoir leakage, linkage breakage), erosion, crus perforation and penile necrosis.<sup>2,3</sup> With this case report, we present an unusual and rare complication of inflatable penile prosthesis in 36-year-old patient.

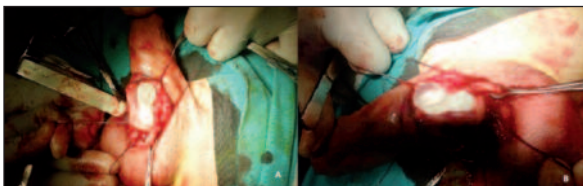
## CASE REPORT

An inflatable penile prosthesis (Ambicor, AMS, USA) was placed to a 36-year-old man who had been suffering from ED which was caused by neuropathy due to type 1 diabetes mellitus, 8 years ago. He referred to our clinic with loss of activation of prosthesis, pain and palpable swelling on penis for the last 3 months. We determined a palpable deformation and swelling on the left-lateral side of the root of the penis on the physical examination. The patient's laboratory values were found within the normal range (blood glucose:136 mg/dl, hemoglobin:14.1 g/dl, BUN: 11, creatinine 0.8) and PA pulmonary X-ray graphy was determined as normal. Then the operation was planned to replace the prosthesis. The skin was opened with peno-scrotal incision, then the corpora cavernosa were opened after the mobilizing the scrotal part of prosthesis. An aneurysmal dilatation with a diameter of 2x2 cm was seen on the central part of the left corpus cavernosus (Figure 1 A, B and 2A, B). The prosthesis was then removed. The irrigation of corpuses was done with solution containing rifampicin. After that; a new prosthesis was implanted which was 22 cm length and 11 mm thickness. The negative pressure suction drainage tube was placed into the space. The drainage tube was taken off at postoperative 2<sup>nd</sup> day. The patient was discharged at post operative 3<sup>rd</sup> day. The prosthesis was activated at post operative 6 week and the patient started to perform it. No problems were encountered on the follow-up period.

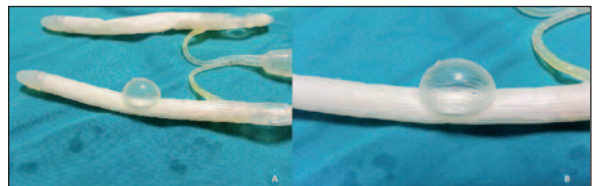
## DISCUSSION

A significantly great success was obtained on the treatment of erectile dysfunction using with 5

alpha reductase inhibitors in the last decades. If this first line treatment fails, the intra cavernosale agents can be used instead of it. When all these treatments have failed then penile prosthesis is applied for the treatment of ED. Approximately half of the patients who are suffering from ED have serious and irreversible damage and these patients are candidate for prosthesis implantation.<sup>4</sup> The implantation of penile prosthesis is an effective treatment modality on patients with ED and increases the patient satisfaction and provides sexual intercourse. We can observe that, the prostheses which are used for the treatment of ED, had improvement over time. Today, we can classify them into two main types as malleable and inflatable. Inflatables are divided 2 type as 2 segmented and 3 segmented. In our patient, 2 segmented inflatable prosthesis which was developed a cylinder aneurysm had been used (Ambicor, AMS, USA).<sup>5</sup> Even though the rate is low, the penile prosthesis implantation operation may result some complications such as; postoperative pain, infection, mechanical problems, erosion and penile necrosis.<sup>6,7</sup> Paranhos et al., obtained the postoperative pain and the infection rate as 24,5% and 7,9% respectively.<sup>8</sup> In recent studies it has been shown that the rate of infection related penile prosthesis is between 1.7 and 15%.<sup>8,9</sup> In a more recent study by Efesooy et al found no serious infection which needen surgical removal of inflatable penile prosthesis.<sup>10</sup> The most common microorganism isolated is *Staphylococcus epidermidis*. The treatment is removing of the prosthesis and using of antibiotics. Mechanical prosthesis dysfunction is seen rare and the rate is given between 1.4-13.7% in the literature.<sup>4,9,10</sup> The rupture of cylinder, mechanical breaking and fluid leakage are determined as the most frequent mechanical dys-



**FIGURE 1A, B:** The intra-operative view of the cylinder aneurysm.  
(See color figure at <http://www.turkiyeklinikleri.com/journal/uroloji-dergisi/1309-632X/>)



**FIGURE 2A, B:** Extracted aneurysmatic cylinder of the prosthesis.  
(See color figure at <http://www.turkiyeklinikleri.com/journal/uroloji-dergisi/1309-632X/>)

functions. The spontaneously swelling of the prosthesis (auto-inflation) is another mechanical problem. This problem is observed approximately 2.4-11%.<sup>5,7</sup> The cylinder aneurysm is a rare complication which is related with using of inflatable prosthesis. Kaufman et al. have been reported two cylinder aneurysm case which occurred 4 years after the implantation of AMS 700 CX mode inflatable prosthesis in 2008.<sup>11</sup> In our case the aneurysm occurred 8 years after the implantation of AMS ambicor named inflatable prosthesis. And patient's prosthesis became useless because of this aneurysm. There were needed a second operation to replace the prosthesis.

As a result; we can conclude that, except the pain and infection, the other mechanical disorders

are rarely occurred on implantation of penile prosthesis. It must be argued that if this situation is a complication or mechanical dysfunction. The cylinder aneurysm is quite a rare mechanical trouble for this procedure. It may be due to the inaccurate structural production or inaccurate micro coating procedure. The manufacturer firm is informing the patients and the surgeons about the possibility of leakage and malfunction without any mechanical details. If it is occurred once, it is necessary to replace it. The manufacturer of these prosthesis should be warned if that kind of faults observed during the follow-up. Even though it is a rare situation, it should be remembered that, it is possible to occur a cylinder aneurysm on inflatable penile prosthesis.

## REFERENCES

1. Moncada I, Martinez-Salamanca JI, Allona A, Hernandez C. Current role of penile implants for erectile dysfunction. *Curr Opin Urol* 2004;14(6):375-80.
2. Jarow JP. Risk factors for penile prosthetic infection. *J Urol* 1996;156(2 Pt 1):402-4.
3. Carson CC, Robertson CN. Late hematogenous infection of penile prostheses. *J Urol* 1988;139(1):50-2.
4. Minervini A, Ralph DJ, Pryor JP. Outcome of penile prosthesis implantation for treating erectile dysfunction: experience with 504 procedures. *BJU Int* 2006;97(1):129-33.
5. Carson CC, Mulcahy JJ, Govier FE. Efficacy, safety and patient satisfaction outcomes of the AMS 700CX inflatable penile prosthesis: results of a long-term multicenter study. AMS 700CX Study Group. *J Urol* 2000;164(2):376-80.
6. Dubocq F, Tefilli MV, Gheiler EL, Li H, Dhabuwala CB. Long-term mechanical reliability of multicomponent inflatable penile prosthesis: comparison of device survival. *Urology* 1998;52(2):277-81.
7. Wilson SK, Henry GD, Delk JR Jr, Cleves MA. The mentor Alpha 1 penile prosthesis with reservoir lock-out valve: effective prevention of auto-inflation with improved capability for ectopic reservoir placement. *J Urol* 2002; 168(4 Pt 1):1475-8.
8. Paranhos M, Andrade E, Antunes AA, Barbieri AL, Claro JA, Srougi M. Penile prosthesis implantation in an academic institution in Latin America. *Int Braz J Urol* 2010;36(5): 591-601.
9. Govier FE, Gibbons RP, Correa RJ, Pritchett TR, Kramer-Levien D. Mechanical reliability, surgical complications, and patient and partner satisfaction of the modern three-piece inflatable penile prosthesis. *Urology* 1998;52(2):282-6.
10. Efesoy O, zbay E, Tek M, Akbay E, ayan S. [Long term outcomes and couples' satisfaction with three-piece inflatable penile prosthesis surgery in the treatment of erectile dysfunction]. *Turkiye Klinikleri J Med Sci* 2010;30(6):1965-70.
11. Kaufman JM, Weldon TE. Cylinder aneurysm of parylene-coated American Medical System (AMS) 700CX penile prosthesis. *J Sex Med* 2008;5(11):2713-5.