

# Reconstruction of the Defects of the Face Resulting from Excision of Congenital Melanocytic Nevi with Bilobed Flaps After Tissue Expansion

*KONJENİTAL MELANOSİTİK NEVUS EKŞİZYONU SONUCU YÜZDE OLUŞAN DEFEKTLERİN DOKU EKSPANSİYONU SONRASI BİLOBE FLEPLERLE REKONSTRÜKSİYONU*

Uğur KOÇER\*, Hasan Mete AKSOY\*, Yiğit Özer TİFTİKÇİOĞLU\*, Harun ÇÖLOĞLU\*, Cafer ARSLAN\*

\* Plastic and Reconstructive Surgery Clinic, Ankara Training and Research Hospital, Ankara, TURKEY

## Summary

**Purpose:** To present the use of bilobed flaps on the face as an adjunct to tissue expansion.

**Setting:** The study was performed in the Plastic and Reconstructive Surgery Department of Ankara Training and Research Hospital.

**Materials and Methods:** Two patients with congenital melanocytic nevi located on the face were treated with bilobed flaps following tissue expansion. A two staged procedure consisting of placement of tissue expander in the first stage and lesion excision combined with reconstruction with bilobed flaps in the second stage was used.

**Results:** Use of the bilobed flap technique following tissue expansion prevented distortion of facial structures around the lesion and preserved facial contour and symmetry. This was especially important after excision of lesions close to the eyelids or when degree of tissue expansion was considered less than desired due to variable causes.

**Conclusion:** We conclude that combination of the bilobed flap technique with tissue expansion is a useful alternative in the surgical treatment of congenital melanocytic nevi located on the face especially under certain circumstances.

**Key Words:** Congenital melanocytic nevi, Tissue expansion, Bilobed flaps

T Klin J Med Res 2001, 19:146-151

Received: April 06, 2001

**Correspondence:** Ugur KOCER  
Plastic and Reconstructive Surgery Clinic,  
Ankara Training and Research Hospital,  
Ankara, TURKEY

## Özet

**Amaç:** Bilobe Heplerin yüzde doku ekspansiyonuna ek olarak kullanılabilirliğinin gösterilmesi.

**Yapıldığı Yer:** Çalışma Ankara Eğitim ve Araştırma Hastanesi 1. Plastik ve Rekonstrüktif Cerrahi Kliniği'nde gerçekleştirildi.

**Materyal ve Metod:** Yüzde yerleşimli konjenital nevusü olan iki hasta doku ekspansiyonunu takiben bilobe Heplerle tedavi edildi. İlk aşamada ekspander yerleştirilmesini, ikinci aşamada ise lezyonun eksizyonunu ve bilobe Heplerle rekonstrüksiyonunu içeren iki aşamalı bir prosedür uygulandı.

**Bulgular:** Doku ekspansiyonu sonrası bilobe Heplerin kullanılması, lezyonun etrafındaki yapılarda gerilim yaratmamış ve yüz konturunu ve simetrisini korumuştur. Bu özellikle göz kapağı gibi hassas bölgelere yakın lezyonların çıkarılmasında ve çeşitli sebeplerden dolayı yeterli doku ekspansiyonunun sağlanamadığı durumlarda önemlidir.

**Sonuç:** Yüzdeki konjenital melanositik nevüslerin eksizyonu sonrası onarım için doku ekspansiyonuna bilobe Hep tekniğinin eklenmesi özellikle bazı özel durumlarda iyi bir tedavi seçeneğidir.

**Anahtar Kelimeler:** Konjenital melanositik nevüs, Doku ekspansiyonu, Bilobe Hep

T Klin Araştırma 2001, 19:146-151

Today it is clearly known that even small and medium sized congenital melanocytic nevi have the potential to undergo malignant transformation and the risk increases with age (7,11). In addition, these unsightly lesions, especially those located on the

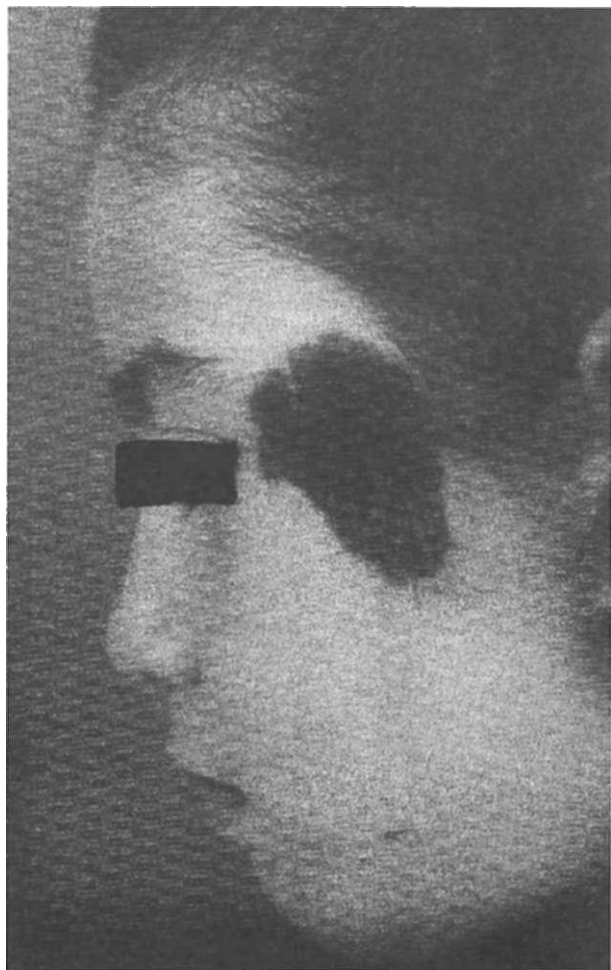
face, cause significant aesthetic disfigurement in young patients leading to serious psychological and social problems. Therefore these lesions especially larger ones should be treated early in life (1). At times it is quite difficult to treat lesions located on the face that are large enough to preclude excision and primary closure or closure with local flaps without distorting neighboring structures. The advent of tissue expanders has revolutionized surgical treatment of such lesions allowing successful removal of large areas of skin and soft tissue and appropriate closure of the defect by enough laxity of the skin provided by tissue expansion (4,5,10). Another approach to close defects created by excision of the lesion on the face is the bilobed flap technique in which another flap is used for direct closure of the secondary flap defect making use of laxity of the skin adjacent to the main flap (8). Use of the bilobed flap technique following tissue expansion may be more appropriate to prevent distortion of structures around the lesion and to preserve facial contour and symmetry especially after excision of lesions close to the eye lids or when degree of tissue expansion is considered less than desired due to variable causes.

## Case Reports

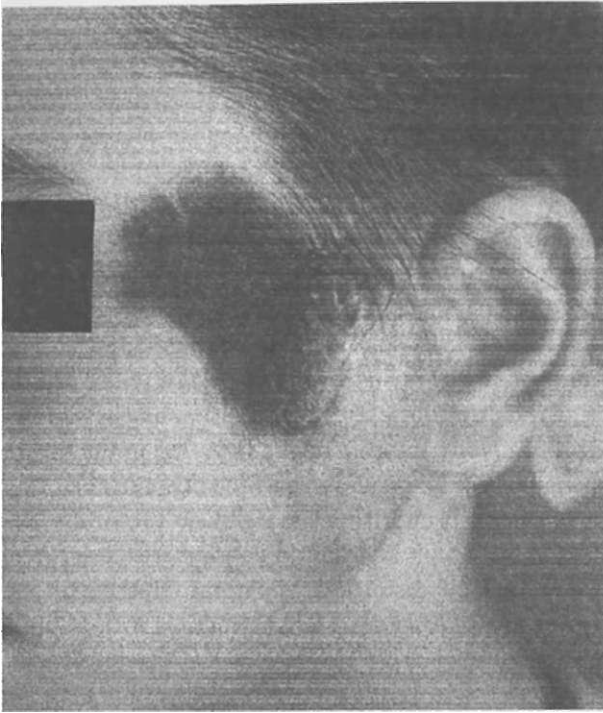
### Case 1

A 9-year-old girl presented with congenital melanocytic nevus located on the left side of the face. The lesion was situated between the eye and the ear, located mainly in the temple and preauricular region measuring 5.5x3.5 cm in size (Figure 1A). There was a limited amount of hairless skin adjacent to the lesion making primary closure or use of a local flap impossible after removal. As color and texture match is not ideally achieved with full thickness skin grafts tissue expansion was chosen as the method of surgical treatment. In the first step of surgical treatment a rectangular tissue expander (McGhan®, 50cc) was placed under the skin of the preauricular region posteroinferior to the lesion. Expander was inflated with saline weekly up to 40 cc (Figure 1B). Unfortunately patient had exposure of the expander through a skin defect located on the healed incision of the first operation due to thinning of the skin caused by pressure exerted by the edge of the expander. Considering risk of infection the second step of surgical treatment

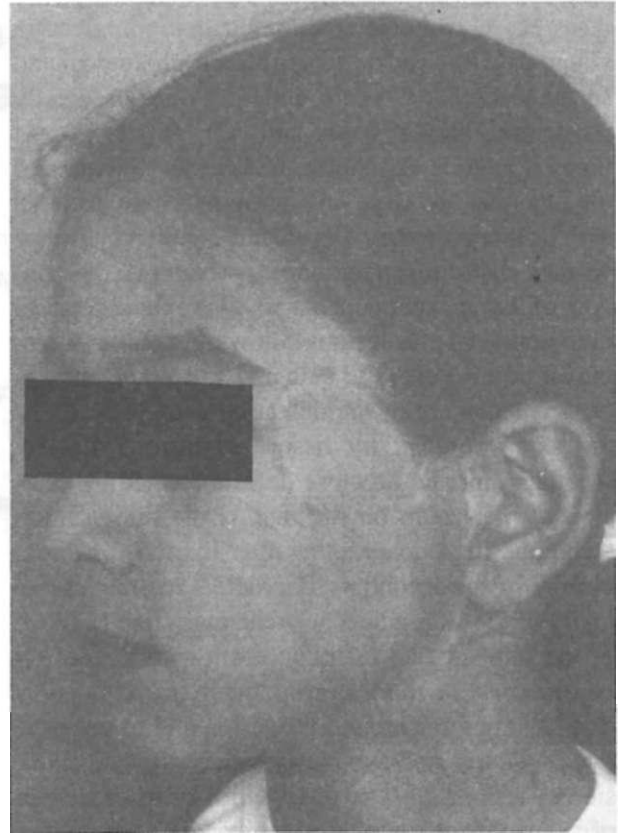
had to be performed earlier than it was planned. In addition, adequate expansion of the skin had already been obtained. Congenital melanocytic nevus was excised totally and the expander was removed. Two inferiorly based flaps with the same pivotal point were designed according to the bilobed flap technique (Figure 1C). One of the flaps comprising the bilobed flap was in the preauricular region and used to cover the defect resulting from excision of the lesion. This flap contained expanded skin. The other flap was raised from the postauricular region and was used for closure of the secondary flap defect following transfer of the first flap to the defect (Figure 1C). The donor site of the postauricular flap was closed primarily. Despite close proximity between the lesion and lateral canthus of the left eye there was no distortion of lateral canthus or the lower eyelid following reconstruction with bilobed



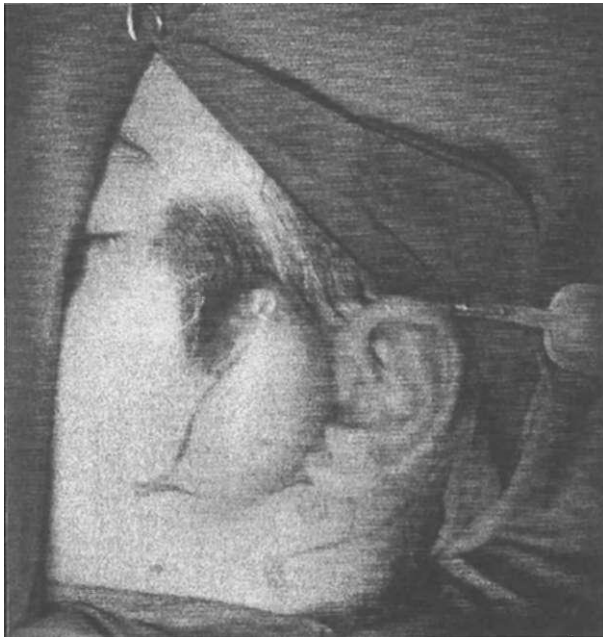
**Figure 1.** Patient 1 is a 9-year-old girl. (A) A congenital melanocytic nevus located on the face is seen before the operation.



**Figure 1.** Patient 1 is a 9-year-old girl. **(B)** Appearance of the lesion and expanded skin after the first stage of the operative treatment. Note that part of the expander is exposed through the site of the incision.



**Figure 1.** Patient 1 is a 9-year-old girl. **(D)** Appearance of the bilobed flap 8 months later. Note that the natural contour of the face is well preserved and there is no distortion of the lateral canthus.

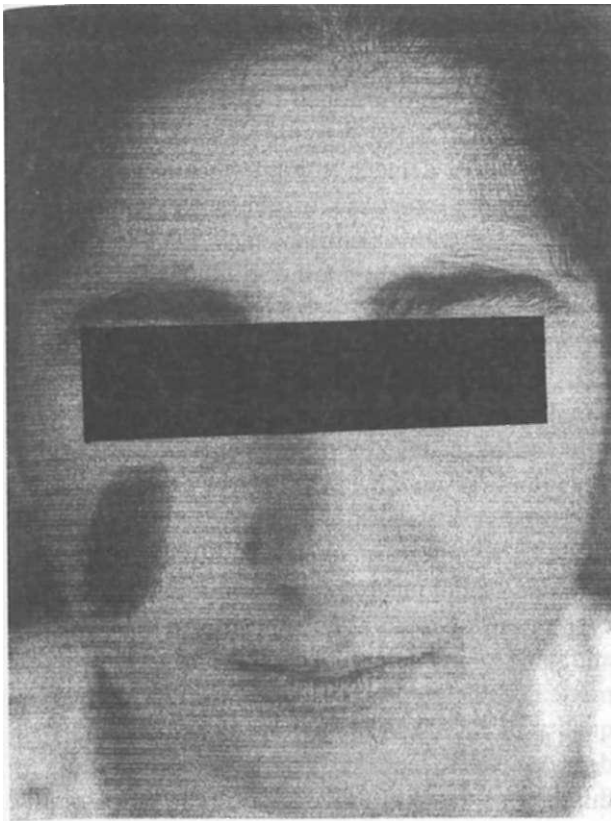

**Figure 1.** Patient 1 is a 9-year-old girl. **(C)** Intraoperative design of the bilobed flap.

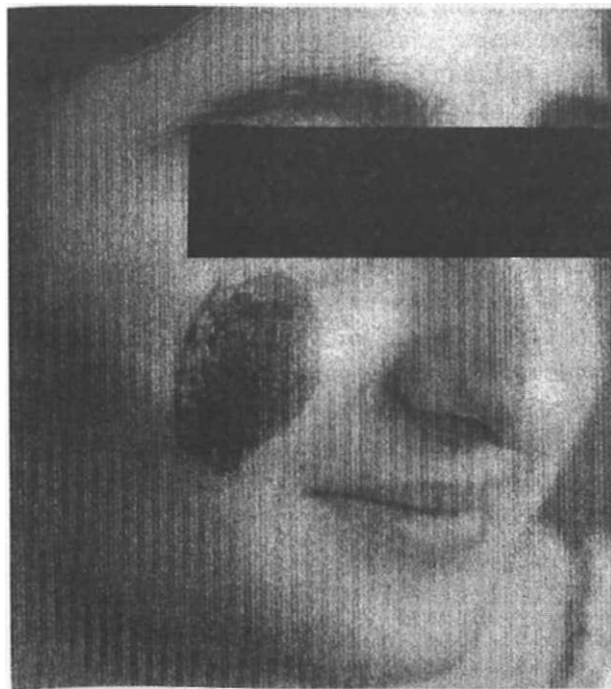flap. Postoperative period was uneventful. Facial contour and symmetry were also preserved well after reconstruction of the defect with bilobed flap eight months after the operation (Figure ID).

## Case 2

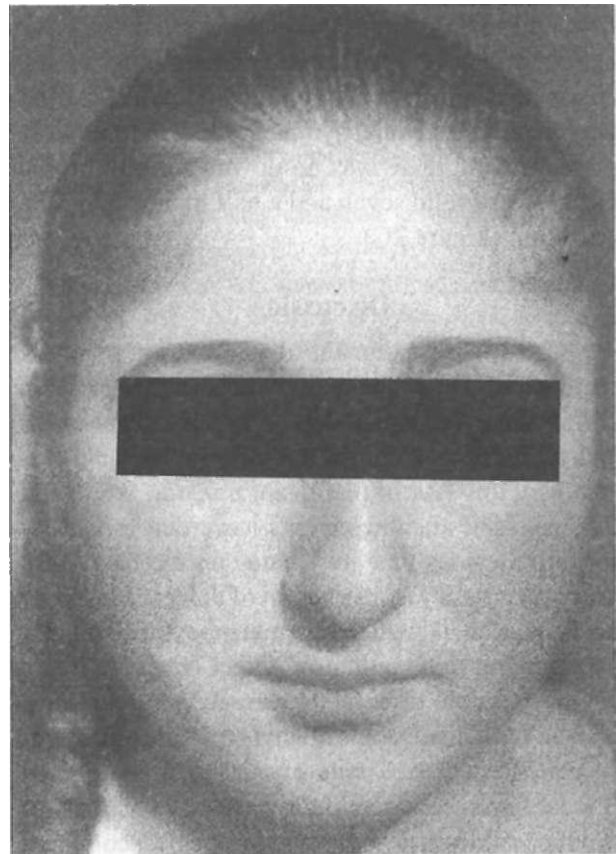
A 16-year-old girl presented with congenital melanocytic nevus measuring 4x2 cm in size and located on the malar region of the face on the right side (Figure 2A). The lesion was situated just below right lower eyelid. Because of the location of the lesion there was a limited amount of normal skin around the lesion making removal and primary closure very difficult if not impossible. Removal and reconstruction with a local flap was difficult and carried the risk of pulling lower eyelid downwards and distorting facial symmetry and contour. Because color and texture match is not ideally achieved with full thickness skin grafts tissue ex-



**Figure 2.** Patient 2 is a 16-year-old girl. (A) A congenital melanocytic nevus located on the face is seen before the operation.



**Figure 2.** Patient 2 is a 16-year-old girl. (B) Appearance of the lesion and expanded skin immediately after the first stage of the operative treatment.



**Figure 2.** Patient 2 is a 16-year-old girl. (C) Appearance of the bilobed flap 7.5 months later. Note that the natural contour of the cheek is well preserved and there is no downward pull on the lower eyelid.

pansion was chosen as the method of surgical treatment. In the first operation a cylindrical tissue expander (CUI®, 2.5 cc) was placed in the malar region posterior to the lesion. Expander was inflated with saline weekly up to 6.5cc in 2 months (Figure 2B). After 2 months the second operation was performed since no further expansion was achievable with saline injections, as the capacity of the expander had come to its maximum. The congenital melanocytic nevus was totally excised and the expander was removed in the second operation. Two inferiorly based flaps were designed according to the bilobed flap technique. The flap adjacent to the defect included expanded skin and was used for closure of the defect following excision of the lesion. The other flap was raised from the right preauricular region next to sideburn area to cover the secondary defect created by the transfer of the

first flap. The donor site of the second flap was closed primarily after some undermining to decrease tension on the flaps. Postoperative period was uneventful. Facial symmetry and contour were preserved and there was no downward pull on the right lower eyelid seven and a half months after the operation (Figure 2C).

### Discussion

Because of malignant transformation potential removal of large congenital melanocytic nevi in childhood is recommended (7,11). However small and medium sized congenital melanocytic nevi carry a very low risk of malignant transformation and this makes aesthetic concerns important especially for those lesions that are located on the face (3,6). The best way of reconstruction of defects caused by excision of facial congenital melanocytic nevi is local flaps but this method of defect coverage is not always possible or defect coverage can be accomplished with distortion of facial structures to an unacceptable degree. Tissue expansion is considered local flap reconstruction is difficult to achieve or not possible at all as it provides the best color and texture match among other alternatives (5,10). Congenital melanocytic nevi involve whole dermis and extend some distance into subcutaneous tissue. Therefore grafting defects following complete excision of congenital melanocytic nevi result in a depressed contour in addition to color and texture mismatch. So primary grafting or grafting rest of defect after partial flap closure are undesirable. However larger lesions located on the face (especially around the eye), which can't be totally covered by expanded flaps may be grafted in addition to flap closure. Bilobed flaps can also be used to cover defects following excision of the lesion but it is not always possible to prevent distortion of facial structures and facial contour. We preferred expanded bilobed flap for reconstruction of defects resulting from excision of congenital melanocytic nevi located on the face as the lesions were located in facial places like just lateral to lateral canthus in order to prevent possible distortion of facial structure and contour of the face that would have resulted if expanded skin had been used in the form of a single flap. We also preferred bilobed flaps over tissue expansion was limited due to complications such as expander exposure or when the clo-

sure of the defect created by lesion excision required a larger expanded flap than previously estimated. Thus use of bilobed flap after tissue expansion instead of using a single flap enables the surgeon to cover defects without causing any distortion of facial structures or contour asymmetry of the face. Use of bilobed flaps makes it unnecessary to operate the patient another time to complete the excision and obtain a better contour and finishes treatment in a single stage. However, use of bilobed flaps is associated with longer scars when compared with tissue expansion alone but cosmetic results are better than skin grafts due to better color and texture match and better contour (2,8). Repeated skin expansion or staged excision can also be used instead of expanded bilobed flaps (9). But this technique requires additional operations each requiring general anesthesia and cost in time and money is increased significantly. This technique is associated with shorter scars however skin quality of flaps prepared from expanded skin will decrease after repeated tissue expansion due to thinning of the skin limiting aesthetic outcome after surgical treatment. Moreover scars associated with the second flap of the bilobed flap technique can be hidden in postauricular or sideburn areas thus decreasing scar burden on the patient. If scar fading in time is not satisfactory then use of silicon sheets and minor scar revisions will make scar appearance better.

In conclusion, combination of the bilobed flap technique with tissue expansion is a useful alternative in the surgical treatment of congenital melanocytic nevi located on the face especially under certain circumstances (problems associated with previously placed tissue expanders) to obtain better contour and to complete reconstruction in one stage. Moreover scars associated with this technique fade in time as a result of scar maturation process and scars of the second flaps can be hidden in side burn or postauricular areas.

### REFERENCES

1. Bauer BS, Vicari FA. An approach to excision of congenital giant pigmented nevi in infancy and early childhood. *Plast Reconstr Surg* 1988; 82:1012.
2. Clark DH, Bennet JE. Excision of giant nevi in children - how should the wound be closed? *Ann Plast Surg* 1985; 15:443.

3. Kruk-Jeromin J, Lewandowics E, Rykala J. Surgical treatment of pigmented melanocytic nevi upon their size and location. *Acta Chir Plast* 1999; 41:20.
4. Maclennan SE, Corcoran JF, Neale HW . Tissue expansion in head and neck burn reconstruction. *Clin Plast Surg* 2000;27:121.
5. Maves MD, Lusk RP. Tissue expansion in the treatment of giant congenital melanocytic nevi. *Arch Otolaringol Head Neck Surg* 1987;113:987.
6. Orlow SJ. Congenital melanocytic nevi. In: Aston SJ, Beasley RW, Thorne CHM, eds. *Grabb and Smith's Plastic Surgery*. 5th ed. Philadelphia-New York: Lippincott-Raven, 1997:129.
7. Padilla RS, McConnell TS, Gribble JT, Smoot C. Malignant melanoma arising in a giant congenital melanocytic nevus. *Cancer* 1988;62: 2589.
8. Place MJ, Herber SC, Hardesty RA . In: Aston SJ, Beasley RW, Thorne CHM, eds. *Grabb and Smith's Plastic Surgery*. 5th ed. Philadelphia-New York: Lippincott-Raven, 1997: 22-3.
9. Vergnes P, Taieb A, Maleville J, Larregue M, Bondonny JM. Repeated skin expansion for excision of congenital giant nevi in infancy and childhood. *Plast Reconst Surg* 1993;91:450.
10. Wiltz H, Kollmer WL, Rauscher GE, Sharma PK, Cohen PJ, Schwartz RA. Excision of a the large congenital melanocytic nevus facilitated by the use of the tissue expander. *J Surg Oncol* 1988; 38:104.
11. Zielinski A, Pruscynski M. Giant congenital nevus as a basis for the development of malign melanoma. *Acta Chir Plast* 1985; 27:98.