

# Uterus-Like Ovarian Mass with Elevated Serum Levels of CA 19-9 and CA 125: A Case Report and Review of the Literature

## Artmış Serum CA 19-9 ve CA 125 Düzeylerinin Eşlik Ettiği Uterus-Benzeri Ovaryan Kitle: Bir Olgu Sunumu ve Literatürün Gözden Geçirilmesi

Canan KELTEN, MD,<sup>a</sup>  
Nagihan YALÇIN, MD,<sup>a</sup>  
Şermin ÇOBAN, MD,<sup>a</sup>  
Erkan ALATAŞ, MD,<sup>b</sup>  
Metin AKBULUT, MD<sup>a</sup>

Departments of  
<sup>a</sup>Pathology  
<sup>b</sup>Obstetrics and Gynecology,  
Pamukkale University  
Faculty of Medicine, Denizli

Geliş Tarihi/Received: 10.10.2008  
Kabul Tarihi/Accepted: 16.03.2009

*This case report was presented as a poster at 18<sup>th</sup> National Pathology Congress (25-29 October, 2008, Antalya, TURKEY).*

Yazışma Adresi/Correspondence:  
Canan KELTEN, MD  
Pamukkale University  
School of Medicine,  
Department of Pathology, Denizli,  
TÜRKİYE/TURKEY  
ckelten@pamukkale.edu.tr

**ABSTRACT** Uterus-like ovarian mass is a rare benign entity with controversial etiopathogenesis. A 37-year-old woman, gravida 2, para 2, presented with the complaint of pain in right lower abdominal quadrant. Physical evaluation revealed tenderness in this area and the ultrasonographic examination showed a right adnexial mass. Biochemical blood tests showed minimal leucocytosis and elevated serum levels of both CA 19-9: 117.79 mIU/mL (N: 0-37) and CA 125: 41.4 u/mL (N: 0-35). To exclude a malignancy, the specimen was examined with frozen sections and was subsequently diagnosed as endometriosis. Therefore, the surgical procedure was limited to right salpingo-oophorectomy. The right ovary was 6 x 4 x 2.5 cm in size and the dissected surface of ovary resembled a miniature uterus. Histologic sections as well as immunohistochemistry (smooth muscle actin, caldesmon and CD10) were consistent with the endometrial mucosal tissue that surrounded the bundles of smooth muscle.

**Key Words:** Endometriosis; CA 19-9 antigen; adenomyoma

**ÖZET** Uterus-benzeri ovaryan kitle etyopatogenezi tartışmalı, nadir görülen, benign bir lezyondur. 37 yaşında kadın hasta, gravida 2, para 2, sağ alt abdominal kadran ağrısı ile başvurdu. Fizik muayene ile hassasiyet gözlenen aynı bölgede, ultrason ile incelemede sağ adneksiye kitle saptandı. Biyokimyasal incelemelerde, minimal lökositozis yanısıra serum Ca19.9: 117.79 mIU/mL (N: 0-37) ve Ca 125: 41.4 u/mL (N: 0-35) değerleri yüksekliği izlendi. Malignite dışlanması için olgu frozen ile incelendi ve kitle endometriozis olarak değerlendirildi. Bunun üzerine cerrahi uygulama sağ salpingooforektomi ile sınırlandırıldı. Sağ over 6 x 4 x 2.5 cm boyutlarında olup kesi yüzü minyatür bir uterus görünümündeydi. Histolojik kesitleri yanısıra düz kas aktin, kaldesmon ve CD10'u içeren immünhistokimyasal incelemeleri, düz kas demetleri ile çevrelenmiş endometriyal mukoza ile uyumlu idi.

**Anahtar Kelimeler:** Endometriyozis; CA 19-9; adenomyoma

**Türkiye Klinikleri J Med Sci 2010;30(5):1732-6**

Uterus-like ovarian mass (UOM) was first described by Cozzutto in 1981.<sup>1</sup> 'Endomyometrioma', 'adenomyoma' and 'tumor of mullerian type' are representative of some of the terms, reported for UOM since 1981. This lesion shows a central cavity lined by endometrial mucosa surrounded by thick muscle wall. To our knowledge, 11 cases of UOM, aged 11-54 years old, were reported.<sup>1-7</sup> It was documented that five out of 11 cases were followed because of infertility, three had renal anomalies, two had breast cancers and three had elevated serum CA 125 levels (Table 1). UOM was also found in some other locations such as cervix uteri, broad

**TABLE 1:** Clinicopathologic features in patients with uterus-like ovarian masses.

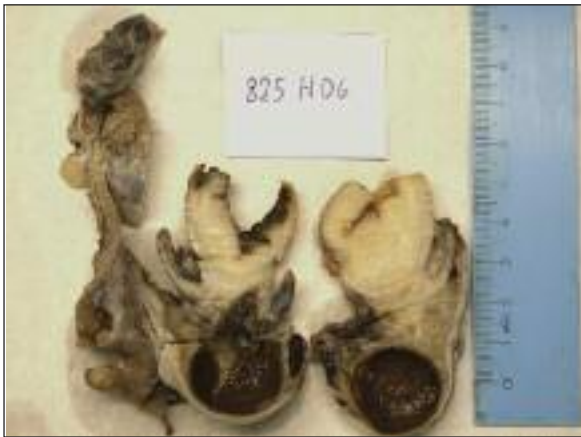Case	Year, Author	Age	Urogenital System Anomaly	Breast Cancer	CA 125	Other
1	1981, Cozutto C	32	Unilateral renal agenesis	-	-	-
2	1985, Peublitz-Peredo et al.	18	Double excretory system, double ureter, bifid pelvis	-	-	-
3	1991, Rahilly et al.	38	-	-	-	Endometrioid cancer in both ovary and endometrium
4	1994, Noel et al.	49	-	-	-	Cytogenetic anomaly (+), congenital anomaly (-)
5	1997, Mitra et al.	34	Not known	-	-	-
6	1998, Pai-Sanjay et al.	39	-	+	+	-
7	1998, Pai-Sanjay et al.	43	-	-	+	-
8	1998, Pai-Sanjay et al.	38	-	+	-	-
9	2005, Shutter	11	Resected right pelvic kidney	-	-	-
10	2007, Gurel et al.	54	-	-	-	Uterus unicornis
11	2007, Zannoni et al.	33	-	-	+	Histologic atypia
12	2008, Present	37	-	-	+	Elevated CA 19-9 and histologic atypia

ligament, peritoneum, pelvic lymph nodes, scrotum, small bowel, bladder and conus medullaris.<sup>8-11</sup> Two hypotheses have been proposed for the origin of UOM: 1- In the presence of endometriosis, through the metaplasia of endometrial stromal cells to the smooth muscle cells, 2- In the presence of the urogenital anomaly, the probability of being a part of congenital malformation.<sup>1-5,12,13</sup>

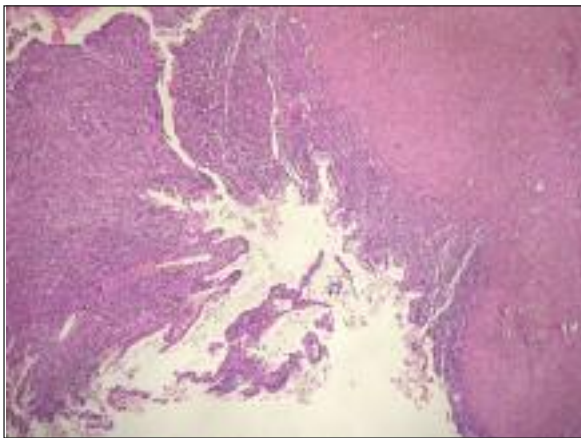
## CASE REPORT

A 37-year-old woman presented with abdominal pain. The patient had allergic asthma. Physical evaluation revealed tenderness in the right lower abdominal quadrant. The ultrasonographic examination showed a right adnexial mass (6 cm) and no other gynecologic or urinary abnormalities. On abdominal computed tomography (CT), liver, spleen, gallbladder and bilateral kidneys were normal in size and location. There were no suspicious lymphadenopathies in the abdomen or retroperitoneal area. During biochemical laboratory evaluation, minimal leucocytosis (12.1 K/uL), elevated serum CA 19-9: 117.79 mIU/mL (N: 0-37) and slightly elevated serum CA 125: 41.4 u/mL (N: 0-35) levels were detected. Blood count, TSH, f T3, f T4, CEA and AFP values were within the normal ranges. To exclude a malignancy, the specimen was examined with frozen sections and diagnosed as

endometriosis. Therefore, the surgical procedure was limited to right salpingo-oophorectomy. Intraoperatively, the right ovary was observed in Douglas sac adhered to the left ovary and rectal serosa. The uterus was of normal size and appearance. No foci suspicious for endometriosis were found in the pelvic or abdominal region or in another organ of genital tract. The right ovary was 6 x 4 x 2.5 cm in size and composed of two adherent nodules. One of the nodules resembled a miniature uterus since the cut section had a cavity with hemorrhagic appearance, which was surrounded with the bundles of smooth muscle (Figure 1). Microscopic evaluation revealed a cavity lined with columnar epithelium associated with endometrial stroma and surrounded by a thick muscular wall (Figure 2). Cells with atypia such as pleomorphic nuclei, hyperchromasia, nuclear vesiculation, prominent nucleolus and eosinophilic cytoplasm were observed in the wide areas of surface columnar epithelium (Figure 3). Hemosiderin-laden macrophages were present in endometrial stroma, which were surrounded by thick walls of smooth muscle bundles. From the block of this tissue, immunohistochemical stainings were applied for CD 10 (56C6 clone, 1:60 dilution, Neomarker Labvision), smooth muscle actin (1A4 clone, 1:100 dilution, Biogenex) and caldesmon (h-CD clone, 1/100 dilution, Biogenex)



**FIGURE 1:** Gross photo of the salpingo-oophorectomy: *right-top* is the uterus-like ovarian mass, containing a cavity surrounded with the thick wall of muscles and *right-bottom* is the ovarian stroma with a hemorrhagic cyst and follicular cysts.



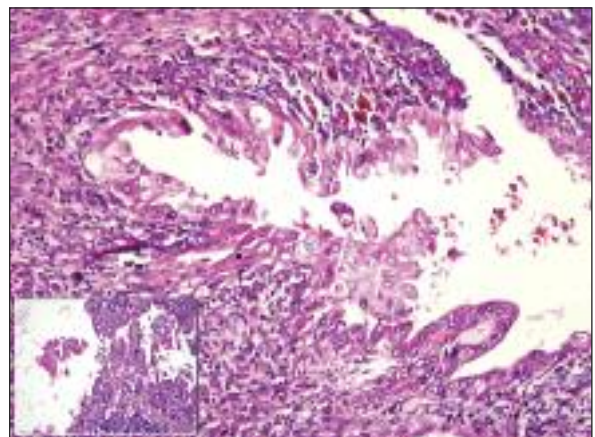
**FIGURE 2:** Thick myometrium-like smooth muscle component surrounds endometrial mucosa (H&E, original magnification x40).

with use of a standard labeled streptavidin biotin peroxidase method. Positive staining with CD10 (consistent with endometrial stroma), smooth muscle actin and caldesmon (consisting with smooth muscle tissue) confirmed the histological diagnosis. In one pole of this nodule, the bundles of smooth muscles were intermingling with the spindle cells of the ovarian stroma of the other nodule, composed of ovarian stroma with follicular cysts and hemorrhagic corpus luteum. No abnormality was found in the sections of right tubal tissues. The patient had been followed for two years due to infertility. Meanwhile, the only pregnancy achieved through in vitro fertilization was diagnosed as

'blighted ovum', thus finally curettage was applied to the patient. There has been no pregnancy since then.

## DISCUSSION

The etiopathogenesis of UOM is controversial. There are two main hypotheses. Cozzutto suggests that metaplasia of ovarian stroma in the background of endometriosis may explain the cause of the lesion.<sup>1</sup> This hypothesis has been supported by several other cases.<sup>3,4,13</sup> On electron microscopic evaluation, Cozzutto observed myofibroblasts as well as smooth muscle cells, and consequently, he suggested that myofibroblasts could be a transitional cell during the metaplastic changes. Supporting this view, Scully suggested that pressure of an expanding endometriotic cyst could trigger a metaplasia through smooth muscle cells in the cells surrounding the cyst.<sup>14</sup> He also indicated that smooth muscle fibers could be seen in some of other ovarian lesions such as leiomyoma, mucinous cystadenoma and ovarian stromal hyperplasia. In cases with absence of demonstrable endometrial mucosa due to bleeding or pressure, differentiation from ovarian stromal hyperplasia and leiomyoma should be considered. Although the period which triggers the metaplasia cannot be clearly determined, there is some evidence to support the role of ovarian hormones. Breast cancers were determined in two out



**FIGURE 3:** Endometrial columnar cells with atypia, (a) Stratification, tufting, pleomorphic nuclei, nuclear vesiculation, prominent nucleolus and eosinophilic cytoplasm were observed (H&E, original magnification x40), (b) inset shows similar atypia (H&E, original magnification x40).

of three cases reported by Pai et al.<sup>4</sup> Endometrioid carcinoma was identified in both ovary and uterus as well as endometriosis in the case of Rahilly et al.<sup>13</sup> Peterson et al. reported a case with precocious puberty and this points to the role of estrogen in formation of UOM.<sup>9</sup>

The other hypothesis proposed by Rosen is that this lesion may be a part of urogenital congenital malformation as a fusion defect of Mullerian duct or a real partial duplication of Mullerian system.<sup>12</sup> The detection of renal agenesis in the case of Cozzutto retrospectively and the presence of urinary anomaly in two other cases also support this hypothesis.<sup>2,5</sup> The hypothesis of metaplasia seems more likely in the cases without any uterus and/or renal congenital anomaly.<sup>3,4,13</sup>

It is known that the cases with endometriosis should be evaluated carefully by the pathologists in terms of the presence of cytologic atypia. Epithelial abnormalities (hyperplasia or atypia) have been considered as a step in the progression to malignancy.<sup>15,16</sup> Endometrioid carcinomas and clear cell carcinomas are the two most common tumors developed in ovarian endometriosis.<sup>15,16</sup> Rarely, various tumors in the background of ovarian endometriosis have been reported such as ovarian serous cystadenoma of low malignant potential, benign and malignant mucinous tumors, squamous cell carcinoma, granulosa cell tumor, endometrioid stromal sarcoma, malignant mesodermal mixed tumor and adenosarcoma.<sup>16,17</sup> Atypical cells display eosinophilic cytoplasm, large hyperchromatic or pale pleomorphic nuclei, increased nuclear to cytoplasmic ratio, cellular crowding, stratification or tufting. Zannoni et al. reported the first case of ovarian endomyometrioma with histologic atypia (hyperchromasia, pleomorphic nuclei, eosinophilic cytoplasm) and foci of mucinous metaplasia

on cavity lined by columnar epithelium.<sup>18</sup> In this study, authors have mentioned that the simultaneous presence of endometrial epithelium with histologic atypia and metaplasia supported the metaplastic theory of UOM. They have suggested the term 'endomyometrioma with atypias' for these cases. Similarly, our case showed epithelial tufting with pleomorphic nuclei, hyperchromasia, nuclear vesiculation, prominent nucleolus and eosinophilic cytoplasm.

High serum levels of both CA 19-9 and CA 125 have been reported in some benign lesions such as leiomyoma, endometriosis, teratoma of the fallopian tube and tuba-ovarian abscesses.<sup>19-22</sup> In endometriosis, serum level of CA 125 and CA 19-9 is expected to be no more than 100 IU/ml and 1000 IU/ml, respectively. However, very high serum levels of CA 125 and CA 19-9 (CA 125: 9537 IU/ml, CA 19-9: 15.653 IU/ml) was recorded in a patient with ruptured ovarian endometrioma.<sup>20</sup> The mechanisms that may elevate serum levels of CA 125 and CA 19-9 in endometriosis are not yet clearly understood; however, the diffusion of cyst fluid through the peritoneal surface into the circulation is considered in some cases.<sup>20</sup>

We believe that UOM was developed due to the metaplasia of ovarian endometrioma in our patient. First, no urogenital abnormalities were found on radiologic evaluations. Second, high serum levels of CA 19-9 and CA 125 were associated with the presence of ovarian endometriosis. Third, the presence of histologic atypia in columnar epithelium of endometrial mucosa supports the metaplastic theory.

### ***Acknowledgement***

*We would like to thank Hatice Altun for her assistance in editing English language.*

## REFERENCES

1. Cozzutto C. Uterus-like mass replacing ovary: report of a new entity. *Arch Pathol Lab Med* 1981;105(10):508-11.
2. Pueblitz-Peredo S, Luévano-Flores E, Rincón-Taracena R, Ochoa-Carrillo FJ. Uteruslike mass of the ovary: endometriosis or congenital malformation? A case with a discussion of histogenesis. *Arch Pathol Lab Med* 1985;109(4):361-4.
3. Noel JC, Hustin J, Simon P, Verhest A. Uterus-like mass of the ovary. *J Obstet Gynecol* 1994;14(33):209-11.
4. Pai SA, Desai SB, Borges AM. Uteruslike masses of the ovary associated with breast cancer and raised serum CA 125. *Am J Surg Pathol* 1998;22(3):333-7.
5. Shutter J. Uterus-like ovarian mass presenting near menarche. *Int J Gynecol Pathol* 2005;24(4):382-4.
6. Gurel D, Tuna B, Yorukoglu K. Uterus-like mass of the ovary. *Turkish J Pathol* 2007;23(2):103-6.
7. Mitra S, Nicol A, Scott Gl. Uterus-like mass of the ovary. *J Obstet Gynaecol* 1997;17(1):94-5.
8. Ahmed AA, Swan RW, Owen A, Kraus FT, Patrick F. Uterus-like mass arising in the broad ligament: a metaplasia or mullerian duct anomaly? *Int J Gynecol Pathol* 1997;16(3):279-81.
9. Peterson CJ, Strickler JG, Gonzalez R, Dehner LP. Uterus-like mass of the small intestine. Heterotopia or monodermal teratoma? *Am J Surg Pathol* 1990;14(4):390-4.
10. Fukunaga M. Uterus-like mass in the uterine cervix: superficial cervical endometriosis with florid smooth muscle metaplasia? *Virchows Arch* 2001;438(3):302-5.
11. Redman R, Wilkinson EJ, Massoll NA. Uterine-like mass with features of an extrauterine adenomyoma presenting 22 years after total abdominal hysterectomy-bilateral salpingo-oophorectomy: a case report and review of the literature. *Arch Pathol Lab Med* 2005;129(8):1041-3.
12. Rosai J. Uteruslike mass replacing ovary. *Arch Pathol Lab Med* 1982;106(7):364-5.
13. Rahilly MA, al-Nafussi A. Uterus-like mass of the ovary associated with endometrioid carcinoma. *Histopathology* 1991;18(6):549-51.
14. Scully RE. Smooth-muscle differentiation in genital tract disorders. *Arch Pathol Lab Med* 1981;105(10):505-7.
15. Busacca M, Vignali M. Ovarian endometriosis: from pathogenesis to surgical treatment. *Curr Opin Obstet Gynecol* 2003;15(4):321-6.
16. Clement PB. Diseases of the peritoneum. In: Kurman RJ ed. *Blaustein's Pathology of the Female Genital Tract*. 5<sup>th</sup> ed. New York: Springer-Verlag; 2002. p.729-89.
17. Elagoz S, Aker H, Egilmez R, Cetin A. [Histopathological diagnostic criteria of endometriosis and associated lesions: review of 63 cases]. *Turkiye Klinikleri J Gynecol Obst* 2000;10(4):253-9.
18. Zannoni GF, Vellone VG, Fadda G, Guerriero M, Carbone A. Ovarian endometrioma with atypias: description of a case. *Fertil Steril* 2007;88(5):1438.e15-7.
19. Tsao KC, Hong JH, Wu TL, Chang PY, Sun CF, Wu JT. Elevation of CA 19-9 and chromogranin A, in addition to CA 125, are detectable in benign tumors in leiomyomas and endometriosis. *J Clin Lab Anal* 2007;21(3):193-6.
20. Kurata H, Sasaki M, Kase H, Yamamoto Y, Aoki Y, Tanaka K. Elevated serum CA125 and CA19-9 due to the spontaneous rupture of ovarian endometrioma. *Eur J Obstet Gynecol Reprod Biol* 2002;105(1):75-6.
21. Ingeç M, Kadanali S, Erdogan F. Huge teratoma of the fallopian tube: a case report. *J Reprod Med* 2007;52(3):247-9.
22. Neunteufel W, Breitenacker G. Tissue expression of CA 125 in benign and malignant lesions of ovary and fallopian tube: a comparison with CA 19-9 and CEA. *Gynecol Oncol* 1989;32(3):297-302.